UC-NRLF
C 2 903 432

TYPICAL OPERATIONS IN SURGERY

DR. PH. BOCKENHEIMER

AND

DR. FRITZ FROHSE

Ex-libris
Charles Atwood
Kofoid
BMC

THE LIBRARY
OF
THE UNIVERSITY
OF CALIFORNIA

PRESENTED BY
PROF. CHARLES A. KOFOID AND
MRS. PRUDENCE W. KOFOID

Atlas of Typical Operations in Surgery

Atlas of Typical Operations in Surgery

BY

DR. PH. BOCKENHEIMER

AND

DR. FRITZ FROHSE

Sixty Illustrations from Water Colours by FRANZ FROHSE (Artist), Berlin

ADAPTED ENGLISH VERSION

BY

J. HOWELL EVANS, M.A., M.B.

M.Ch., Oxon., F.R.C.S., England

Demonstrator of Operative Surgery at St. George's Hospital, London

Late Senior Demonstrator of Human Anatomy at St. George's Hospital

Assistant Surgeon to the Cancer Hospital, London

Surgical Registrar Chelsea Hospital for Women, London

NEW YORK
REBMAN COMPANY
1123 BROADWAY

1906

LONDON
REBMAN LIMITED
129 SHAFTESBURY AVENUE

COPYRIGHT, 1906, BY
REBMAN COMPANY, NEW YORK

COPYRIGHT, 1906, BY
REBMAN LIMITED, LONDON
[ENTERED AT STATIONERS' HALL]

COPYRIGHT, 1905, OF THE GERMAN ORIGINAL TEXT, BY
REBMAN COMPANY, NEW YORK

COPYRIGHT IN GERMANY, 1905, OF THE
GERMAN ORIGINAL TEXT BY
GUSTAV FISCHER, JENA

[ALL RIGHTS RESERVED]

Printed in America

K-4R
E6-

PREFACE TO THE ENGLISH ADAPTATION

As the field of Operative Surgery is so wide, an Atlas comprehensive of every detail would become too voluminous, so that for the assistance of Students and Practitioners Drs. Bockenheimer and Frohse have chosen to describe lucidly and tersely one typical operation in each section considered. This "adapted version" presents to the English-speaking Members of the Medical Profession the work of these Eminent Surgeons.

The plan of their work is in no way altered.

By the aid of the Instrument Sheets and the beautiful Coloured Plates the reader is enabled to see at a glance the important steps, and at each step the important structures, which he encounters in the course of the operation.

By this means much energy will be economized to the Student in acquiring and to the Surgeon in reviving his knowledge.

J. HOWELL EVANS.

63 Grosvenor Street
LONDON, W.

N°8647

Regional Classification of the Operations Described

Figures refer to pages.

Operations on the Head.

Hemicraniotomy, 11—16.
Gasserian Ganglion, 243—250.
Tongue, Excision of the, 29—43.

Operations on the Neck.

Tracheotomy, High, 4—10.
Tracheotomy, Low, 53—70.
Larynx, Excision of, 53—70.
Oesophagotomy, 229—237.
Thyreoidectomy, 213—228.
Lingual Artery, Ligature of, 27—28.
Cellulitis of Neck, 125—128.

Operations on the Urogenital Tract.

Kidney, Excision of, 79—85.
Prostatectomy, 109—123.
Urethrotomy, External, 109—123.
Cystotomy, Suprapubic, 129—133.

Operations on the Thorax and Back.

Breast, Removal of the, 239—242.
Pericardiotomy, 177—180.
Pleurotomy, 71—74.
Rib, Resection of, 71—74.
Laparotomy, Transpleural, 105—107.
Laminectomy, 135—143.

Operations on the Abdomen.

Gastroenterostomy, Anterior, 155—166.
Gastroenterostomy, Posterior, 181—183.
Gastrostomy, 45—52.
Gallbladder, Operations on, 201—212.
Intestinal Resection, 167—176.
Implantation, Lateral, 185—188.
Appendicectomy, 93—103.
Colostomy, 145—149.
Enterostomy, 151—153.
Rectum, Operations on, 189—199.
Hernia, Operations for, 17—26, 87—92.

Operations on the Extremities.

Cellulitis of Hand, 75—77.
Hernia, Femoral, 87—92.

Contents

Plate	
I., II., III.	High Tracheotomy.
IV., V.	Hemicraniotomy.
VI., VII., VIII., IX., X.	BASSINI'S Operation for the Radical Cure of Inguinal Hernia.
XI.	Ligature of Lingual Artery.
XII., XIII., XIV., XV., XVI.	Excision of the Tongue—VON BERGMANN'S Method.
XVII., XVIII.	Gastrostomy.
XIX., XX., XXI., XXII., XXIII.	Excision of the Larynx.
XXIV.	Resection of Rib.
XXV.	Cellulitis of the Hand.
XXVI., XXVII.	Excision of Kidney.
XXVIII., XXIX.	Operation for Femoral Hernia.
XXX., XXXI., XXXII.	Appendicectomy.
XXXIII.	Transpleural Operation.
XXXIV., XXXV.	Urethrotomy. Prostatectomy.
XXXVI., XXXVII.	Cellulitis of the Neck.
XXXVIII.	Suprapubic Cystotomy.
XXXIX., XL.	Laminectomy.
XLI.	Colostomy.
XLII.	Enterostomy.
XLIII., XLIV., XLV.	Anterior Gastroenterostomy.
XLVI., XLVII.	Resection of Intestine.
XLVIII.	Pericardiotomy.
XLIX.	Posterior Gastroenterostomy.
L.	Lateral Implantation.
LI., LII.	Excision of Rectum.
LIII., LIV., LV.	Operations on the Biliary Passages.
LVI., LVII.	Thyreoidectomy.
LVIII.	Oesophagotomy.
LIX.	Removal of the Breast.
LX.	Operations on the Trigeminal Nerve and Gasserian Ganglion.

INSTRUMENTS OF USE IN OPERATIONS DESCRIBED



Langenbeck's Retractor. (3 sizes.)

Small Blunt Retractor.

Langenbeck's Retractor for hip joint resection.

Rehn's Skin Grafting Knife.



Lange's Retractor.

Hahn's Artery Forceps.

Minor Operating Finger Knife. Scalpel. Curved Sharp Bistoury.

Straight Scissors.



Pean's Haemostatic Forceps.

Curved Scissors.

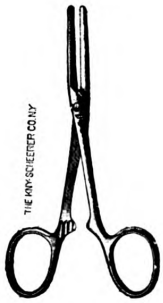

Pean's Haemostatic Forceps; long jaw.

Heavy Cartilage Knife.

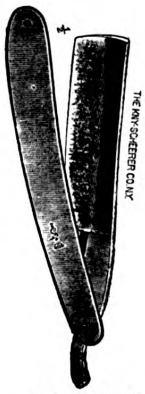

Skin Grafting Razor.

Small Double Prong Retractor.

Volkmann's 3 prong Retractor.

Probe with Myrtle leaf end.



Israel's Retractor.

Volkmann's 4 prong Retractor.

Bergmann's Blunt Retractor.

Director and Tongue Tie.

Langenbeck's Elevator.

Bergmann's Bone Chisels.

Schede's Bone Curettes.



Small Sharp Retractor.

Bruns' Bone Gouge.

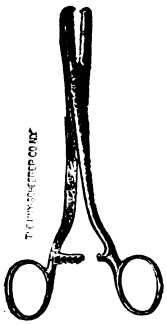

Bergmann's Haemostatic Forceps.



Polypus Dressing Forceps.

Liston's Bone Cutting Forceps.

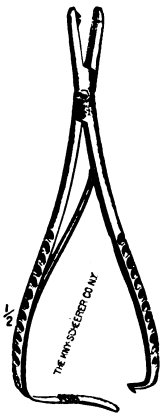

Green's Needle Holder.



Lead Bone Mallet.

Langenbeck's Stout Sharp Tenaculum.

Sayre's Double Ended Elevator.

Luer's Bone Rongeur

Plain Dressing Forceps; serrated tips.

Plain Dressing Forceps; mouse teeth ends.

Langenbeck's Raspatory.

Pean's Haemostatic Forceps; curved.

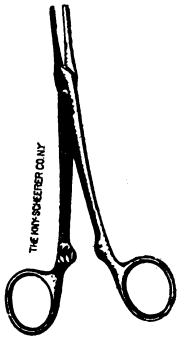

Kelly's Haemostatic Forceps.

Tracheotomy

INSTRUMENTS

Hupp's Trachea Retractor.

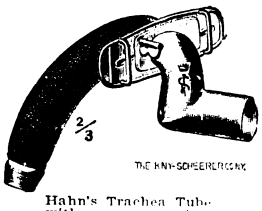

Hahn's Trachea Tube with sponge covering.

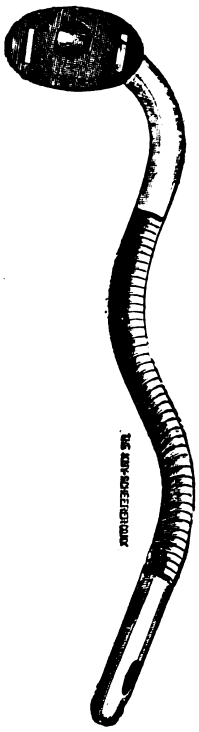

Koenig's Spiral Trachea Tube.

Trousseau's Trachea Tube.

Roser's Trachea Tube.

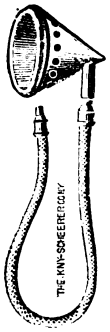

Chloroform Apparatus for Trachea Tubes.

Schimmelbusch's Trachea Tube.

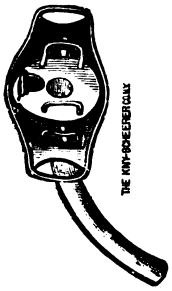

Lüer's Trachea Tube.

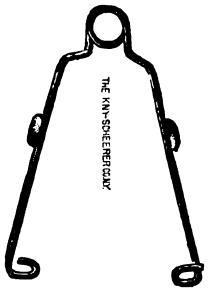

Bose's Wire Trachea Retractor.

Plate I.

Tracheotomy

Tracheotomy

STAGE I.

Position: A four-cornered cushion is placed under the Scapulæ of the patient; by this means the Head can be well retracted.

The lower border of the Cricoid Cartilage is the middle-point of an incision made exactly in the middle-line and commencing directly below the Notch of the Thyreoid Cartilage (*Incisura Thyreoidea.*) Beginners should make *long incisions.* The Skin and Superficial Fascia are divided by this incision. On the Fascia lie the Anterior Jugular Veins (also frequently the Transverse Branch of Communication between them). Between the two veins which are often of considerable size a *yellowish-white band* is seen. This band coincides accurately with the middle-line and separates the two Sternohyoid Muscles. The Fascia is divided on a grooved-director, along the yellowish-white line. The veins are ligatured.

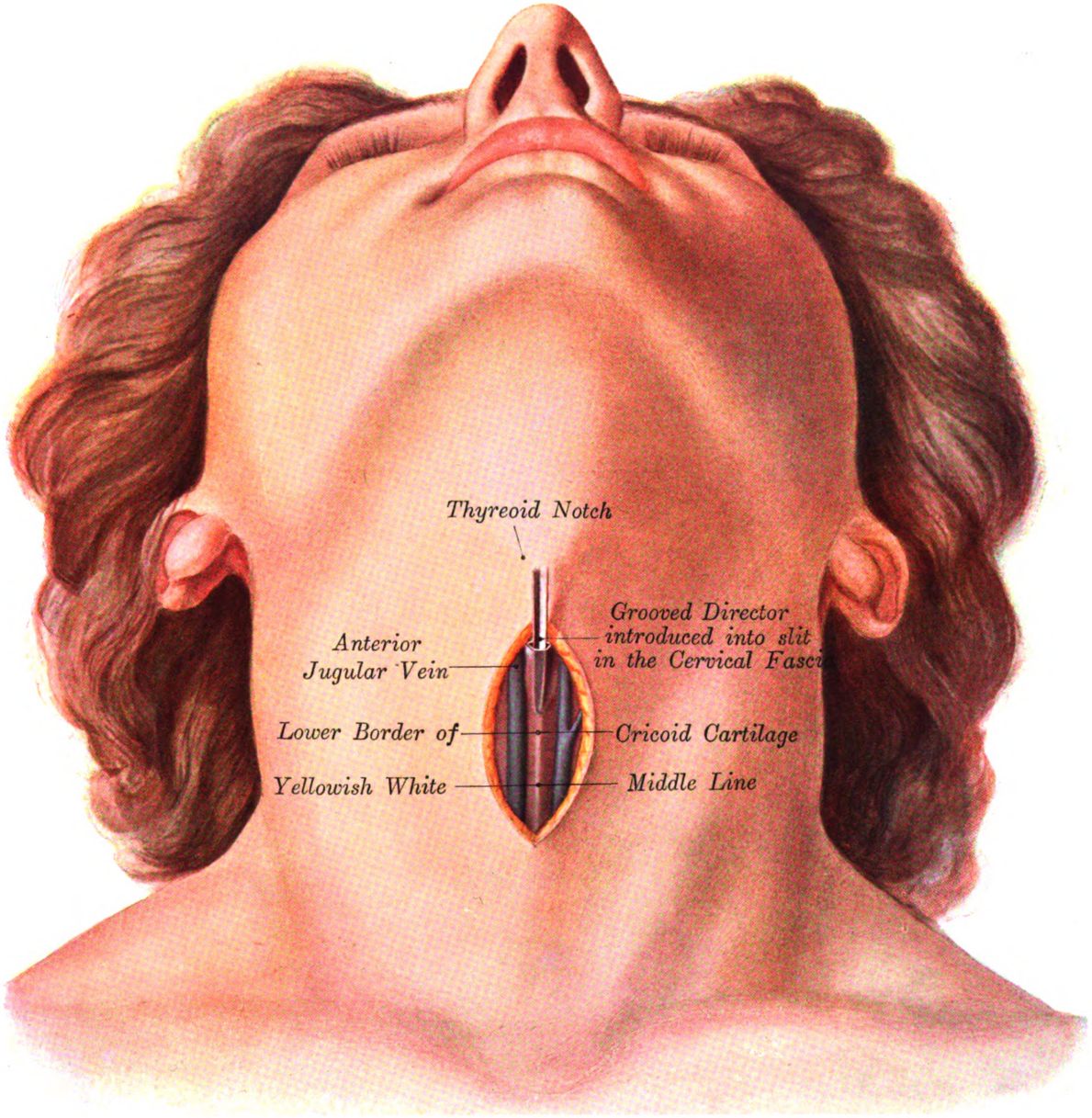

Tracheotomy (Stage I.).

Plate II.

Tracheotomy

Tracheotomy

STAGE 2.

Skin, Superficial Fascia, Sternohyoid Muscles are drawn aside so as to expose:—

1. The Cricoid Cartilage with the Crico-Thyreoid Muscles, above these the Central portion of the Crico-Thyreoid Membrane (*Ligamentum Conicum*).

2. The Isthmus of the Thyreoid Gland. At the lower border of the Cricoid Cartilage the deep layer of the Cervical Fascia which envelops the Larynx and Thyreoid Gland (*Fascia Laryngo-Thyreoidea*) is divided by a *transverse* incision. Through this slit a raspatory is passed between the Trachea and the posterior surface of the Thyreoid Gland.

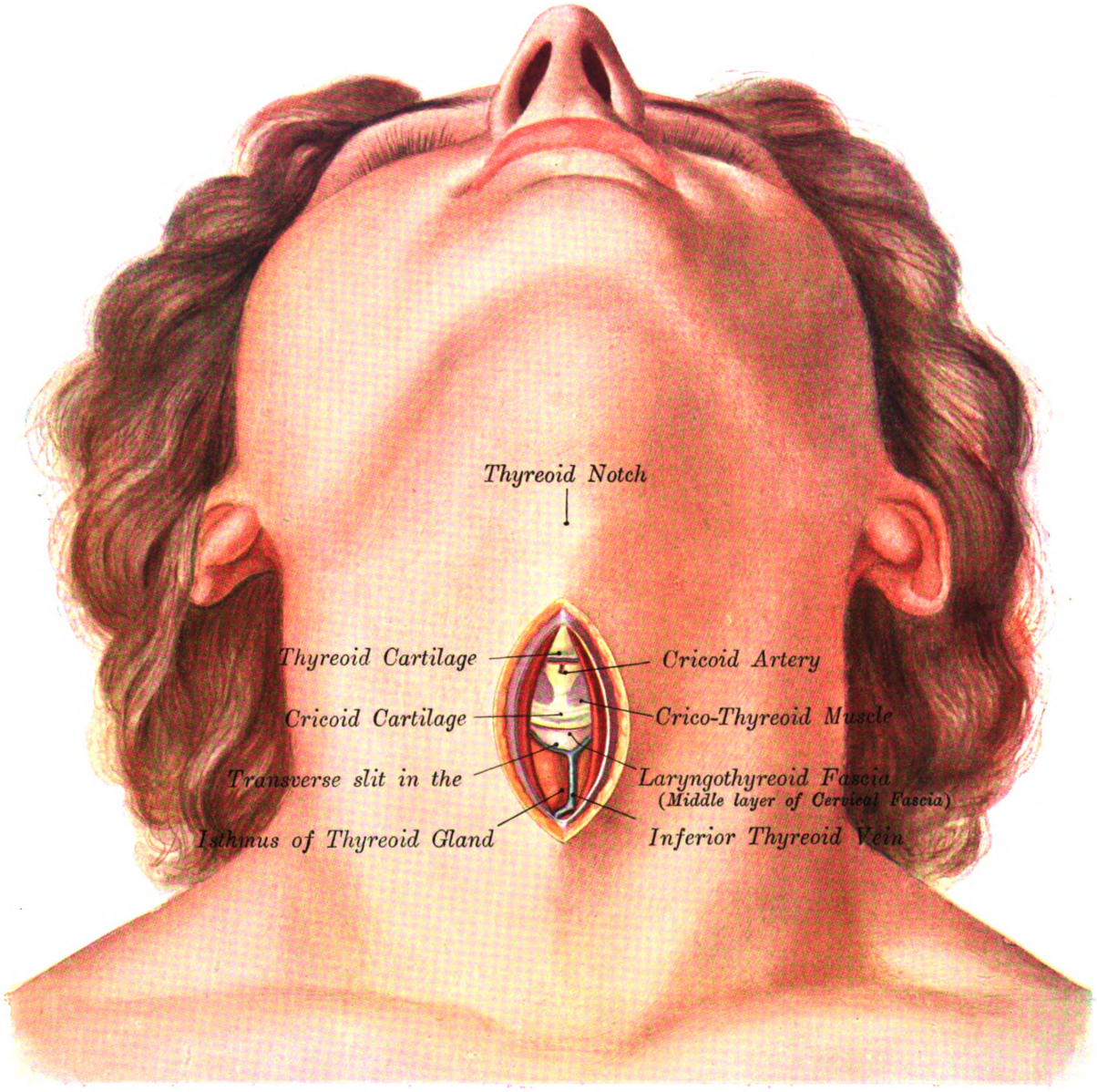

Tracheotomy (Stage II.).

Rebman Limited, London. *Rebman Company, New York.*

Plate III.

Tracheotomy

Tracheotomy

STAGE 3.

The Isthmus, thus detached, is drawn downwards, and the 3 upper rings of the Trachea are exposed to view. A sharp hook is inserted into the *lower* border of the Cricoid Cartilage and the upper rings of the trachea are pulled forwards to the *level* of the skin. When complete Hæmostasis has been procured, the Trachea is opened by means of a *longitudinal* incision which divides the first two or three rings. The edges of the Tracheal wound are held apart with retractors so as to allow of the introduction of a *double canula* which is then fixed by means of a band. (No bow or loop, but a double knot should be employed.) The skin wound may be partially united by sutures.

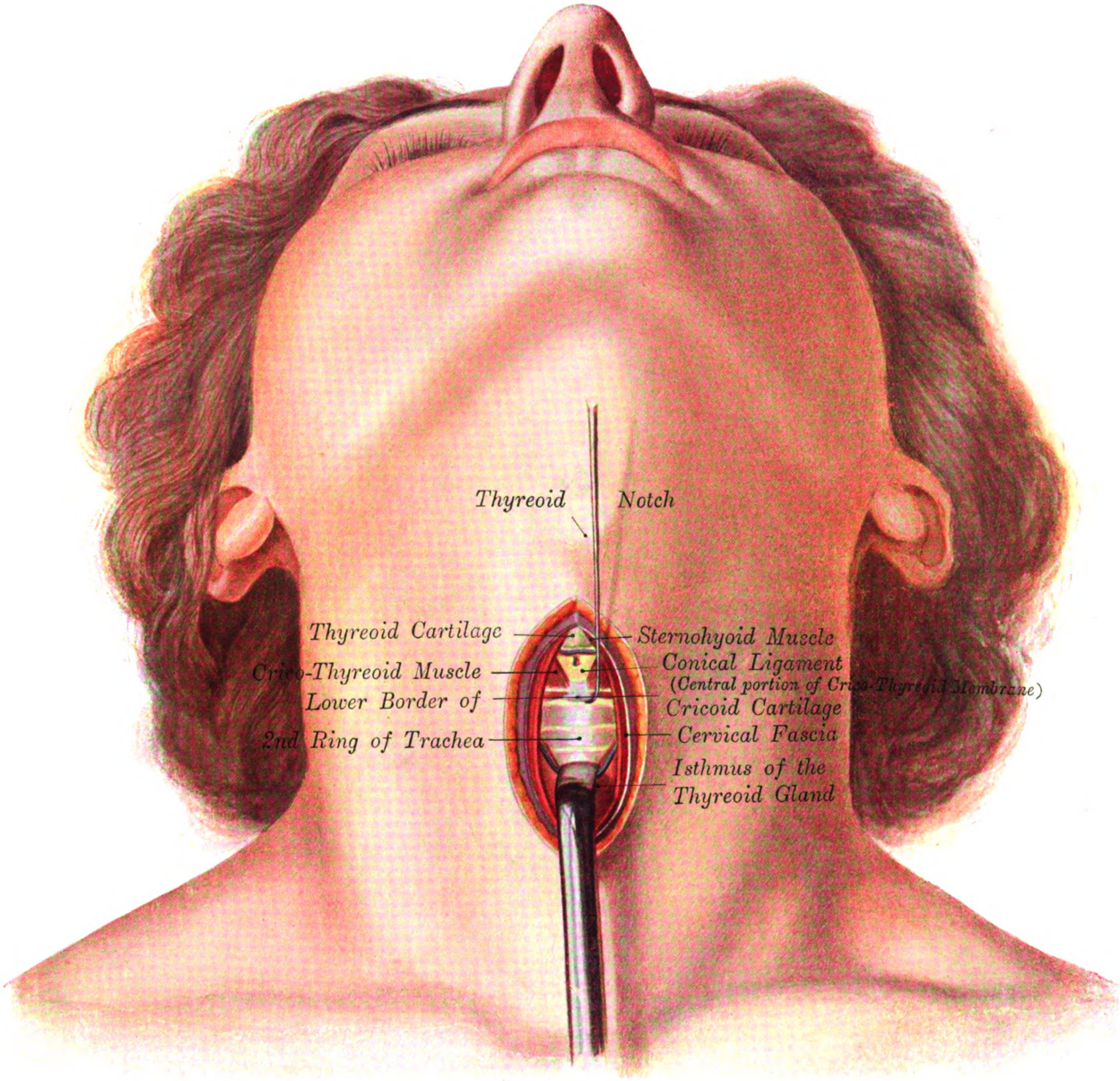

Tracheotomy (Stage III.).

Plate IV.

Hemicraniotomy

Plate IV.

Hemicraniotomy

INSTRUMENTS

Dahlgren's Cranial Rongeur.

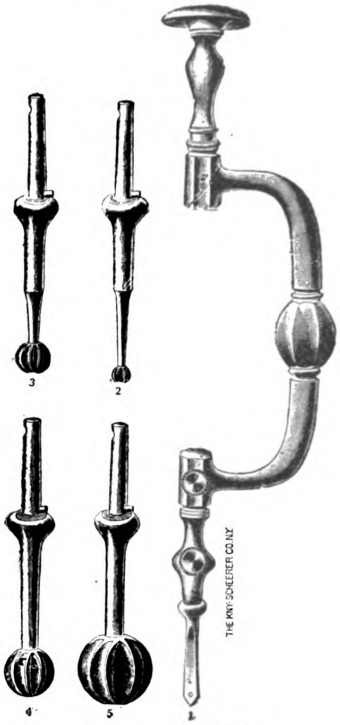

Doyen's Brace Trephine.

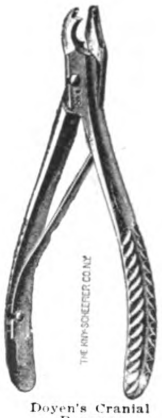

Doyen's Cranial Rongeur.

Doyen's Chisel for enlarging Cranial Section.

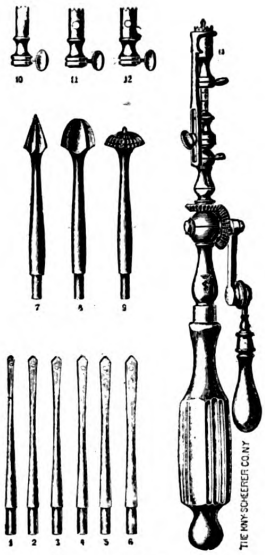

Collins' Bone Drill.

Sudeck's Trephining Set.

Doyen's Cranial Exsection Saw.

Hemicraniotomy

STAGE I.

Preparation: The patient's head is completely shaved: an elastic band or *Doyen's rubber bandage* is placed around the head in order to compress the vessels.

Position of Patient: While the skull is being chiselled open the *semi-prone* attitude is maintained, but when the *Dura Mater* has been opened the patient is placed in a *sitting* position.

A 4-sided flap, consisting of skin, muscle and periosteum (*pericranium*), is made so that its narrow base lies just above the Ear. The numerous vessels which bleed freely are ligatured. The periosteum is separated along the line of incision by a *raspatory,* the strip of periosteum separated being about 5 *mm.* (1/5 *inch*) broad. Similarly the soft parts must only be removed to a corresponding extent from the bone.

Four (if necessary a greater number) holes are made by means of *Doyen's drill;* by this means the thickness of the skull can be ascertained without any injury to the *Dura Mater.* By means of a circular saw the skull is divided from hole to hole whereas the Internal Table is kept, as far as possible, intact. The latter is now divided by means of a *guarded chisel,* which is held obliquely.

The flap, comprised of soft parts and bone in one thickness, is raised by means of two elevators. In the course of this manipulation the Temporal Bone at the base of the flap, which has hitherto remained undivided, snaps, and the *Dura Mater, Middle Meningeal Artery* (main vessel and chief branches) and the *Spheno-Parietal Venous Sinus* are exposed.

The *Dura Mater* is closely inspected before it is opened and the consistency of the underlying brain-tissue ascertained, because in this way a *tumour* can oftentimes be localized.

If necessary, and especially in the case of a tumour of the Frontal, Temporal or Occipital Lobes, the skull must be further opened up, in accordance with the seat of the tumour, by nipping off as much bone as is required with the aid of Bone-Forceps.

The *Dura Mater* is opened by a *crucial* incision and reunited later by sutures; if necessary the Trunk of the Middle Meningeal Artery is ligatured.

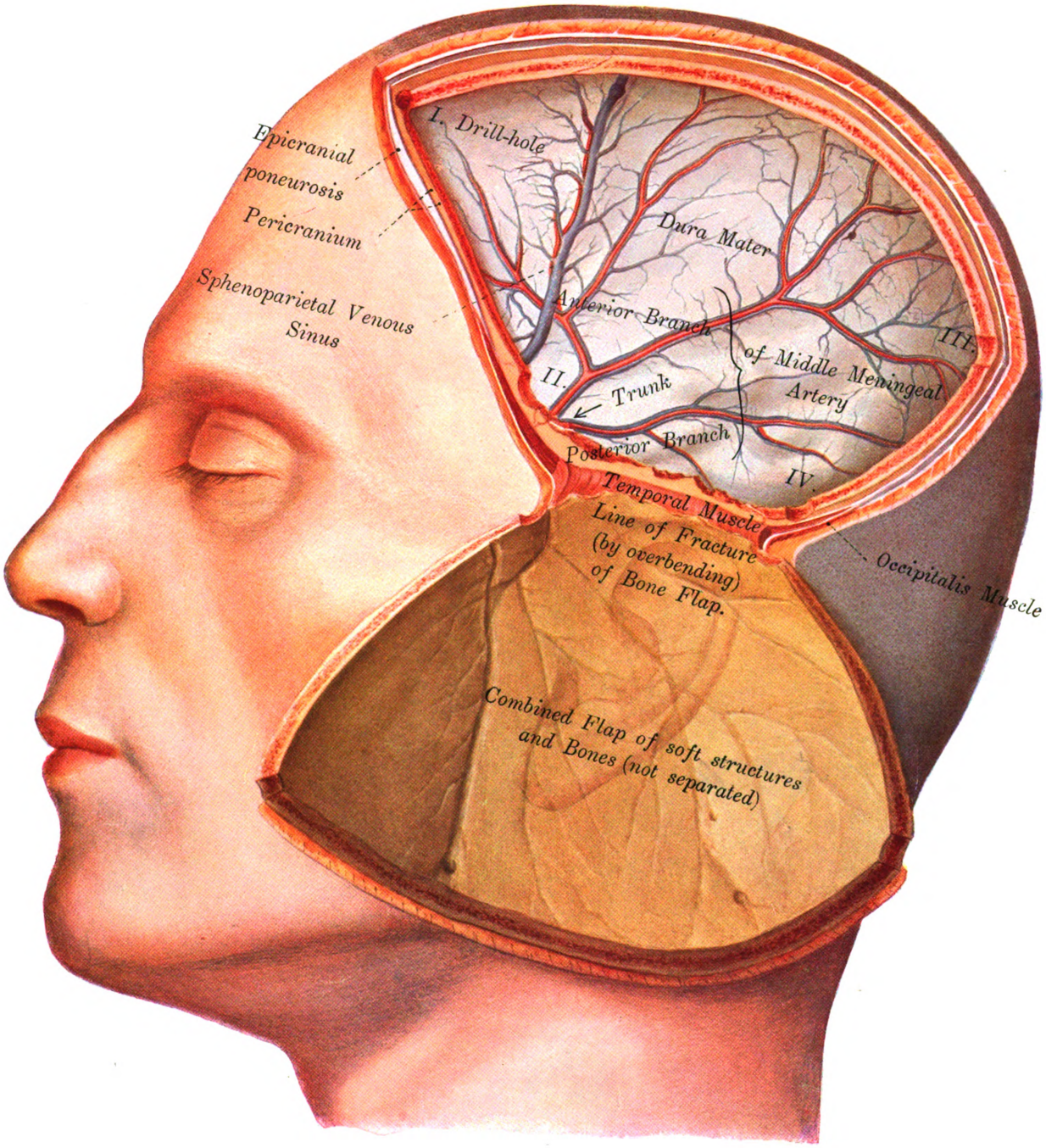

Hemicraniotomy (Stage I.).

Plate V.

Hemicraniotomy

Hemicraniotomy

STAGE 2.

This plate illustrates the left hemisphere extensively exposed with the various *centres* adapted from v. Bardeleben, Haeckel and Frohse (Atlas of Topographical Anatomy, Rebman Limited, London, and Rebman Company, New York, 1905. Translation by J. Howell Evans) with modifications after Horsley and Kocher.

The operation being completed, the *Dura Mater* is sutured with catgut, Iodoform gauze from the cavity of the wound is passed through a *slit* in the *Dura Mater* and drawn through one of the drill-holes. The Flap is returned to its original position, and the soft parts are reunited as accurately as possible.

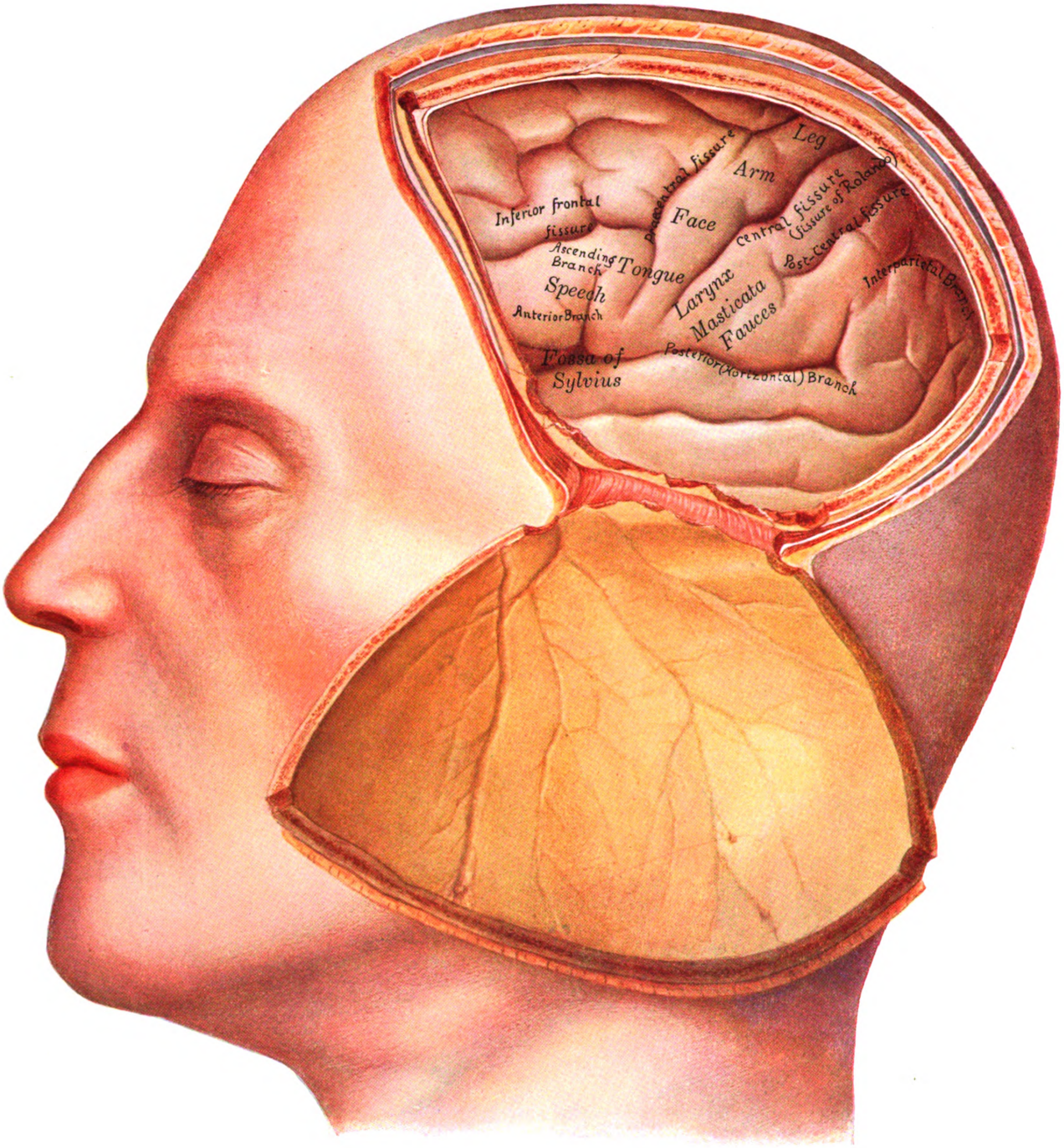

Hemicraniotomy (Stage II.).

Plate VI.

Herniotomy

Herniotomy

STAGE 1.

The incision through the soft parts is made in a line from the position of the Internal Abdominal Ring to the External Abdominal Ring and extended on to the Scrotum. When *large Herniæ* occur the incision should be carried to the lower part of the Scrotum. This extensive incision, in such cases, is practised in order to obtain a better view. The Scrotal Cavity is laid open.

When the subcutaneous fat has been cut through and all bleeding vessels ligatured, the Aponeurosis of the External Oblique Muscle is exposed with the Hernial Sac, over which the fibres of the Cremaster Muscle and the Pampiniform Plexus of veins are spread.

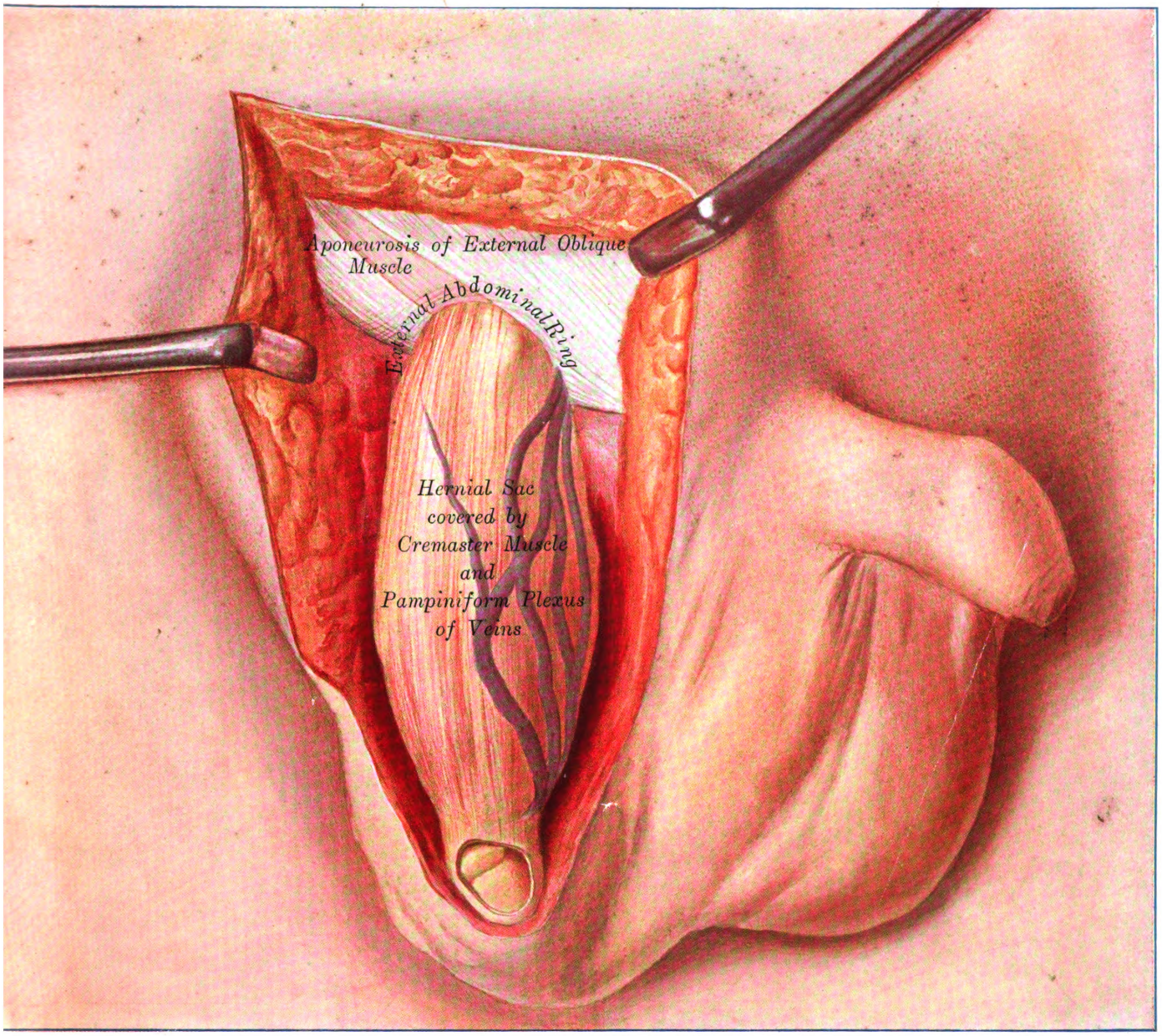

Herniotomy (Stage I.).

Plate VII.

Herniotomy

Herniotomy

STAGE 2.

The Hernial Sac (*Peritoneum*) is isolated from its coverings, viz. from the Testis, from the Vas Deferens, and the other constituents of the Cord (Cremaster Muscle, Spermatic Vessels and Tunica Vaginalis). It is advisable to commence this separation at the External Abdominal Ring because the cord, at this point, is rounded and not flattened. In order to accurately define the topographical relations, the Aponeurosis of the External Oblique Muscle may be divided as far as the Internal Abdominal Ring, and the *neck* of the Hernial Sac be isolated completely on all sides.

In every case the Sac should be laid open. Any portion of *Omentum* which may be found in the Sac is ligatured with catgut sutures. Each catgut suture is, in turn, secured by a silk stitch, whereby any slipping of the suture is prevented. (V. Bergmann.)

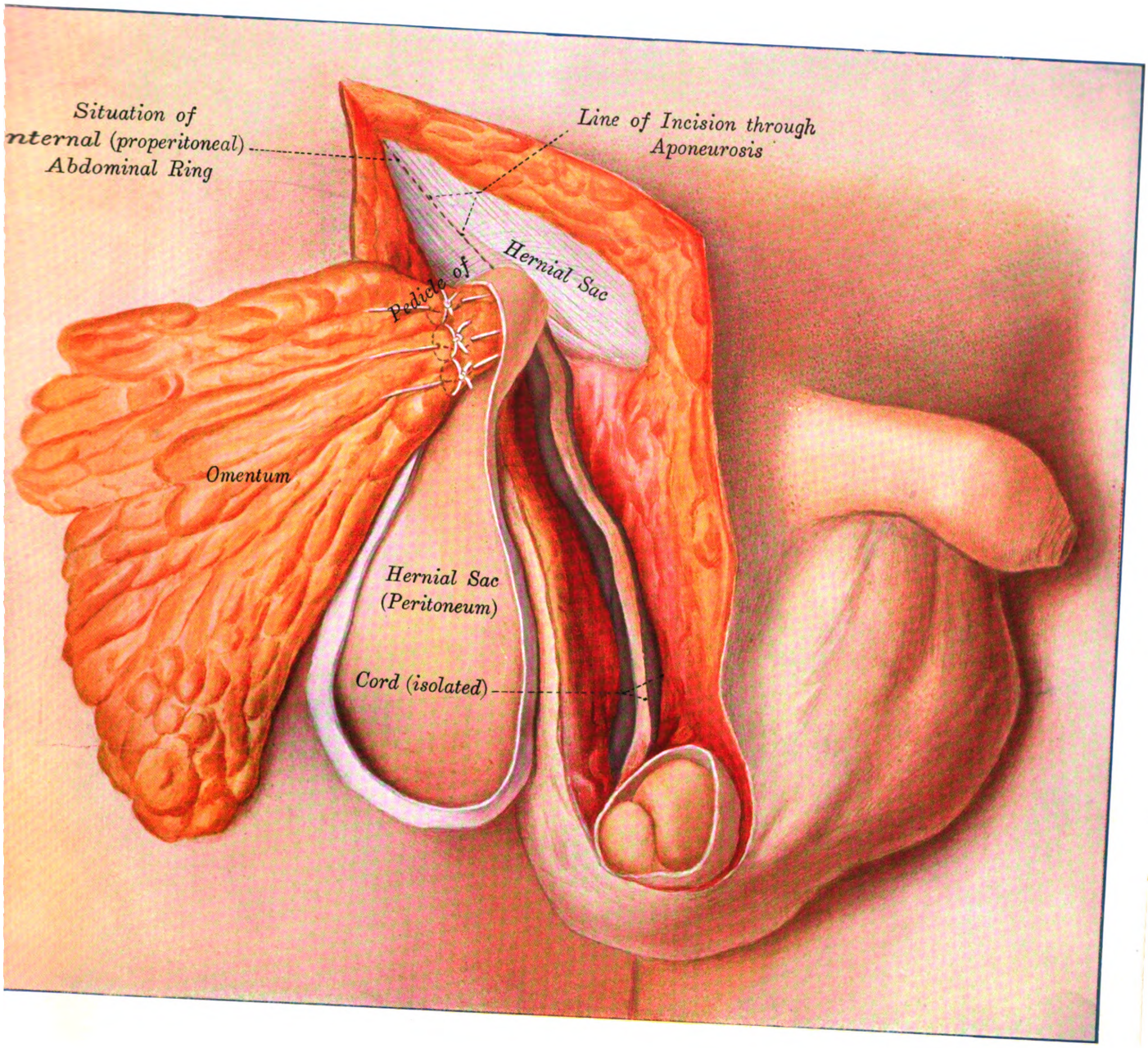

Herniotomy (Stage II.).

Rebman Limited, London.

Rebman Company, New York.

Plate VIII.

Herniotomy

Herniotomy

STAGE 3.

The ligatured *omental stump* is now returned into the abdominal cavity. The neck of the Hernial Sac (duly freed) is *twisted* and ligatured by transfixion at the level of the Internal Abdominal Ring, and the peripheral portion cut off.

The divided Aponeurosis of the External Oblique is drawn aside by means of forceps and the muscles which lie deep to this Aponeurosis (Internal Oblique and Transversalis) are held forward by a hook. The cord, which, at a previous stage, was carefully isolated is now drawn aside by a piece of gauze-ribbon.

The *Deep Epigastric Vessels* which run on the Fascia Transversalis and the Peritoneum, may easily be ligatured, if necessary, as they lie inferior to the Hernial Sac.

The technique of Intestinal Resection in cases where gangrenous intestine is contained within the sac, will be described later.

The *constriction* which is frequently found at the neck of the Hernial Sac, we always relieve by the *open method,* dividing, layer by layer, the constricting bands. We have entirely abandoned any division of the ring of constriction by means of Cooper's Herniotomy knife.

By this method all constrictions are more certainly divided and hæmorrhage from vessels, previously ligatured, is avoided.

In Herniæ of the small intestine, the Sac can be completely cut off by a circumferential ligature, but this is impossible when *Caecum, Ascending Colon, Descending Colon* or *Sigmoid Flexure* have been forced into the Hernial Sac.

In such cases the *posterior* and *lateral* wall of the protruding peritoneum connected with the large intestine is returned with the Viscus, whereas the *anterior* edge of the incised Hernial Sac is closed by sutures.

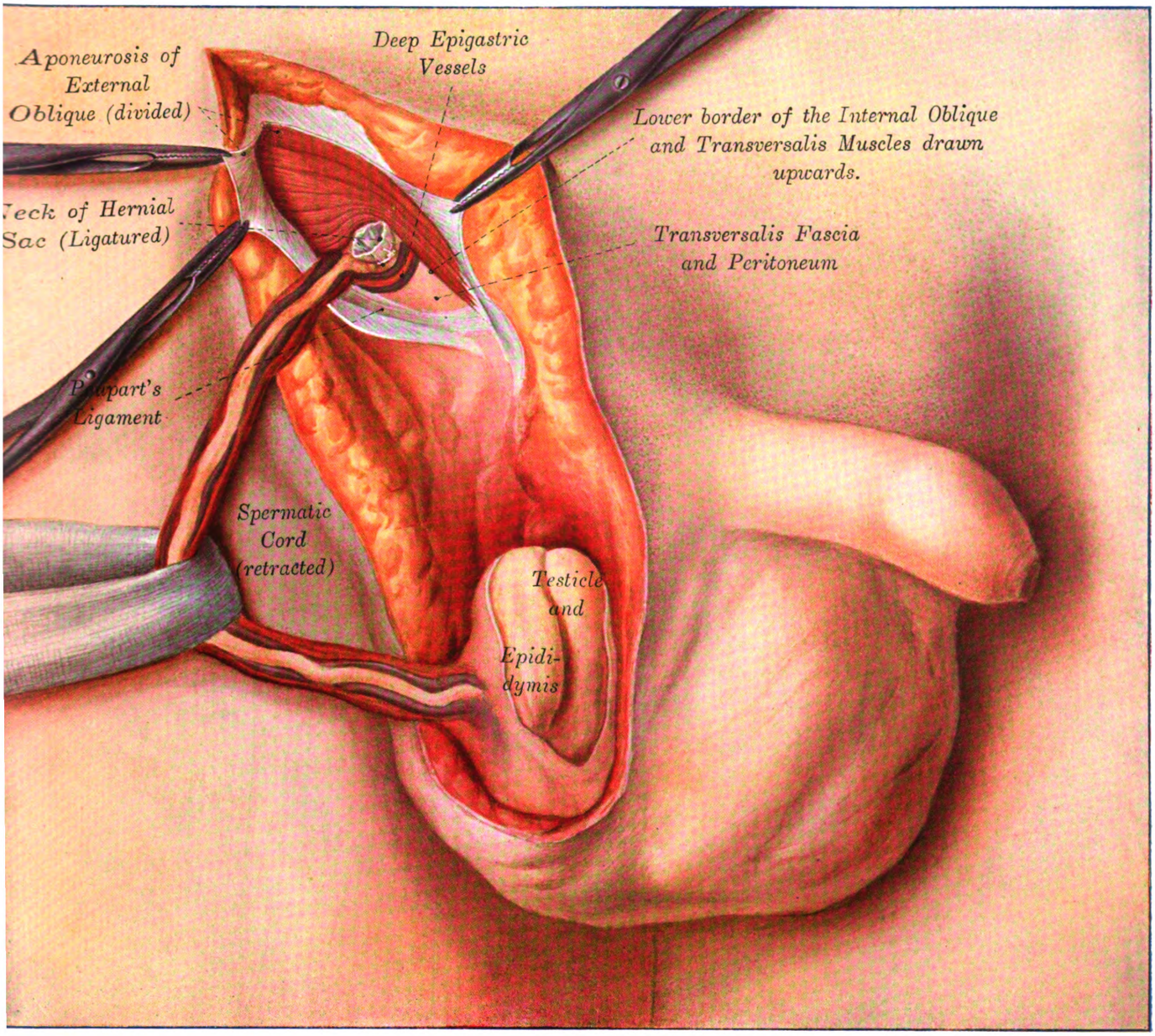

Herniotomy (Stage III.).

Plate IX.

Herniotomy

Herniotomy

STAGE 4.

The Vas Deferens and Spermatic Cord should now be pulled upwards to allow the Internal Oblique and the Transversalis Muscle—which is in deep relation to it—to be united with the deeper part of Poupart's Ligament by *silk* sutures.

The suture nearest the median line is passed through the substance of the Rectus Muscle and the *Periosteum* of the Pubic Bone. Three to five sutures are passed.

The suture at the Internal Abdominal Ring, that is, the one situated farthest out, must in no way compress the Spermatic Cord. In the inclusion of Poupart's Ligament within the suture, considerable care is necessary to avoid the Iliac vessels which form so close a posterior relation; furthermore it is important to take up the *deep part* of Poupart's Ligament *within* the suture, and not merely the divided Aponeurosis of the External Oblique as it merges into the ligament.

ROCKENHEIMER & FROHSE.

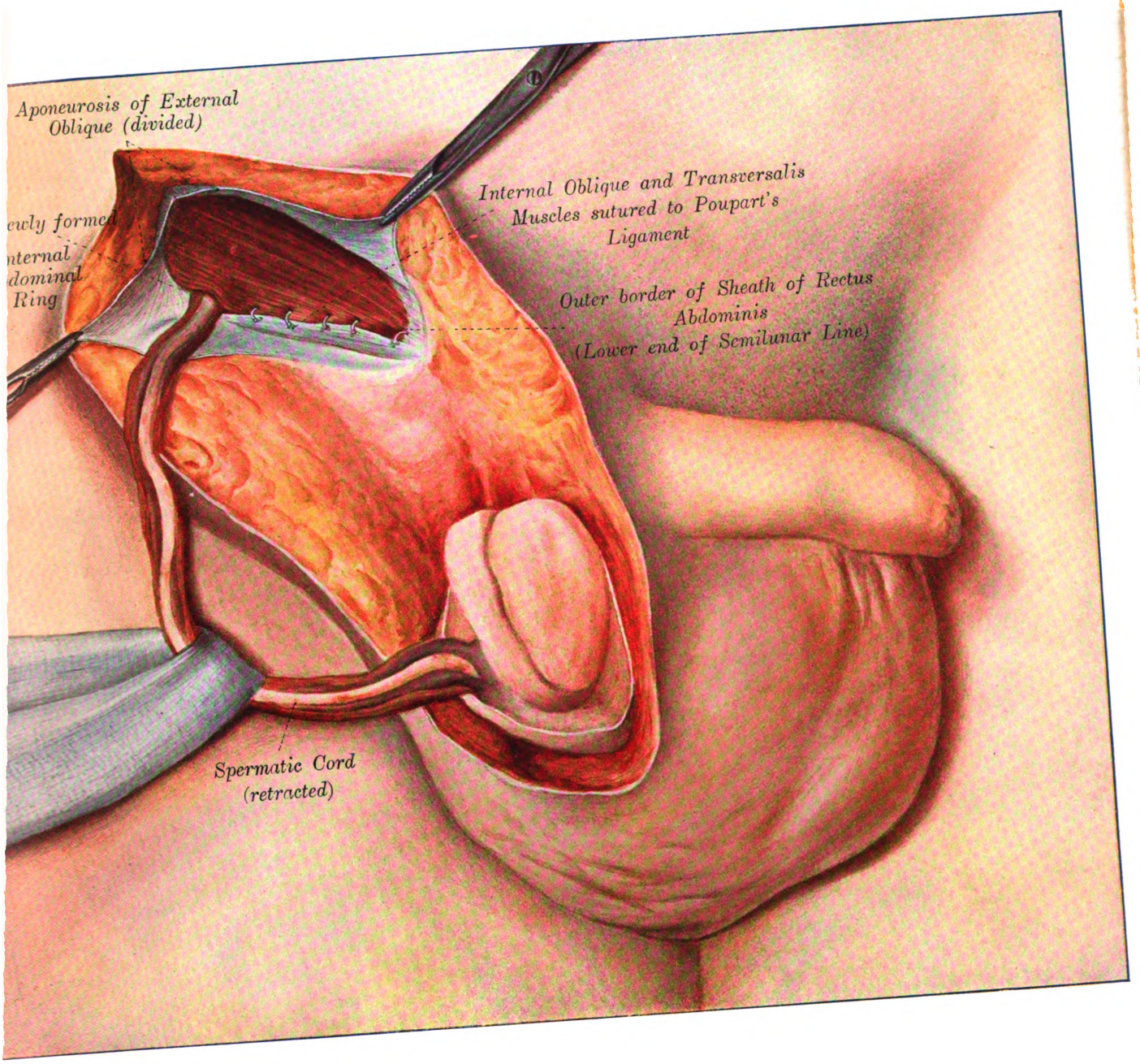

Herniotomy (Stage IV.).

Rebman Company, New York.

Rebman Limited, London.

Plate X.

Herniotomy

Herniotomy

STAGE 5.

By the union of the Internal Oblique Muscle with Poupart's Ligament, a *new* posterior wall to the Inguinal Canal has been built up. It is upon this newly formed wall that the Spermatic Cord with the Vas Deferens is placed. Over these structures the edges of the External Oblique Muscle are brought together by means of catgut sutures; the testicle is now carefully replaced in the bottom of the Scrotum. The skin is sewn up.

By this operation the lowest point of the Abdominal cavity (as differentiated from the Pelvic Cavity), viz. the External Abdominal Ring which always has to bear the greater pressure, is strengthened to such a degree as to render the wearing of a truss *unnecessary*.

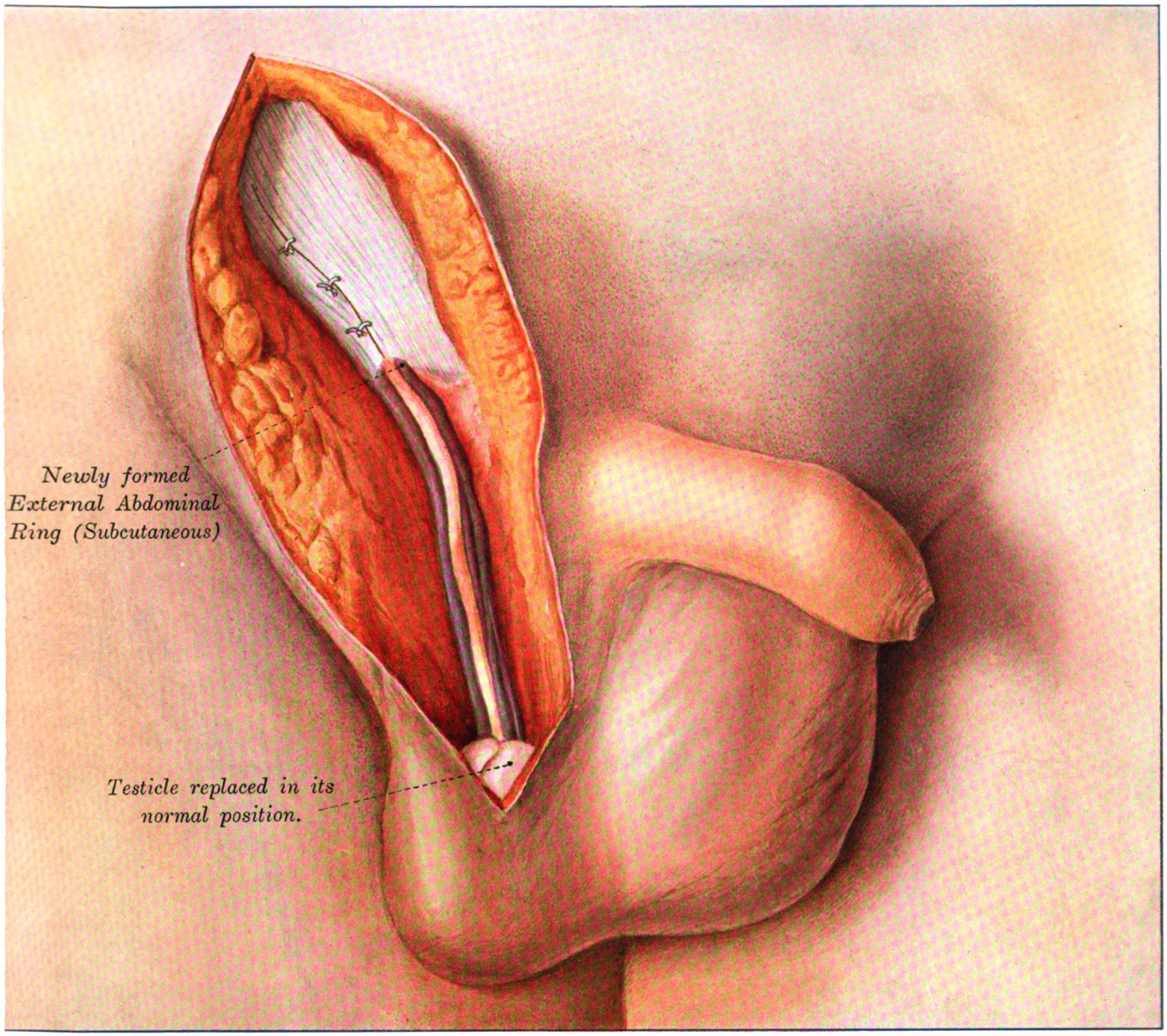

Herniotomy (Stage V.).

Rebman Limited, London. *Rebman Company, New York.*

Plate XI.

Ligature of the Lingual Artery

Ligature of the Lingual Artery

Position: The head is extended and turned towards the opposite (healthy) side.

Linear guide to the Vessel: From the middle of the Hyoid Bone to the Apex of the Greater Cornu.

Incision: The incision commenced at the Hyoid bone is extended half way along the linear guide.

The Platysma is divided. The Submaxillary Gland which is enclosed in a *fascial capsule* is drawn upwards after the division of the Anterior Fascial Lamella.

As we pass laterally from the inner edge of the wound, we find the following structures:

Muscles. Mylohyoid, Digastric (Anterior and Posterior Bellies), Stylohyoid.

At a deeper plane lying on the Hyoglossus Muscle the Lingual Vein and Hypoglossal Nerve.

In the |> space formed by the Mylohyoid Muscle, Digastric Muscle and the Hypoglossal Nerve, the Artery is found deeply placed, after separating with a *blunt* instrument the fibres of the Hyoglossus Muscle.

A double ligature is passed around the vessel by means of an Aneurism needle.

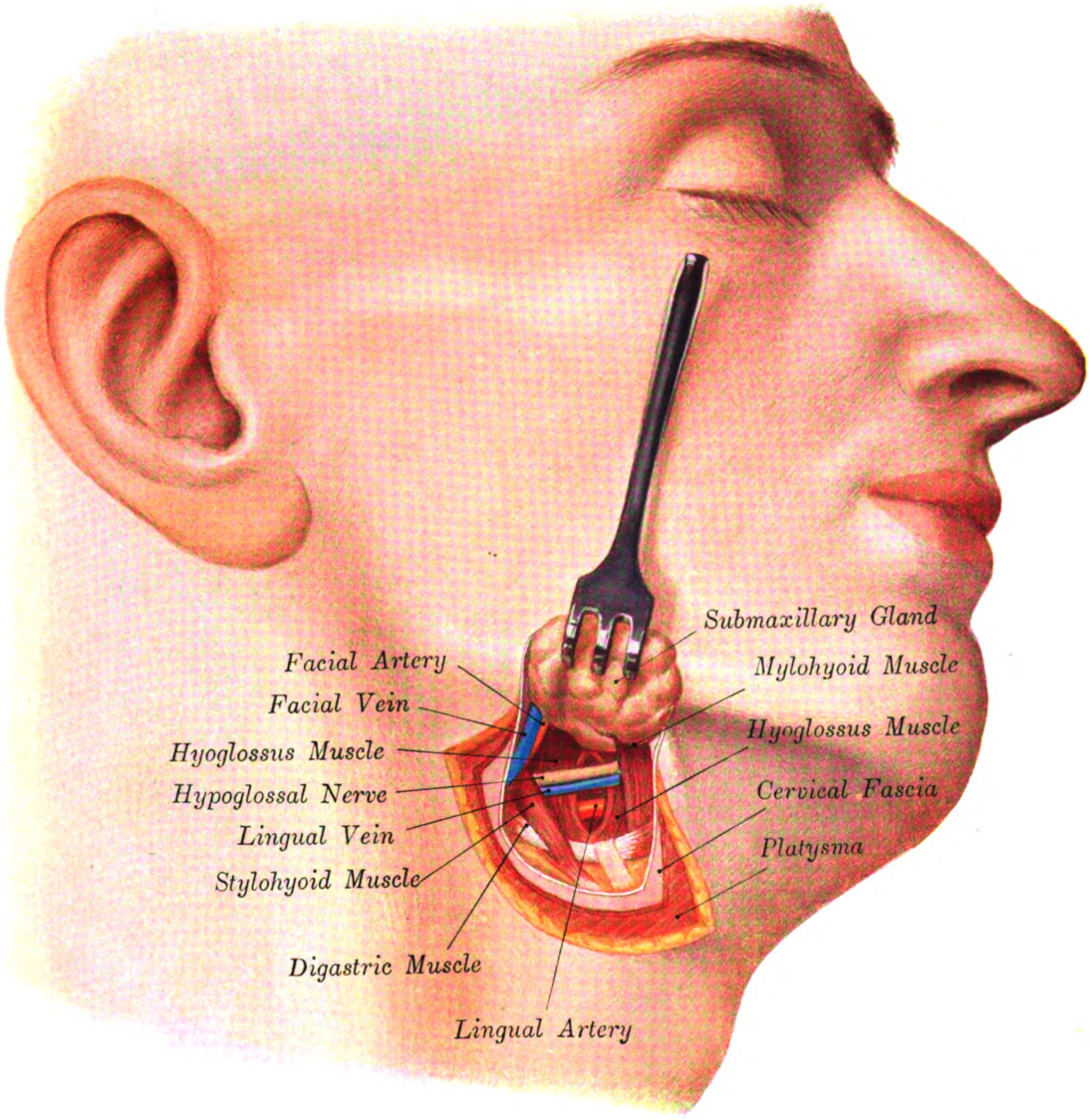

Ligature of the Lingual Artery.

Plate XII.

Excision of the Tongue

(after von Bergmann)

Excision of the Tongue

(after von Bergmann)

STAGE I.

An incision is made on the affected side, from the angle of the mouth to the Anterior border of the Masseter Muscle, being carried through the entire structures of the cheek; from this point the incision is prolonged downwards, so as to meet the inner border of the Sterno-Mastoid Muscle, at an acute angle just below the point of bifurcation of the Carotid Artery.

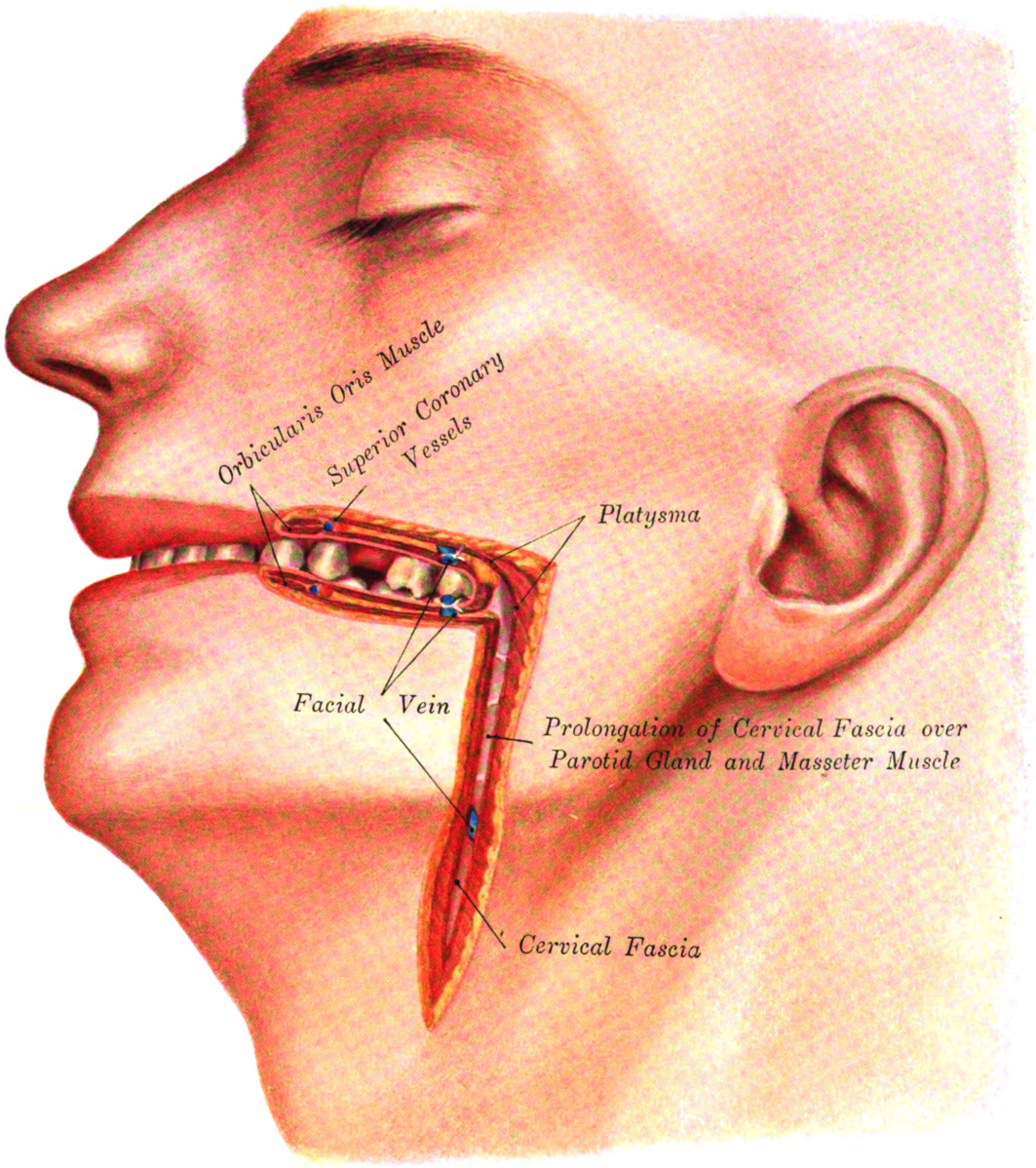

Excision of the Tongue (after von Bergmann) (Stage I.).

Plate XIII.

Excision of the Tongue

Plate XIII.

Excision of the Tongue.

INSTRUMENTS.

Langenbeck's Aneurism Needle.

Trendelenburg's Trachea Tube, with tampon.

Bockenheimer's Mouth Gag with electric illuminating lamp.

Spatula and Tongue Tie.

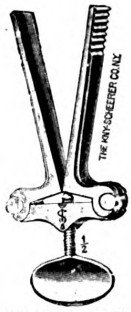

Heister's Mouth Gag.

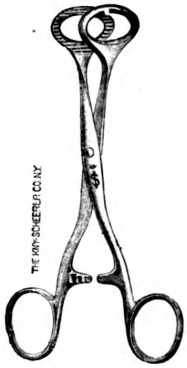

Collin's Tongue Forceps.

Wire Nippers.

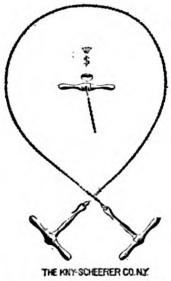

Gigli's Wire Saw, with handles.

Thomas' Wire Twister.



Ollier's Chain Saw Carrier.

Excision of the Tongue

STAGE 2.

In the 1st Stage we have seen how the whole cheek as far back as the Anterior border of the Masseter, is cut through, whereas the line of incision is made so as to avoid *Stenson's Duct* and those branches of the Facial Nerve which run downwards to the angle of the mouth.

The Coronary Vessels and the Facial Vein have already been ligatured.

In Stage 2 the incision directed obliquely downwards, is deepened by dividing the Platysma and the Parotideo-Masseteric Fascia at the Anterior Border of the Masseter as far down as the lower border of the Lower Jaw, thence downwards to the inferior angle of the wound.

Whereas the upper part of the incision may be carried boldly down on to the Periosteum of the Lower Jaw, below *the lower border of the lower jaw,* the incision must not yet be carried deeper than through the Platysma so as to avoid the Supramandibular Branch of the Facial Nerve (*Ramus Marginalis Mandibulae*) and the Facial Artery (External Maxillary Artery).

The Facial Vein, though previously tied, may need a second ligature in this situation.

The submaxillary gland situated between the two layers of Fascia is sought, the Anterior layer is divided along the lower border of the gland, which being now well isolated, is freely excised after ligature of *Wharton's Duct.* (This detail is carried out because lymphatic glands of cancerous infection are frequently found in its substance).

Occasionally the Facial Artery in its tortuous course amid the gland and the Ramus Marginalis of the Facial Nerve, may be left uninjured, provided the operation be carefully carried out.

When the Submaxillary Salivary Gland has been enucleated, very many small lymphatic glands are found. *These must be removed.*

Similarly lymphatic glands situated in the region of the chin, and the invariably infected glands which lie along the mesial border of the Sternomastoid Muscle, must be removed.

The Cervical Lymphatic Glands near the bifurcation of the Carotid Artery as well as those which lie in close relation with the lower extremity of the Parotid Gland and extend into the Retro-Maxillary Fossa, frequently become infected at an early date.

The *Lingual Artery* is now ligatured, as indicated in Plate XI. Thus any serious hæmorrhage during the removal of tumours of the Tongue is obviated.

The Mylohyoid and Hyoglossus Muscles, the Hypoglossal Nerve and Lingual Vein serve as our important guides in this procedure.

Easy access to the Tongue can be obtained from *below* if, after separation of the Mylohyoid Muscle from the Mylohyoid Ridge which can be felt along the inner surface of the lower jaw, the mucous membrane of the *floor* of the mouth *be divided.*

According to our method the posterior part only of the Mylohyoid Muscle need be divided so as to allow a section of the lower jaw to be made.

In those *rare cases* in which the Carcinoma occupies the *tip* of the Tongue and the Glands are infected on both sides, *bilateral* division of the Cheek (Plate XII) *without* section of the lower jaw is sufficient.

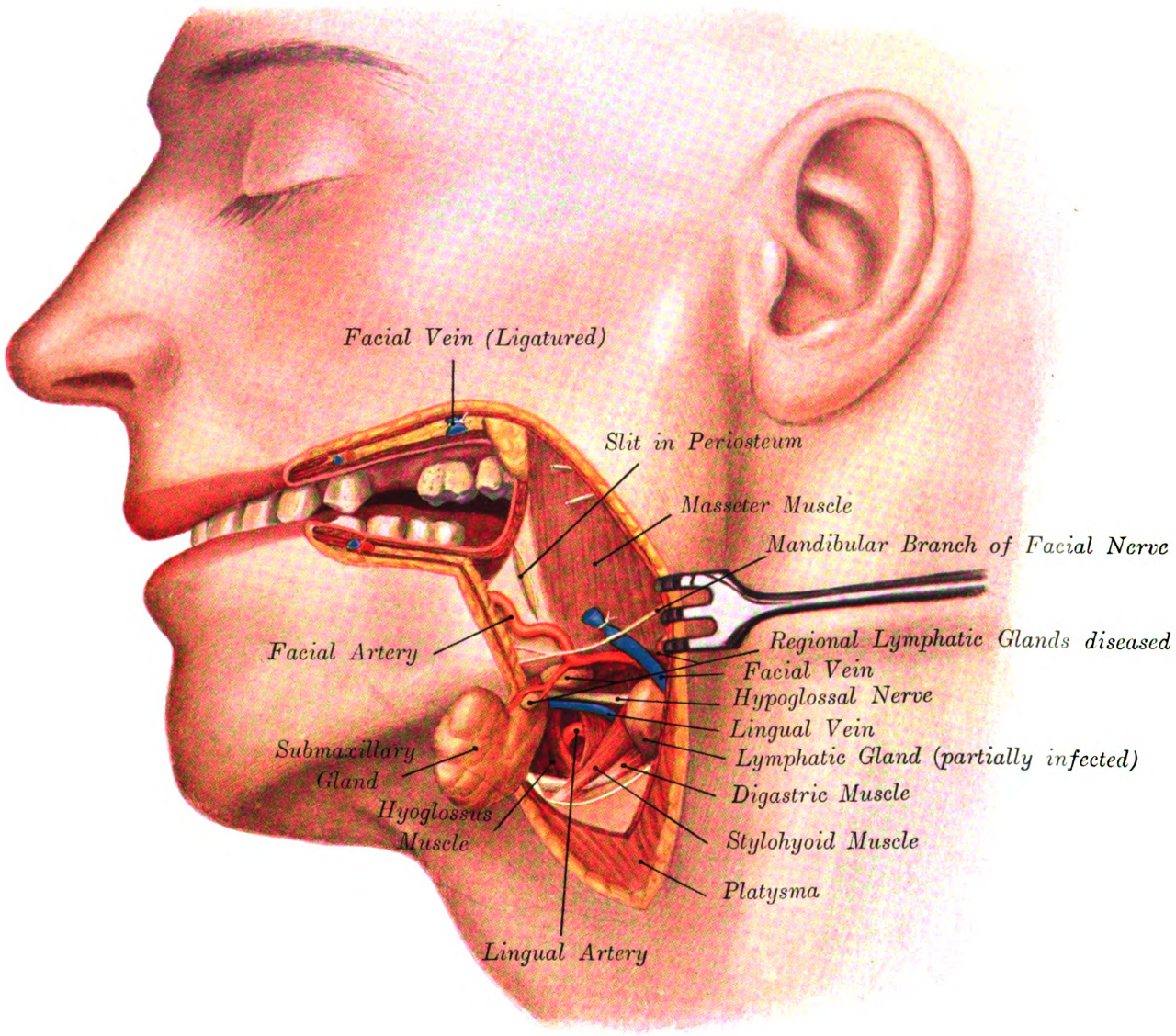

Excision of the Tongue (Stage II.).

Rebman Limited, London.

Rebman Company, New York.

Plate XIV.

Excision of the Tongue

Excision of the Tongue

STAGE 3.

Because in the majority of cases the Carcinoma is situated on the lateral aspects of the Tongue at some distance from the Tip and extends backwards, it is imperative to lay widely open the field of operation.

By this means the technique of the operation is simplified, and the trickling of a single drop of Blood into the Air passages is prevented.

To allow of section (*by sawing*) of the Lower Jaw, the Periosteum is divided along the outer surface of the Horizontal Ramus, by an incision beginning at the point of junction of the Ascending Ramus with the Horizontal Ramus.

The danger of Necrosis demands that "no marked extent of bone be denuded of its periosteum."

The inner surface of the jaw has been freed as mentioned in Stage 2.

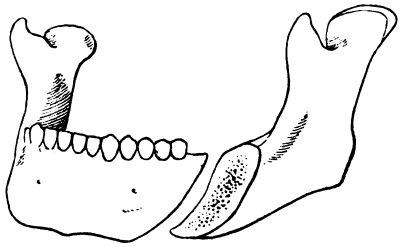

A *Gigli's* wire-saw can now be passed around the Lower Jaw by means of *Fergusson's* Needle; the Molar Tooth, at the point of section, is extracted (all carious teeth have previously been removed during the disinfection of the Buccal cavity).

The process of sawing through the Lower Jaw is accomplished in the following manner:—"The Lower Jaw is sawn from a point above and behind the junction of the Ascending with the Horizontal Ramus in a downward and forward direction, while at the same time the section is carried obliquely to the axis of the Horizontal Ramus, so that its internal margin lies anteriorly and its external posteriorly.

If the jaw be divided as here described, on readjustment of the fragments, neither can the posterior fragment be drawn upwards nor the anterior fragment drop.

After section of the Jaw, 2 hooks (*Langenbeck's*) are placed in the Inferior Dental Canal, in this manner hæmorrhage from the Inferior Dental Artery, which runs in the canal, is checked. The hooks serve as the means, when necessary, of separating widely the two fragments of bone.

If much space be required, division of the Styloglossus, Stylohoid Muscles, and Intermediate Tendon of the Diagastric Muscle, will considerably assist the separation of the bony fragments. Nevertheless, whenever it is possible, these muscles should be kept intact.

Preservation of the Lingual and Hypoglossal Nerves, when their corresponding half of the tongue is being removed, is unnecessary.

It is advisable to separate the mucous membrane of the mouth in front of the Arch of the Palate, because in this way not only is the tongue exposed from Tip to Root, but a full view is obtained of the Arch of the Palate, of the Palate itself, of the Epiglottis, of the Arytenoid Cartilages, and of the Nasopharynx. Tumours of these regions may under certain circumstances be easily removed by this route.

During the subsequent cutting out of the tumour, which must be made through healthy tissue, it is advisable to place a sponge in the Vestibule of the Larynx, so that any blood may be absorbed without prevention of the passage of air.

The tumour is cut out with a knife.

The Lingual Artery, though previously ligatured is sought for and divided, a second ligature is passed round this artery. If the disease be extensive it may be necessary to ligature the Lingual Artery on the opposite side.

The extent of Carcinomatous Infiltration is often-times difficult to appreciate in the presence of Psoriasis or Leucoplakia of the Tongue (see Figure), which are considered to predispose to Carcinoma Linguæ.

The Cancerous Tumour is often characterised by deep indentations and excrescences of cancerous exudations. The edges may merge gradually into Plaques so that the absolute limits of the Carcinoma become quite indistinguishable. If an exploratory incision should shew that the Plaque has penetrated through the aponeurosis into the muscle substance of the tongue, removal is necessary, inasmuch as it is suspected of being cancerous.

In many cases Leucoplakia extends far beyond the cancerous growth to the root of the tongue. Even where as much tongue-substance as possible has been removed, the functional result is by no means unfavourable.

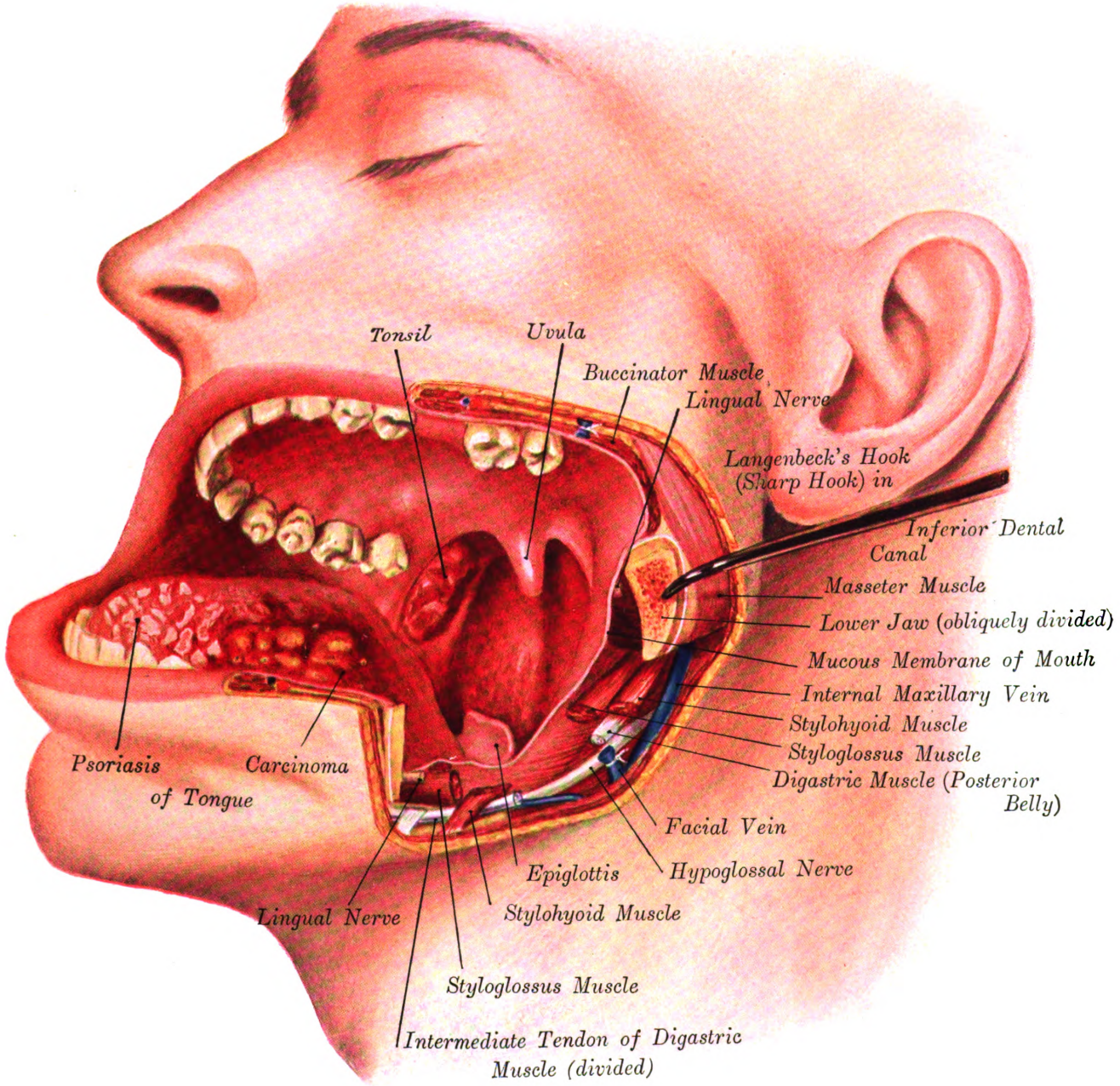

Excision of the Tongue (Stage III.).

Plate XV.

Excision of the Tongue

Excision of the Tongue

STAGE 4.

The wound of the tongue is closely stitched with deep sutures of strong silk, by this means all hæmorrhage from the substance of the Tongue is checked. The sponge may now be removed from the back of the mouth, and the fauces carefully swabbed with sponges on holders.

To obviate any infection of the Lower Jaw which requires to be reunited at a later stage, the separated mucous membrane of the floor of the mouth is approximated, a small gap only being left in the neighbourhood of the Epiglottis, so that it may later be employed as a Fistula.

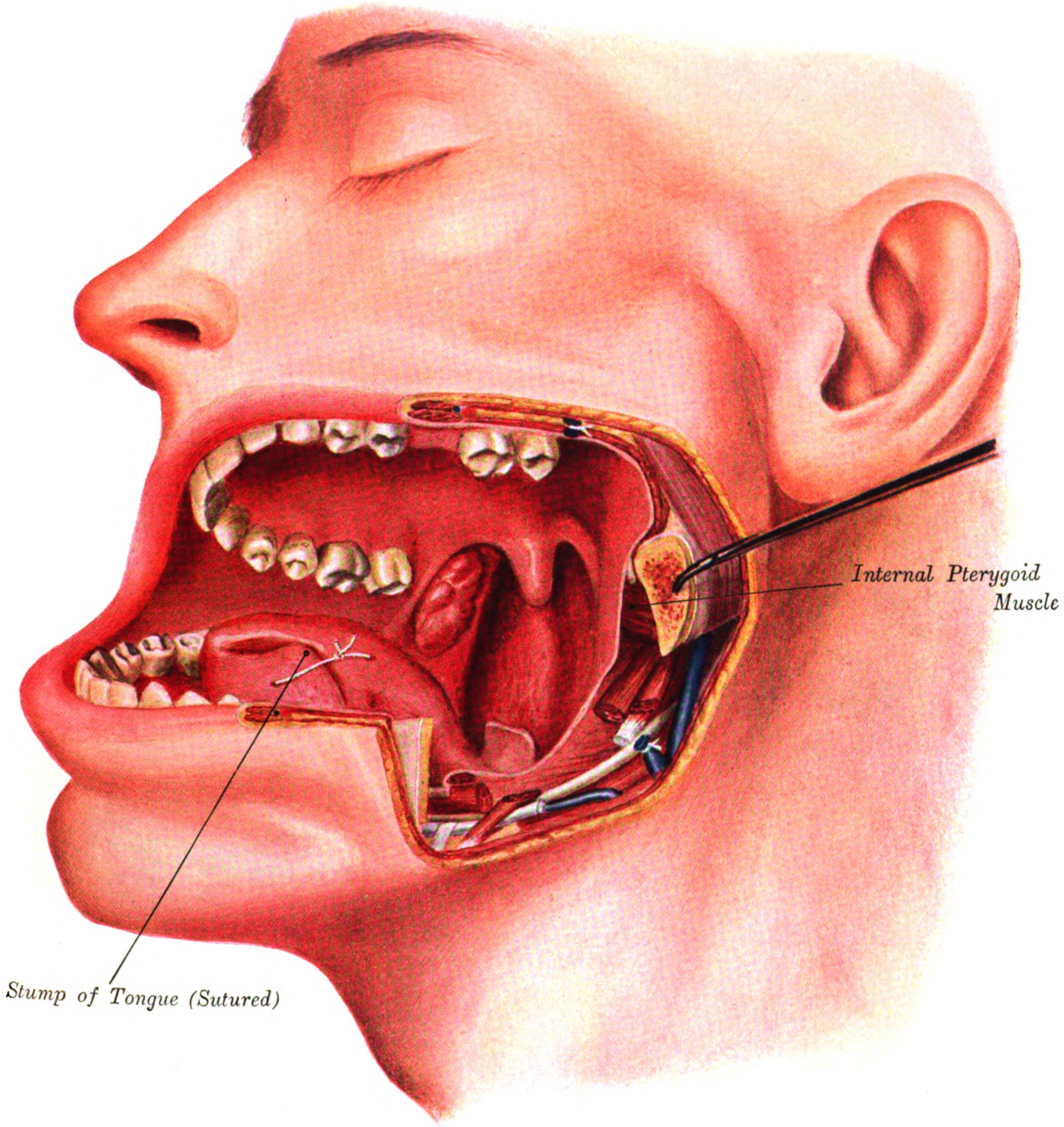

Excision of the Tongue (Stage IV.).

Plate XVI.

Excision of the Tongue

Excision of the Tongue

STAGE 5.

The divided ends of the Lower Jaw are now brought into close apposition and fixed accurately together by Aluminium-Bronze wire. The necessary holes may be made by means of a gimblet or Electro-Motor Drill.

The wire is drawn through by means of a wire director and twisted together by means of a wire-twister. These twisted ends are next bent by means of a flat-nosed pliers so as to lie flat along the jaw. We have always secured adequate apposition by means of a single suture.

The incision through the soft parts is united by (interrupted) silk-sutures which are commenced at the angle of the mouth, and do not involve the Buccal mucous membrane. The edges of the mucous membrane must be very accurately approximated at the angle of the mouth, and may be further united by a few intra-buccal sutures.

The soft parts are further united over the buried wire-suture.

According to *v. Bergmann,* it is of primary importance for favourable progress, to make a Fistula at the lower extremity of the wound. For this purpose the mucous membrane of the fauces is attached by means of a few sutures near the epiglottis, *i.e.,* to the lowest part of the fauces in the lowest angle of the wound; *in* this way a definite and satisfactory drainage of saliva is established.

During the first few days the patients are unable to swallow—consequently the saliva collects in the Pharynx or finds its way into the Lungs; the presence of a fistula obviates this collection of Saliva and thereby prevents Oedema of the neck and Bronchopneumonia.

For the first days the patient must be fed through a catheter.

Disinfection of the mouth is maintained by lotions and inhalations.

The sutures in the tongue should not be removed prior to the 8th or 10th day (Secondary Hæmorrhage).

The patient may sit up as early as the 3rd day. He soon learns to swallow; and the stump of tongue-substance, even when an extensive removal has been carried out, elongates to such a degree that speech becomes nearly normal after the lapse of a few weeks.

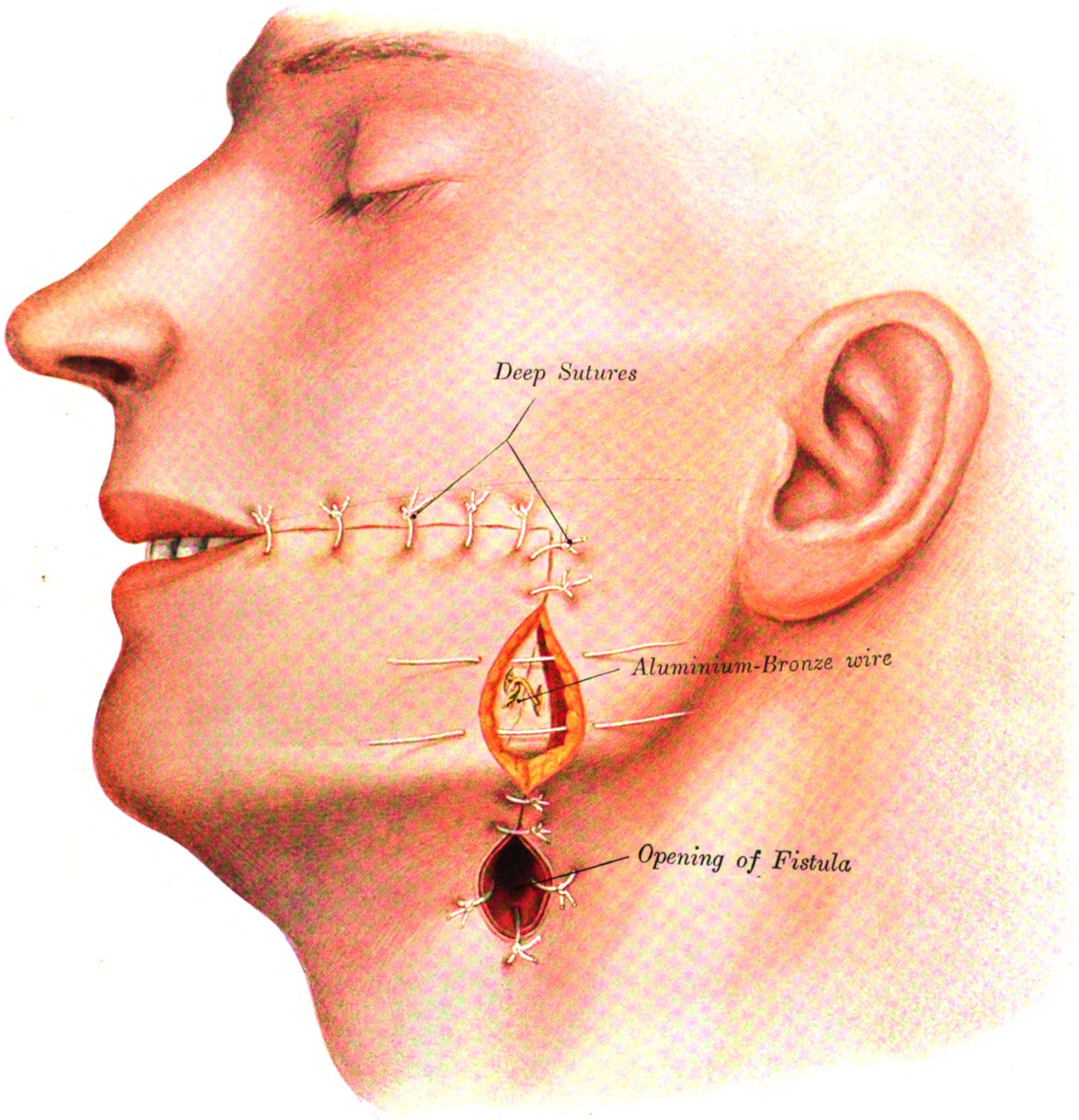

Excision of the Tongue (Stage V.).

The superficial wound heals in 8 to 10 days. Facial expression is good because the main branches of the Facial Nerve have not been injured. The slight degree of disfigurement caused by the scar, is eventually covered by the beard. (Carcinoma linguæ being most frequently met with in men.)

The Cervical Fistula closes spontaneously after a few weeks, or is stitched up after freshening the edges of the wound.

When the operation is done in accordance with this description, the after-treatment is simplified and the ultimate issue is more satisfactory.

By the adoption of this incision, the removal of lymphatic glands in the neighbourhood is accomplished with greater ease and more thoroughly than by *Kocher's* method (median section of lower jaw) with secondary removal of the Lymphatics.

A radical operation is quite justifiable, because recurrence is frequently early even after free removal and primary healing.

Plate XVII.

Gastrostomy

Plate XVII.

Gastrostomy

INSTRUMENTS

Doyen's Abdominal Retractor.

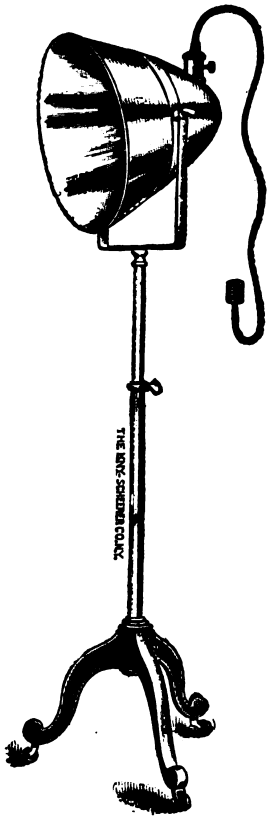

Electric Parabolic Reflector.

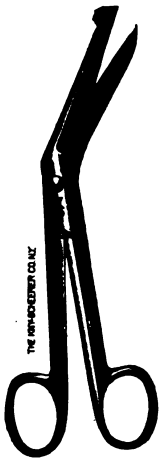

Olshausen's Peritoneal Scissors.



Olshausen's Vaginal Retractor.

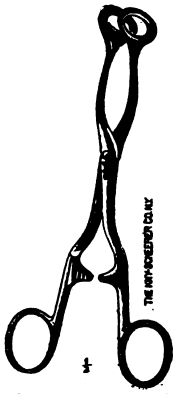

Hegar's Fenestrated Clamp.

Croenlein's Small Tissue Forceps.

Gastrostomy

STAGE I.

Preparations for Laparotomy: Evacuation of the Intestines. Gastric Lavage (frequently impossible prior to Gastrostomy); Catherization; Bath.

Disinfection of the Patient: Wash with Potash Soap; shave from Nipple to Symphysis; scrub the skin with a boiled brush for 10 minutes: wipe dry with a sterilized rough towel. Wash with Alcohol (70 to 80%) for 5 minutes. Wash with Corrosive Sublimate (1/5000) for 5 minutes. If the patient is fat, rub his skin with Ether and again disinfect with Corrosive Sublimate.

Anæsthesia: Chloroform, Ether, Oxygen and Chloroform, or Oxygen and Ether. (*Roth-Dräger* apparatus.)

If the patient is in feeble state *Schleich's* Anæsthesia. (Saline and Cocaine Subcutaneously. Infiltration Anæsthesia.)

Position: Horizontal position on a warmed table; legs well wrapped up; head slightly raised by a wedge-shaped cushion.

Operation:

The Surgeon standing on the right side of the patient, renders tense the skin of a flaccid abdominal wall by pulling upwards with his left hand while his assistant pulls the skin downwards.

The incision commencing directly over the Ensiform Process, is carried down exactly in the middle line as far as the Umbilicus. (Mesial Supra-Umbilical Laparotomy.)

It is advisable at first to make only a small incision through Skin and Superficial Fascia on to the Linea Alba (which in the Epigastric region is 1 to 2 cm. (2/5ths to 4/5ths inch) in width; consisting of dense fibres which decussate in the middle line, and are derived from both the Anterior and Posterior Lamellæ of the Sheaths of the Recti Muscles). The Fascia Transversalis exists only where the Transversalis is Muscular and consequently is absent in this region.

The Peritoneum may be met with immediately after cutting through the Linea Alba, but generally fat is present in such quantity as to form a distinct pre- or properitoneal fatty pad, which definitely separates the Linea Alba and Peritoneum from one another.

Before opening the Peritoneum complete hæmostasis is necessary.

The Peritoneum is now cautiously pulled upwards, by means of toothed-forceps, in a transverse fold and divided between the forceps.

Through this small opening the Peritoneum is divided throughout the whole length of the superficial incision. If the incision be of insufficient length for the purpose of the surgeon, then it may be enlarged downwards in the middle line; it is advisable to carry the incision through the periphery of the Umbilicus which is subsequently excised (*v. Mikulicz*). When the abdominal cavity has been opened, the peritoneal edges should be seized on both sides with forceps, on account of its tendency to retract in prolonged operations.

Prior to opening the abdominal cavity, the assistant has covered the entire skin with sterilized dressings, attached to the skin by suitable clips, so that any prolapsed intestines may lie on the dressings.

We shall refer later to pathological conditions of the Peritoneum, Abdomen and Intestines, because the conditions are not complicated in making a Gastric Fistula.

In the majority of cases we have to deal with emaciated individuals, inasmuch as the Indications for operation are based upon Oesophageal Obstruction, or Obstruction at the Cardiac end of the Stomach. (Tumours, Cicatrices, Stenosis as the result of Caustics, Diverticula, Foreign Bodies.)

Accordingly, when the Abdominal Cavity is laid open the Intestines are usually collapsed; the Stomach markedly contracted (is found lying posteriorly and more on the left side of the Vertebral Column).

The Stomach is recognised and distinguished from the Transverse Colon by the course of its vessels and the absence of the Omental Covering. The Omentum can be employed as a guide in seeking the Stomach.

In establishing a Gastric Fistula according to the method introduced by *v. Bergmann,* a piece of the Anterior wall of the Stomach 8 to 10 cm. (3 1/5-4 inches) long above the greater curvature and at some distance from the Pylorus, is seized with a Forceps and pulled vertically into the Laparotomy-wound. The base of this process is now stitched peripherally, with 20 to 30 silk sutures, to the Parietal Peritoneum so that the Liver which is evident in the drawing is completely obliterated from view.

Of the layers of the Stomach only the Serous and Muscular coats (as far as the elastic layers of the loose connective submucous tissue) are taken in with the stitches.

The accomplishment of this so-called Sero-Muscular suture can only be acquired with precision by practice.

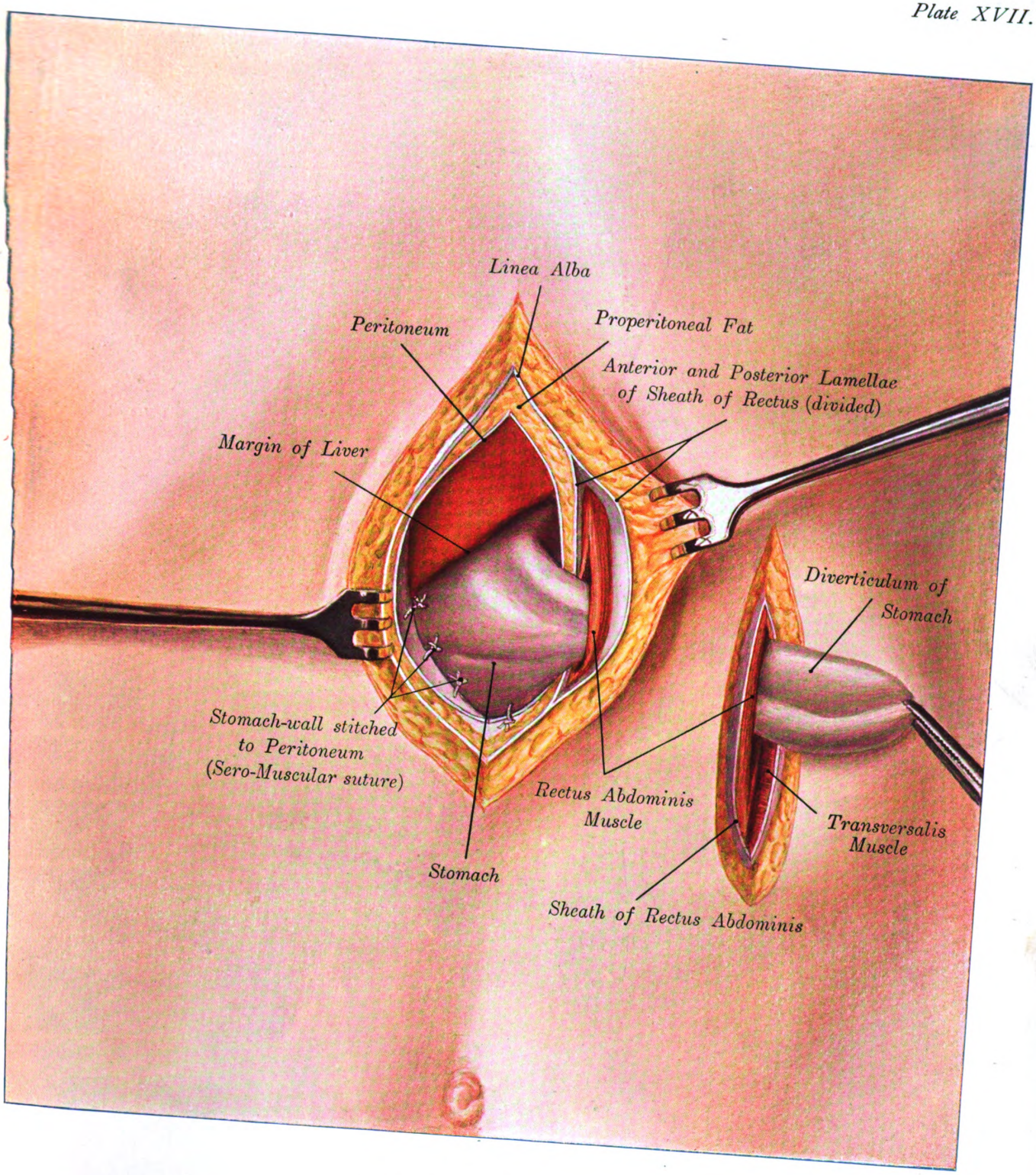

Gastrostomy (Stage I.).

Rebman Limited, London.

Rebman Company, New York.

The peritoneal cavity is completely shut off by this anchored portion of the Stomach.

A second incision through the Skin is made at the outer border of the Rectus Muscle, commencing at a point lower than but parallel to the median incision; length 6 to 8 cm. (2 2/5-3 1/5 inches).

When the superficial fascia has been divided, and the anterior lamella of the sheath of the Rectus opened, a curved pair of Forceps is forced through the substance of the muscle in the direction of the mesial border of the Rectus, where this sheath had been opened in the course of the Laparotomy-incision or is now penetrated. The end of the sutured part of the Stomach is secured by the forceps, and drawn through the substance of the Rectus Muscle into the second wound.

It stands to reason, therefore, that the Operator must secure a portion of the Stomach of sufficient length to allow of this degree of traction.

Plate XVIII.

Gastrostomy.

Gastrostomy

STAGE 2.

In this second cutaneous wound the process of Stomach is fixed by a silk suture (sero-muscular) to the soft parts. The apex of this elongated diverticulum is opened, so that the mucous membrane can be sutured to the skin and form lips to the Fistula.

A thin rubber catheter is introduced into this Fistula, and normal saline solution into the patient by means of a syringe, thus at the same time the efficiency of the closure of the fistula is tested. The skin above and below the fistula is sutured.

As the Peritoneum is sutured to the Gastric Diverticulum, the usual method of closing the Mesial Abdominal wound is not the means here employed. We shall, therefore, consider the typical process of abdominal suturing at a subsequent period.

In this instance, 3 deep silk-sutures, traversing all the soft parts, are employed; before tying these sutures, several buried catgut-stitches are passed to repair the Linea Alba by union of the divided sheath of the Rectus.

The 3 silk-sutures are now tied and the skin is sewn together by a series of superficial stitches. Upon the wound thus sewn up sterilized gauze is placed, being retained in position by strips of adhesive-plaster; over this a protective dressing is adjusted. This affords considerable comfort to the patient, and allows him to cough without pain.

The Gastric Fistula, the object of which is to feed the patient either temporarily or permanently, must, under all circumstances, close firmly, because the flow of Gastric Juice from the Fistula produces "Peptic Eczema."

Von Bergmann's method is easy to carry out. From the point of view of adequate closure we have obtained good results. As the mucous membrane is sutured to the skin, even during the first few days, a catheter can easily and safely be introduced.

Food must at first be supplied in small quantities owing to the general contracted state of the Stomach (Danger of Acute Dilatation of the Stomach).

We consider there is no necessity for the application of a belt after Gastrostomy.

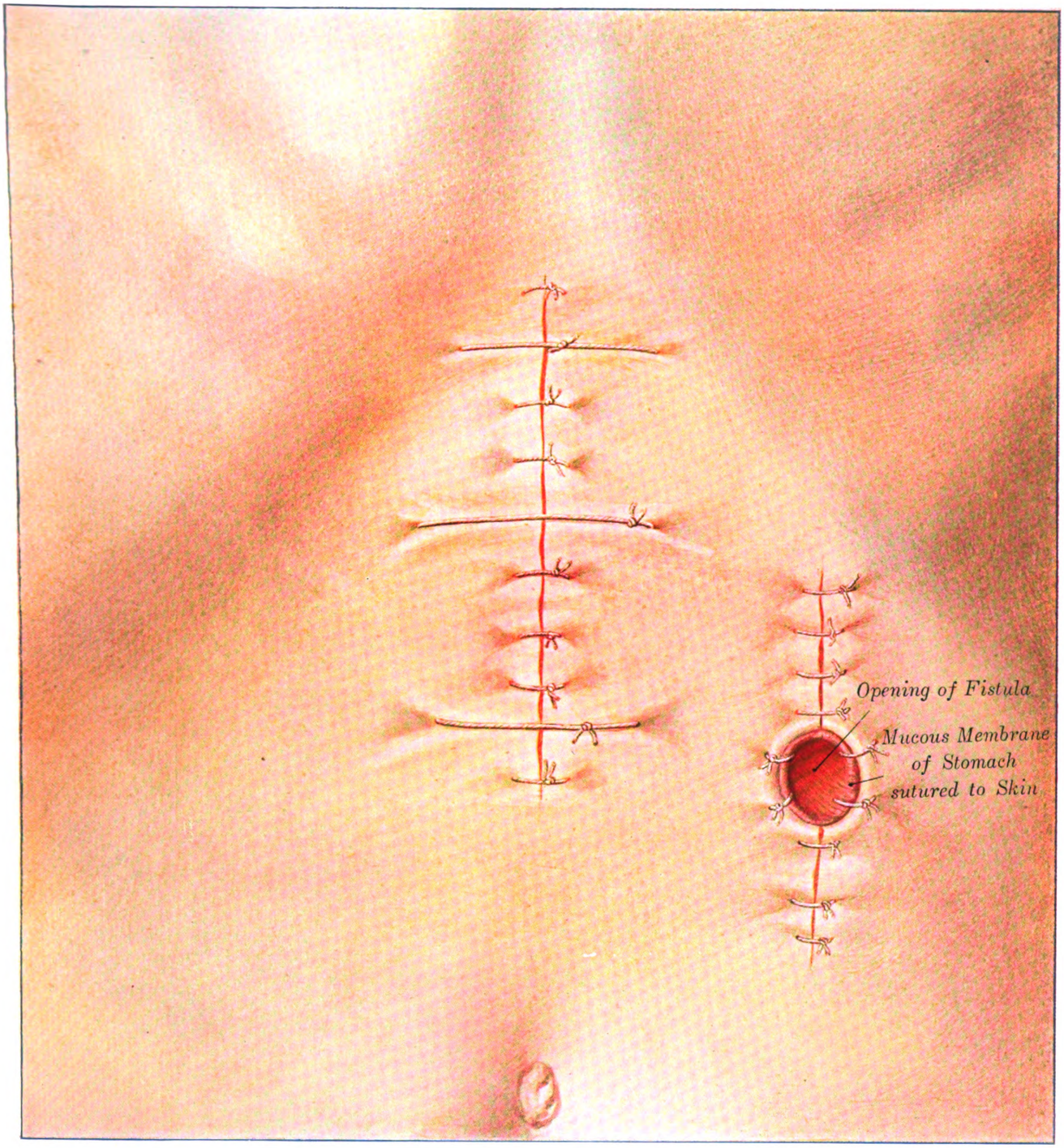

Gastrostomy (Stage II.).

Plate XIX.

Excision of the Larynx.

Plate XIX.

Excision of the Larynx

INSTRUMENTS

Gwathmey's Inhaler Combined for nitrous oxide gas, ether and Ethyl Chloride; also adapted for the administration of oxygen gas.

Waldenburg's Laryngeal Scissors.

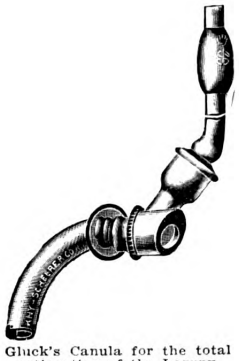

Gluck's Canula for the total extirpation of the Larynx.

Bruns' Artificial Larynx.

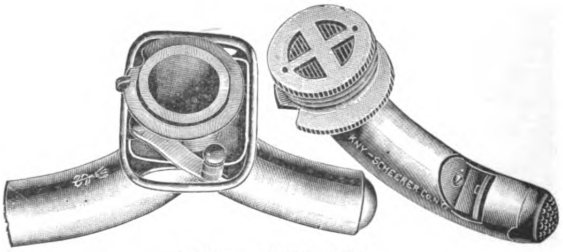

Wolff's Artificial Larynx.

Excision of the Larynx

STAGE I.

In certain cases of Laryngeal Disease the diagnosis is not definitely cleared up by Laryngoscopical Examination; it therefore becomes necessary, prior to having recourse to one of the various Laryngeal Operations, to remove a small portion from the interior of the Larynx for a further confirmatory diagnosis by microscopical examination. It is well known that this method is not infallible in accurate and reliable information; moreover, the laryngoscopical examination frequently fails to give such definite information concerning the exact position and extent of the disease, as is necessary for guidance in the choice of any particular operation.

Whereas benign tumours, if not too large, may be removed by an intra-laryngeal operation, malignant growths must be attacked from without.

Age and Diseases of the Respiratory Tract are contra-indications to the open operations.

There is a general tendency to operation in the case of malignant tumours if local metastases are not extensive, if the muscle substance be not infiltrated, if the larynx be not perforated by the tumour, and if externally there be found no markedly inflamed glands.

The Clinical History, Laryngoscopical and Digital Examinations, must decide as to whether the Pharynx has been extensively involved.

Impassable Strictures and Stenoses are also to be treated by operative means, whereas Tuberculous and Syphilitic affections are treated by the usual methods.

Injuries, Fractures and Foreign Bodies also justify an operation.

Preparation: Disinfection of the Buccal Cavity, Extraction of Carious teeth, etc.

Anæsthesia: Chloroform or Chloroform-Oxygen (*Roth-Dräger*), or without general Anæsthesia by Cocaine (5 % solution).

Position of Patient: A cushion is placed under both shoulders, so that the head may be well extended, and the anterior aspect of the neck rendered markedly prominent. The head is kept low after *Rose's* method (the head in a dependent position) or the body is kept low according to *Kocher's* method.

Large incisions should be made in every instance. The incision beginning in the middle line above the Hyoid Bone, is continued into the Jugular Fossa (Suprasternal Notch).—The skin and superficial fascia are divided, and the yellow

ish-white band, previously mentioned in connection with High Tracheotomy, between the two Sternohyoid Muscles, is exposed. This band is divided throughout its whole length, the Sterno-hyoid muscles are retracted to either side by blunt hooks so that

in the upper part of the wound:	Hyoid Bone, Thyreohyoid Ligament, Thyreoid Cartilage.
in the middle " " " "	Cricoid Cartilage, Ligamentum Conicum (Central portion of Cricothyreoid Membrane), Cricothyreoid Muscle and Cricoid Cartilage.
in the lower " " " "	Isthmus of Thyreoid Gland with extensive Venous Plexus, are exposed to view.

All veins should be carefully ligatured to prevent subsequent oozing; in the present stage the following veins need attention:—Median Vein of Neck, Anterior Jugular Vein and the Communicating Branch of the Inferior Thyreoid Veins.

The Low Tracheotomy, which is now to be performed (we prefer this to the High Operation because it is further from the field of operation and interferes less with the manipulations of the surgeon) preparatory to a subsequent tamponading of the Trachea, is designed to prevent any blood from flowing into the Lungs (Bronchopneumonia), and to simplify the operation in its direct relation to the Larynx. Some surgeons perform the Low Tracheotomy a few days before the operation on the Larynx proper.

If the Isthmus of the Thyreoid Gland be markedly enlarged (Goitre), in order to expose the Trachea, it may be necessary to separate it on both sides and divide in the middle line by means of a *Paquelin's* Thermo-cautery. Usually, however, the lower border of the Isthmus is easily separated with Forceps.

To gain access to the Trachea, the lower border of Isthmus of the Thyreoid is drawn upwards with a blunt hook, the operator then proceeds to puncture exactly in the middle line with a blunt pointed forceps.

The Low Tracheotomy is a more difficult operation than the High Tracheotomy because:—

1. The Trachea is more deeply situated in the former.
2. There is present a large Venous plexus.
3. There occasionally exists a Thyreoidea Ima Artery.

These vessels must be ligatured with double ligatures.

When the Thachea is reached it is pulled, with a sharp hook, into the wound; several rings are well exposed, and an incision is made exactly in the middle line.

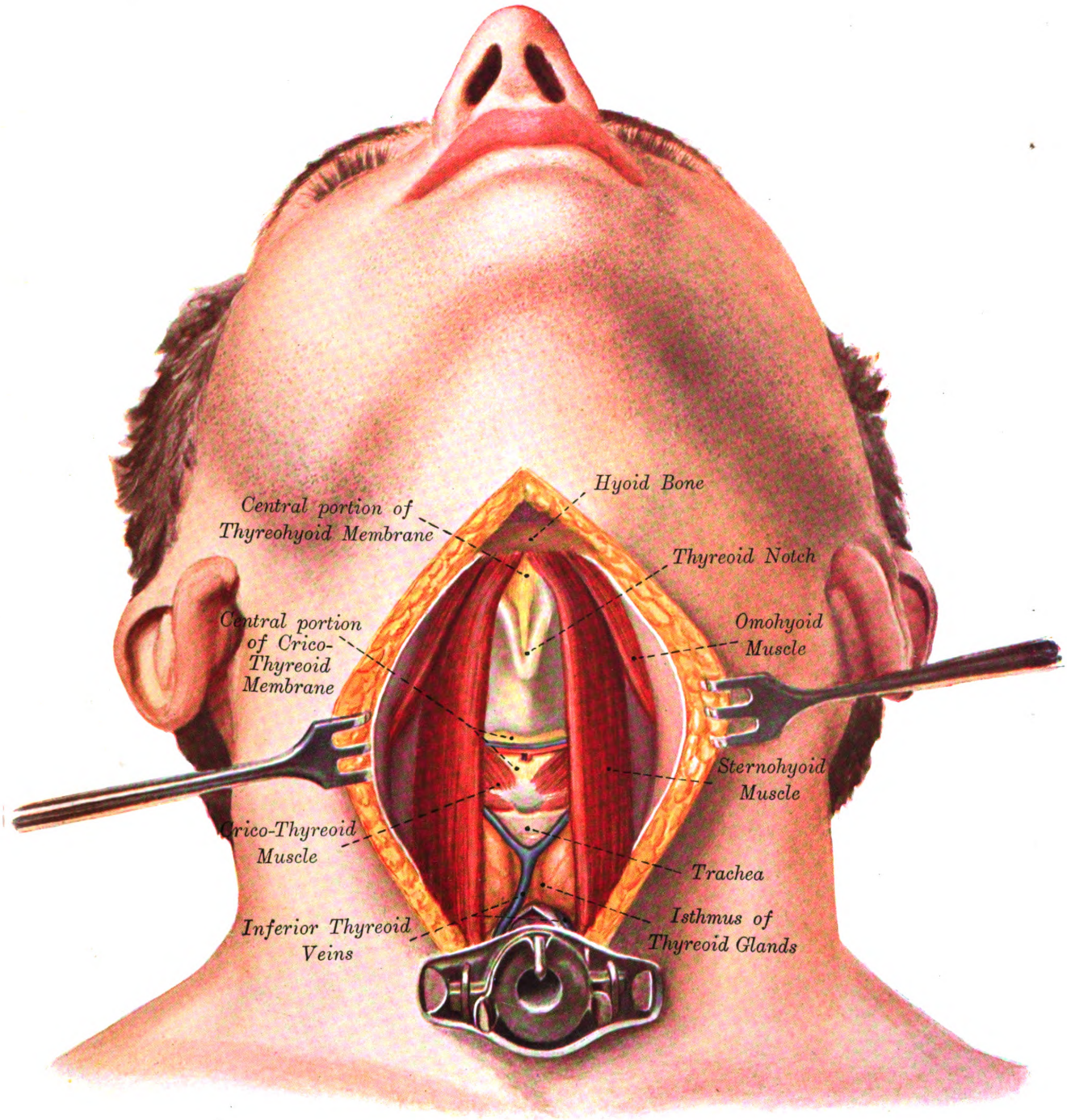

Excision of Larynx (Stage I.).

Plate XX.

Excision of the Larynx.

Excision of the Larynx

STAGE 2.

Hahn's Tampon-canula is now introduced for tamponading. This consists of a silver canula enveloped by compressed sponge, which is dipped in water and rapidly introduced into the wound of the Trachea before the sponge can become too swelled out; the Tracheal wound is held open by sharp hooks.

The Canula has a portion for the adjustment of the Chloroform Apparatus which should now be employed (cf. Part I).

Hahn's canula is preferable to *Trendelenburg's,* because the rubber ampulla of the latter is not so easily adapted, and accordingly does not ensure so perfect a closure of the Trachea.

When the operation is completed the Tampon-Canula is replaced by an ordinary canula; because, if left too long in the wound, it produces pressure-ulceration, and when the sponge has completely swollen it allows blood to pass, and thus favours Broncho-pneumonia.

In cases of Laryngo-fissure median section of the Thyreoid Cartilage affords the clearest and widest view. The Cricoid as a point of support for the Larynx should be left intact. The Conical Central Portion of the Crico-Thyreoid Membrane serves as a guide, the vessels which lie upon the Ligament are ligatured.

Should the so-called Lobus Pyramidalis, forming a median Thyreoid lobe, obscure the topography, this must be isolated by blunt dissection and pulled aside or in a downward direction.

Before the Thyreoid Cartilage is divided, the knife is pushed vertically through the median portion of the Crico-Thyreoid Membrane at the upper border of the Cricoid Cartilage, ensuring division of the mucous membrane; this is ascertained by the introduction of sharp hooks.

The Vocal cords are now in view, so that division of the Thyreoid Cartilage can be made between their anterior extremities exactly in the middle line (*Kocher*). The Cartilage is bisected by means of special laryngeal scissors.

After division, sharp hooks are introduced to pull the two Cartilaginous Plates of the Thyreoid apart. In this way a complete view of the whole of the interior of the Larynx can be obtained. A still better view is secured by division of the Epiglottis.

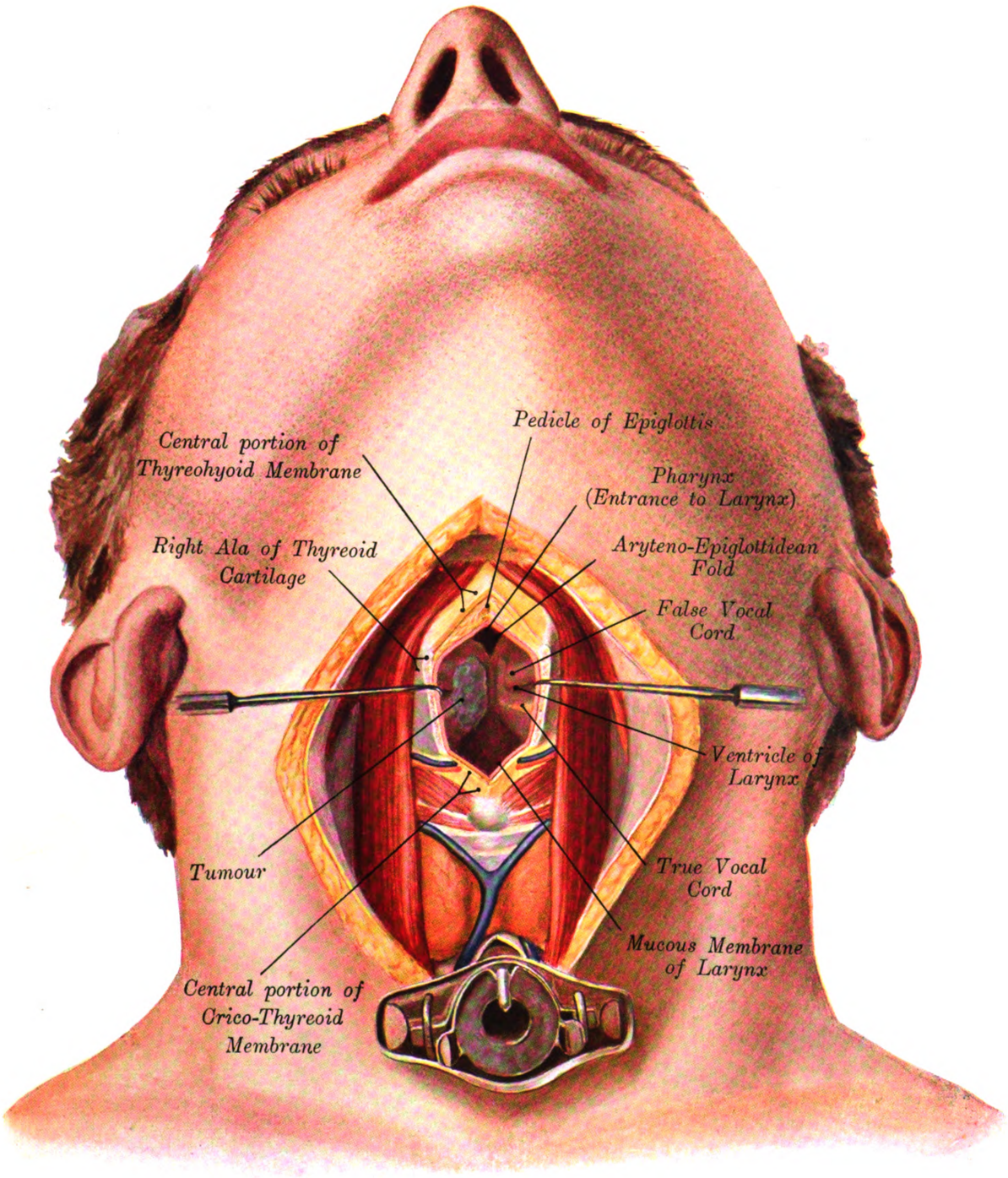

Excision of Larynx (Stage II.).

Rebman Limited, London.

Rebman Company, New York.

Small circumscribed tumours of the mucous membrane can be removed with the knife, and the raw surface cauterised with a *Paquelin's* Thermo-cautery.

If the Tumour be firmly attached, then, under all circumstances, the cartilage must be removed; and if necessary, any infiltrated muscle tissue on the external aspect of the Larynx. The excision must in all cases be made through perfectly healthy tissue.

The Cartilaginous Plates of the Thyreoid Cartilage are, with ease, both well and correctly apposed (if not calcified) by means of catgut sutures.

The edges of the skin wound are sutured with silk.

The Vulcanite Canula introduced at the end of the operation is retained for three or four days; at night the head is placed low. Cautious observation of the patient after removal of the Canula is absolutely necessary in case œdema of the Glottis supervenes.

Excision of the Larynx

STAGE 3.

Whereas in those cases in which the actual extension of the disease is indefinite, Laryngo-fissure with a preliminary Tracheotomy is performed as in stages 1 and 2, so that unilateral or total excision of the Larynx (Stages 3 and 4) may subsequently be carried out; nevertheless, with the primary intention of total extirpation, this procedure may be undertaken forthwith as described in stages 3 and 4.

The incision for total Extirpation is commenced as high up as the Submental Region. In extensive operations transverse incisions are carried across from one Sterno-Cleido-Mastoid to the other, either at the upper extremity only (T-shaped incision), or at both extremities (*Bardenheuer's* swing-door flap incision).

The Sterno-hyoid and deeper muscles are retracted by blunt hooks.

Kocher severs the attachments of the Sterno-hyoid, Omohyoid and Thyreo-hyoid muscles to the lower border of the Hyoid Bone, and thus obtains an excellent view. The Larynx is first exposed on the Left side, being drawn forwards and to the right by a sharp hook.

The Thyreo-hyoid and Sterno-thyreoid muscles are divided at their attachments to the Oblique line of the Thyreoid Cartilage. Posteriorly the Thyreo-Pharyngeus (the portion of the Inferior Constrictor of the Pharynx which is attached to the Thyreoid Cartilage) muscle is cut. In order to completely separate the Inferior Constrictor muscle, the second attachment, viz., the Crico-Pharyngeus, must be severed from the Cricoid Cartilage.

The Crico-Thyreoid may be left untouched. In this manner the Superior Cornu and the posterior border of the Thyreoid Cartilage, and the posterior aspect of the Cricoid Cartilage, are exposed.

The separation of the right side is carried out in a similar manner, the freed left half being drawn to the left.

For the further separation of the Larynx, it is necessary to divide both Superior Cornua by means of a small cartilage-scissors. Directly above the Cornua the Superior Laryngeal vessels come clearly into view. They are immediately ligatured. Prior to the recent step it was not possible for any blood to gain access to the air-passages.

In order to prevent any trickling of blood into the air-passages during the remainder of the operation, transverse division of the Trachea, as devised by *Gluck,* is carried out, and the Trachea is drawn forwards through the lower angle of the wound away from the field of operation in a manner to be described later.

To carry this out, the 1st and 2nd rings of the Trachea are carefully separated from the Oesophagus (which is a posterior relation) into which a Catheter has been introduced.

An elevator is placed between the Oesophagus and Trachea, and the Cricoid Cartilage severed from the Trachea, commencing at the Tracheo-Cricoid Ligament.

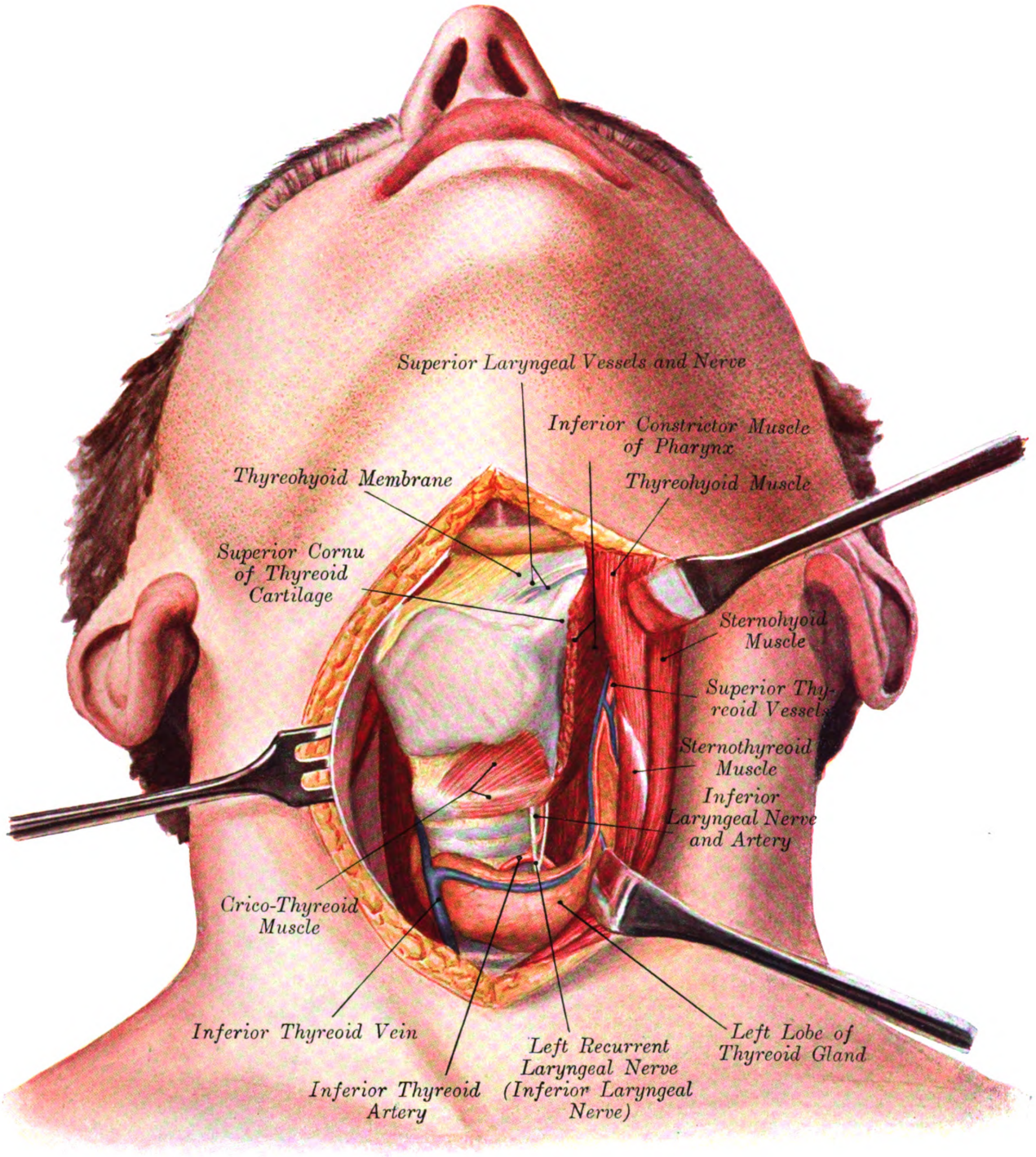

Excision of Larynx (Stage III.)

Plate XXII.

Excision of the Larynx.

Excision of the Larynx

STAGE 4.

The Trachea thus severed is fixed with strong silk-sutures which take in the whole of the 1st, or even 1st and 2nd, rings; the Trachea is pulled forwards by means of these sutures; behind is placed a tampon, whereas a closely-fitting Vulcanite Canula is introduced. The operation can be continued without any danger to the Lungs; accordingly, by this method a preliminary Tracheotomy is not required (*Perier*).

To completely detach the Larynx from the Pharynx a blunt hook is introduced into the lumen of the Cricoid Cartilage, and the Larynx drawn upwards.

When the lower fibres of the Crico-Pharyngeus muscle which merge into the Oesophagus are left intact during the separation of the Inferior Constrictor at the side, these fibres would be rendered tense by the traction on the hook, and thus be easily severed. At the same time the Oesophagus and Pharynx retract away from the lower part of the Cricoid Cartilage.

The Inferior Laryngeal Nerve (Recurrent Laryngeal Nerve) is injured during this manipulation (this is of no importance); the artery of the same name is ligatured.

In the subsequent separation of the Larynx, the operator proceeds with caution, employing a blunt pointed scissors, and notching towards the posterior aspect of the larynx; by this method no injury is done to the pharyngeal mucous membrane, which is here only separated by the sub-mucous layer.

The posterior surface of the Larynx having been exposed, the Thyreo-hyoid membrane is divided at the upper border of the Thyreoid Cartilage, whereas the incision is carried through the Stalk of the Epiglottis.

In the division of the Laryngeal mucous membrane considerable care should be exercised to avoid injury of the Aryteno-Epiglottidean Fold, and of the minute Cartilaginous Bodies (indicated in the figure) which lie within these Folds; as they connect the Arytenoid Cartilage with the Epiglottis (this precaution need only be exercised when these tissues are healthy). In this way a cylindrical pillar of laryngeal mucous membrane remains,—the Aditus ad Laryngem (The Vestibule of the Larynx).

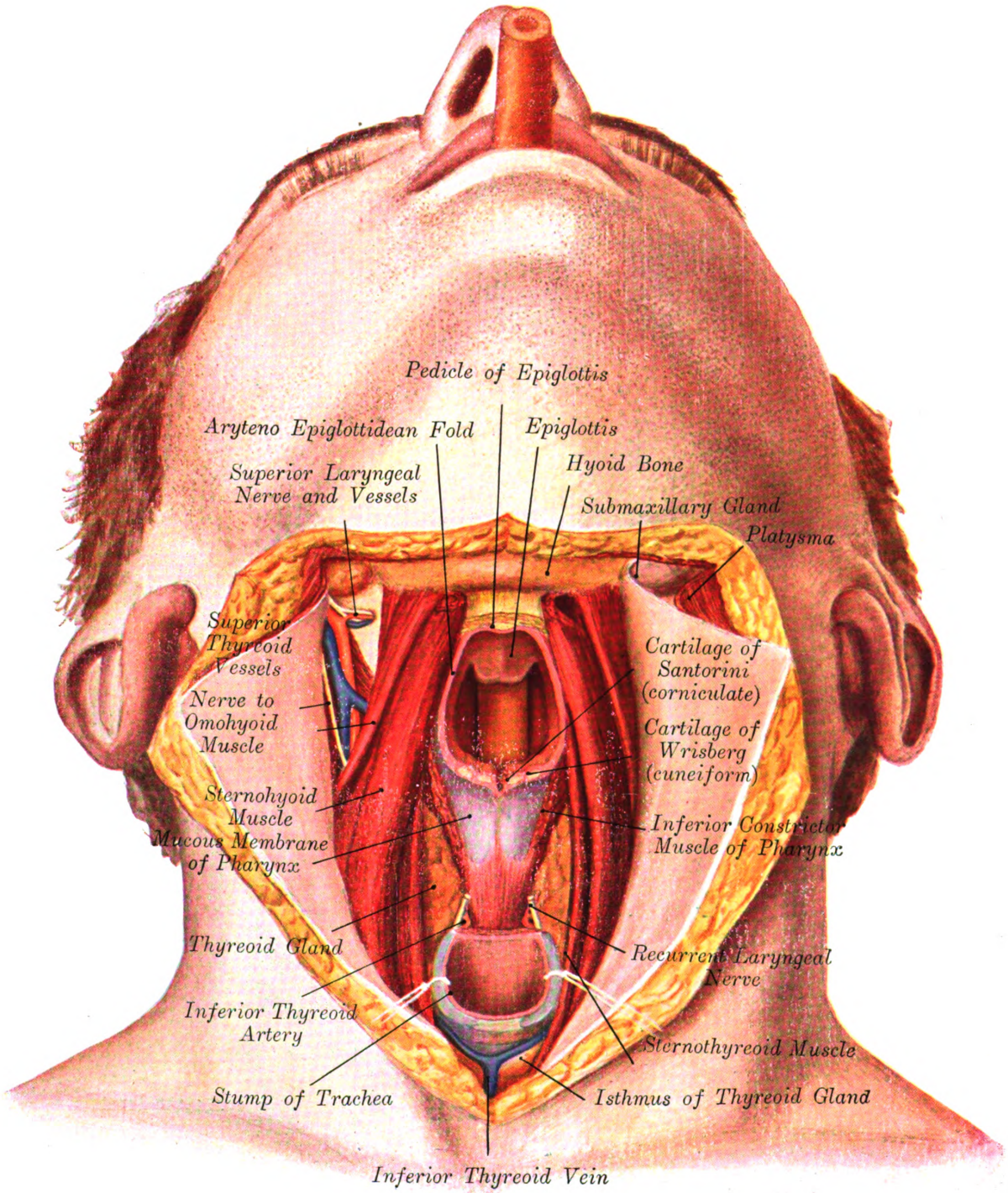

Excision of Larynx (Stage IV.).

Rebman Limited, London.

Rebman Company, New York.

If the disease be very extensive the wall of the Pharynx, Muscles, etc., must also be removed. *Gluck* cuts across both Sterno-Mastoid Muscles in these cases, so as to obtain more room.

Unilateral excision cannot be regarded as a typical operation, because each individual case calls for its necessary modification. Whereas in partial excision and even in unilateral excision the functional results are satisfactory, yet in cases of total extirpation it is necessary at a subsequent operation (Laryngoplasty) to introduce an Artificial Larynx.

The models devised by *Julius Wolff,* by *v. Bruns* and by *Gluck* are the most satisfactory.

Plate XXIII.

Excision of the Larynx.

Excision of the Larynx

STAGE 5.

The subsequent technical procedure is directed to secure protection to the Trachea and closure of the open Vestibule of the Larynx.

The Aditus ad Laryngem, which has been left by the operation, may be completely closed above, because for whispering the Trachea need not communicate with the Pharynx. If there be no necessity for the removal of any part of the wall of the Pharynx the closing can be easily carried out.

The Pharyngeal Mucous Membrane is stitched to the freshened Epiglottis, the membrane being turned directly inwards.

Superficial to the mucous membrane, the Inferior Constrictors previously freed on both sides are stitched together by means of catgut-sutures, next in order the Sterno-hyoid Muscles which had been pulled aside.

The Trachea is circumferentially sutured to the skin. The skin-flaps are placed in their original position and united accurately by suture, a gap being left in the upper part of the wound for drainage. By this means a Septum is established between the Air-passage and the Alimentary Canal. This is of considerable importance at the outset in order to obviate Pneumonia and Mediastinitis.

The stump of the Larynx can also be sewn to the skin, as shown in the picture; but under these circumstances it is necessary to apply absorbent dressings so as to remove the secretions of the Mouth and Fauces, and thus prevent trickling into the external opening of the Trachea.

This method is probably even better than the Epiglottideo-pharyngeal suture described. If this latter should give way, mucus, etc., can flow without being observed downwards, behind the Trachea, and infect the Mediastinum.

During the first few days it is of the utmost importance to avoid Pneumonia and Mediastinitis. This is the object we seek to attain by our method of operation and by the after-treatment—allowing the patient to get up on the 2nd or 3rd day and keeping his head low at night-time. At first, food must be given through a catheter.

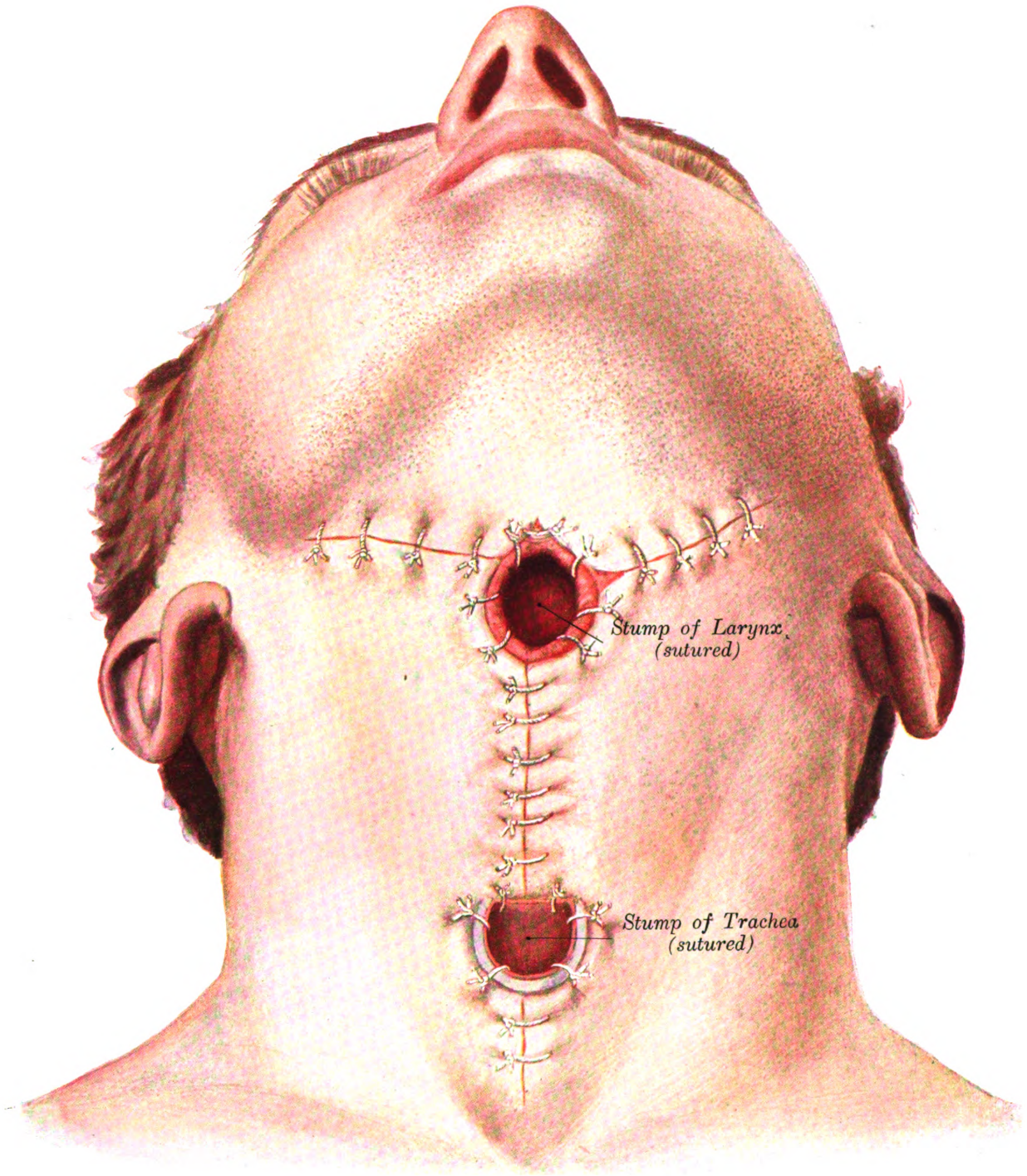

Excision of Larynx (Stage V.).

Plate XXIV.

Resection of a Rib

Plate XXIV.

Resection of a Rib.

INSTRUMENTS



Sayre's Periosteotome.

Ollier's Raspatory

Langenbeck's Bone Holding Forceps.

Rib Shears with eccentric sliding lock.

Bone File.

Gluck's Rib Shears.

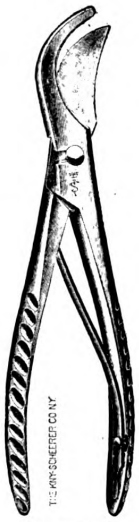

Rib Shears; plain.

Hydrocele Trocar with Stopcock.

Thomas' Glass Drainage Tube.

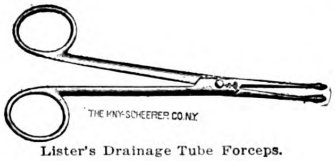

Lister's Drainage Tube Forceps.

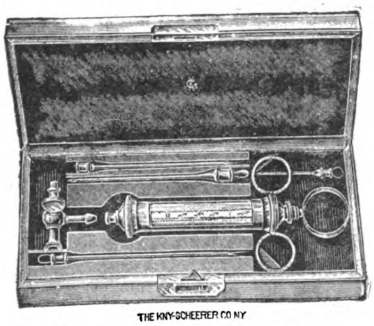

Pocket Aspirator; 2 drams capacity.



Dieulafoy's Aspirator.

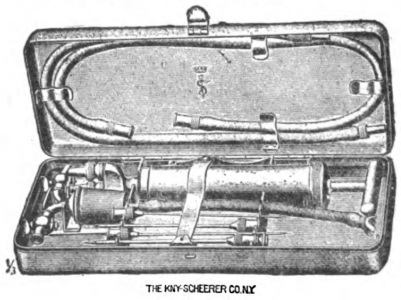

Potain's Aspirator.

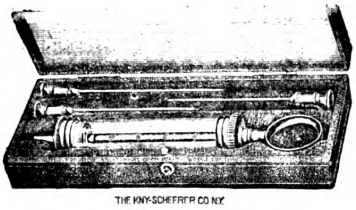

Schede's Aspirator.

Resection of a Rib

Position:—The patient lies in a semi-prone position upon the healthy side. Complete lateral cubitus in cases of pleural exudation may prove fatal. (*Paget.*)

Anæsthesia: Ether or Chloroform. The former is to be avoided in Pulmonary affections. If the lungs are already perforated and in a condition of collapse *Schleich's* Anæsthesia (Infiltration Anæsthesia) or none at all is recommended. When the ribs are diseased the modus operandi is self-evident.

In the treatment of exudations the choice lies between resection of the 5th or 6th rib in the mid-axillary line (*König*), or of the 9th (possibly the 10th) rib in the Scapular line. The latter is preferred for drainage purposes, which are, at this point, more favourable.

Resection of a Rib in non-purulent exudations has already become an Indicatio Vitalis, when the exudation ascends to the 3rd rib and produces compression on the heart.

Purulent exudations under the circumstances call for immediate drainage: if localised the resection is performed at the lowest point of the collection.

In performing the operation, the soft parts, as much as possible, are pulled down and the incision carried through them directly down to the rib along the axis of the rib. The incision is 8 to 10 cm. (3-4 inches) long, beginning just external to the angle of the rib (cf. Plate), at the point of origin of the Ilio-Costalis Muscle, and where the only muscle divided is the Latissimus Dorsi.

The Periosteum is completely separated from the rib by means of a rugine, to the extent of 4-6 cm. (1¾ to 2½ ins.) in the child, 6 to 8 cm. (2½ to 3¼ ins.) in the adult, being incised at both ends in a |—| shaped manner.

The attachment of muscles to the borders of the rib sometimes needs detachment. At the inferior border the operator must guard against injury to the Artery, which, if injured, is more easily secured after removal of the rib than at an earlier stage.

The Periosteum being completely freed and the rib levered by the passage of a rugine behind it, the bone is cut through with a costotome (or wire-saw).

If the soft parts are forcibly retracted, the incision will allow of the removal of the adjacent upper and lower ribs.

In the act of opening into the Pleural Cavity (Pleurotomy) the Periosteum and Pleura are first divided in the longitudinal axis of the rib removed. The incision, when dealing with exudations, should not be large so as to avoid collapse resulting from the too rapid evacuation of the fluid.

But the opening must be large enough to admit of the introduction of a drainage tube which should only reach into the Pleural Cavity and have a diameter of 1 to 1¼ inches. In order to prevent this tube from slipping into the Pleural Cavity it is necessary to fix it to the applied dressings by means of a safety pin.

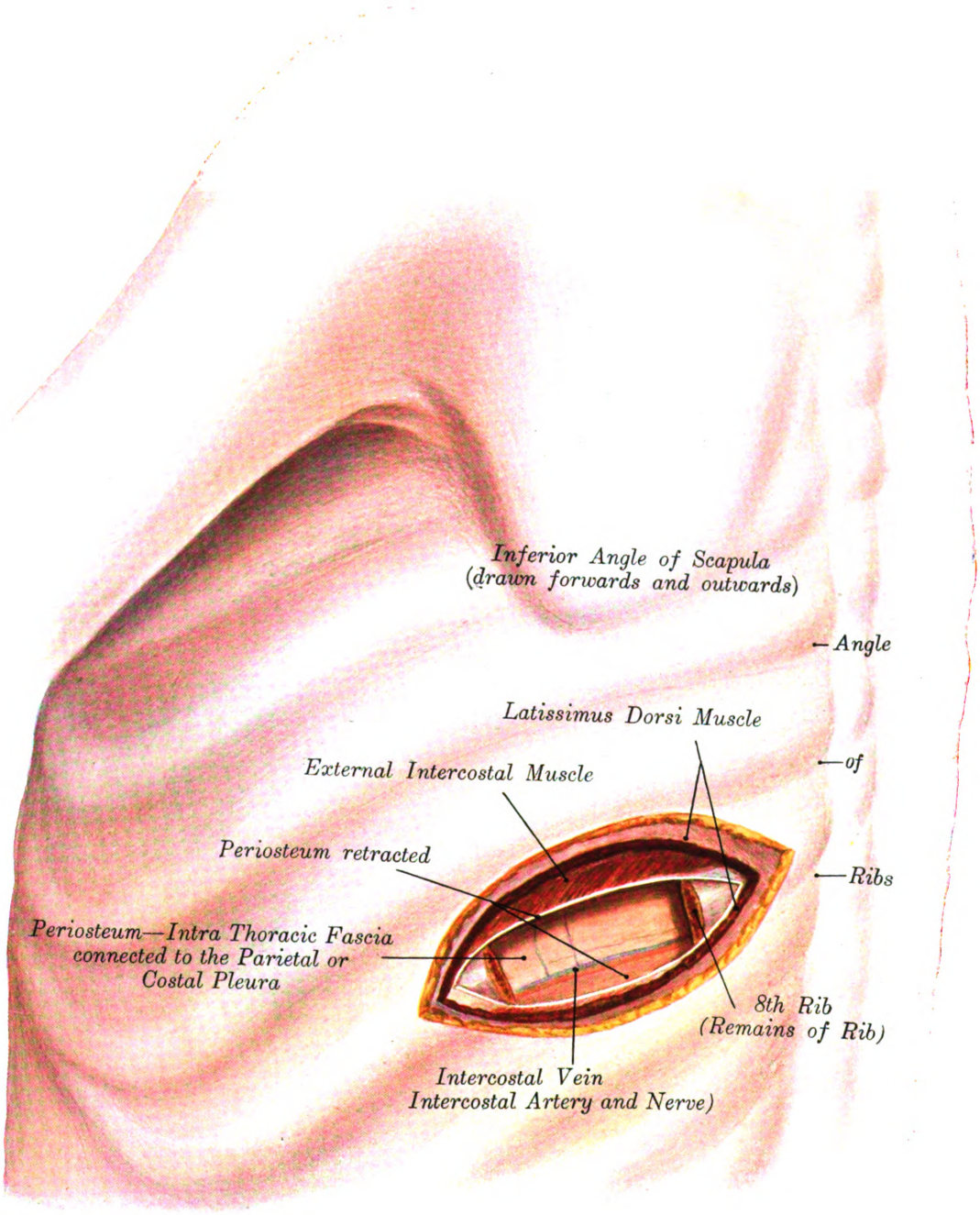

Resection of Rib.

Plate XXV.

Cellulitis of the Hand

Cellulitis of the Hand

As soon as Cellulitis has been diagnosed the affected tissues should be incised; the sooner this is carried out the more favourable will be the prognosis of the subsequent function of the hand.

When the whole finger is involved a general anæsthetic should be employed, but if only the distal Phalanges are implicated Local Anæsthesia is sufficient (*Oberst's* Anæsthesia*). *Schleich's* Infiltration Anæsthesia should never be employed in such cases because the tension in the affected tissues is thereby increased and the extension of the infection favoured. Hæmostasis is procured by *Esmarch's* Elastic Band. The hand which is invariably covered with dirt is perhaps best cleansed by means of turpentine, by scraping the thickened Epidermis prior to the use of any particular antiseptic. Any open wounds are covered with a sterile swab while the edges alone are disinfected.

Our plate depicts the operation carried out for an extensive Cellulitis which has already spread to the forearm.

Injuries of the Thumb and Little Finger are particularly dangerous, because the Synovial Sheaths of the Flexor Muscles do not terminate at the distal end of the Metacarpal bones, but extend above the Wrist and into the Forearm. Normally there is no communication between the flexor synovial sheaths of the Thumb and Little Finger, but the Septum between them is of such tenuity that the formation of pus is usually followed by perforation.

The danger of Cellulitis of the Thumb and Little Finger is explained by such secondary extension of suppuration from one finger to the other.

In typical Cellulitis of the Hand, swelling over the Transverse Carpal Ligament (Anterior Annular Ligament) is usually absent. Induration and pain on pressure on the proximal side of the Wrist indicates that the infection has extended to the Forearm.

The incision is commenced near the tip of the Thumb and Little Finger directly in the middle line and opens up each Synovial Sheath throughout its whole extent. If possible, injury to the superficial Palmar Arterial Arch should be avoided; the only nerve of practical importance is the branch of the Median to the Thenar Eminence. At the Distal or lower border of the Annular Ligament these incisions meet; if necessary, from this point of junction an incision is carried up the middle line of the Forearm, dividing all superficial ligaments. (Vide plate.)

*The base of the finger is encircled by a rubber band, the needle of a hypodermic syringe is in turn inserted from behind forward at 4 places which correspond to the 4 collateral digital nerves and the injection of 1 per cent. solution of cocaine is carried out. Loss of sensibility is complete in 5 minutes.—J. Howell Evans.

The Median Nerve (both the main trunk and chief branches) must be protected from all injury; this can, to a great extent, be done by lifting it from its position between the Flexor Muscles and the Pronator Quadratus.

The spaces between the muscles are widened by blunt instruments, the fasciæ and interosseous membrane serving as landmarks for the lines of separation.

Counter-incisions are made just above the wrist, one on the Radial and the other on the Ulnar side (great care being taken to avoid injury to the Arteries).

Drainage tubes are passed through these counter-openings, and to ensure free drainage of the deeper spaces one of these tubes is inserted deep to the Flexor Tendons.

According to the extent of the Cellulitis, so further incisions and drainage-tubes will be necessary in the Forearm and around the Elbow. Even counter-openings on the exterior aspect of the Forearm are necessary in some cases, whereas multiple superficial incisions will, in all cases, relieve any marked œdema.

The pus is allowed to drain away; cleansing of the wound cavity is not practised. When all necessary incisions have been made the Elastic Band is removed, and all bleeding points carefully secured. The Elastic Band is reapplied, loose strands of Iodoform Gauze are inserted; the arm is entirely enveloped, in a bandage loosely applied, and suspended.

As early as possible the drainage tubes are replaced by gauze-drains. After subsidence of the initial fever the divided ends of the Annular Ligament may be re-united. Fixation of the limb should not be long maintained, but passive movement of the muscles and joints should be entered upon as soon as the fever has abated and pus-formation subsided.

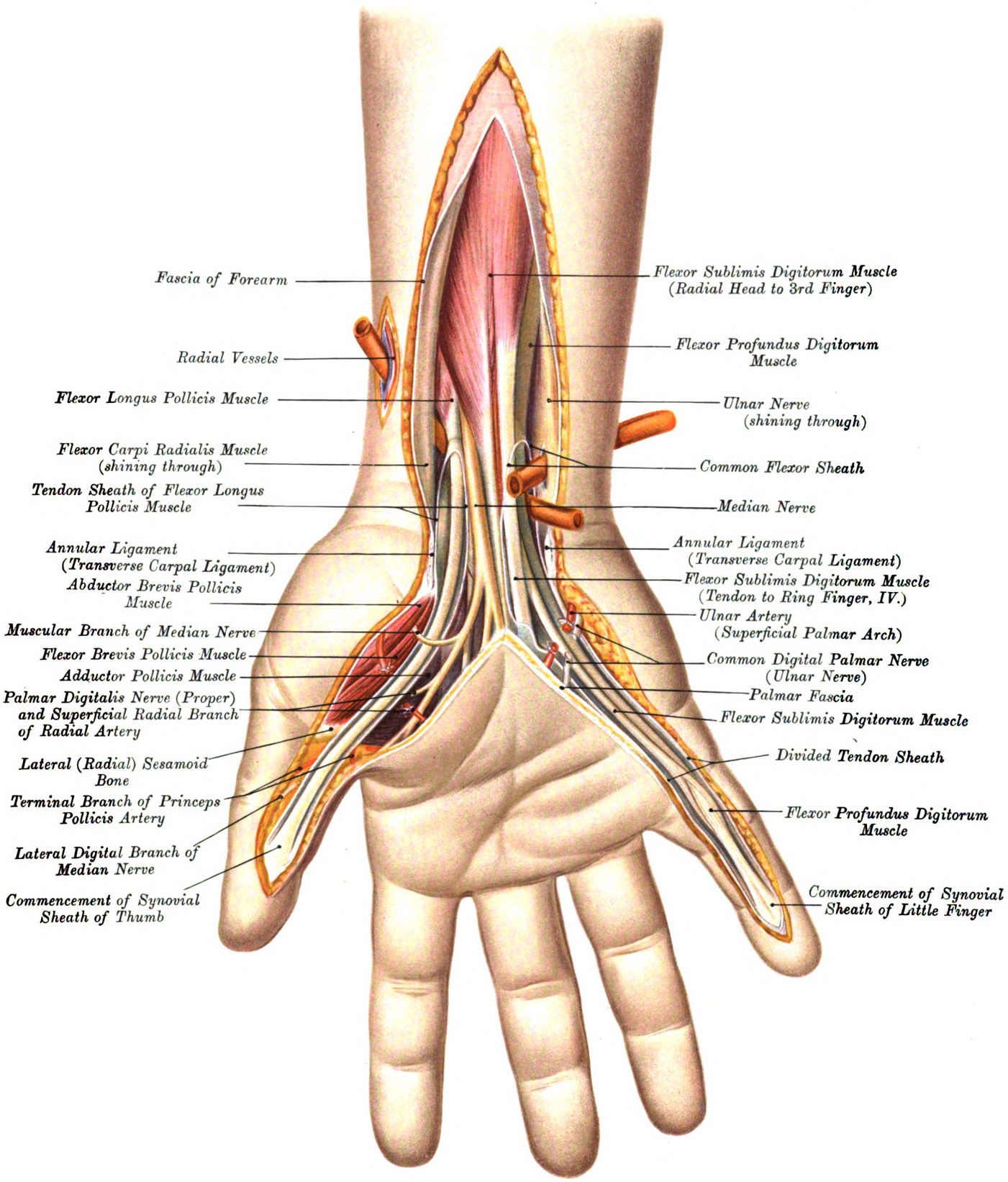

Rebman Limited, London.

Cellulitis of Hand.

Rebman Company, New York.

Plate XXVI.

Nephrectomy

Nephrectomy

STAGE I.

General Anæsthesia: Ether or Chloroform (*Roth-Dräger* Apparatus). The operation is carried out with the patient lying on the sound side, with a rounded sandbag placed under the Ilio-Costal space so that the affected side now becomes arched outwards.

Indications for the Operation: Hydronephrosis, Renal Calculus (to be ascertained by X-Rays), Extensive Injuries, Tumours (including Congenital Tumours), etc., etc.

Prior to all operations upon one of the Kidneys (except Nephropexy) firstly the presence and secondly the normal activity of the other Kidney must in every case be accurately ascertained. Cystoscopy (Cf. Instruments) followed by Catheterisation of the Ureters is necessary.

By means of Cryoscopy, which was first introduced by *Koranyi,* the concentration of the Urine and Blood is determined by the use of *Beckmann's* Freezing apparatus (Cf. Instrument). By comparison with the normal well-established figures an estimate of the function of the Kidneys can be obtained.



Freezing apparatus after Beckmann ¼ natural size.

The kidney is exposed for:—

1. Decapsulation of Kidney (*Edebohls*).
2. Nephrotomy (*Tuffier*).
3. Nephrectomy (*Simon*).
4. Nephropexy or Nephorrhaphy (*Hahn*).

In contradistinction to *Simon's* incision carried vertically downwards along the outer border of the Erector Spinæ, the oblique incision advised by *v. Bergmann* exposes more to the operator's view. It is accordingly particularly recommended for the removal of Tumours. The incision is commenced at the upper border of the last rib, which can be easily felt; the Erector Spinæ can be felt

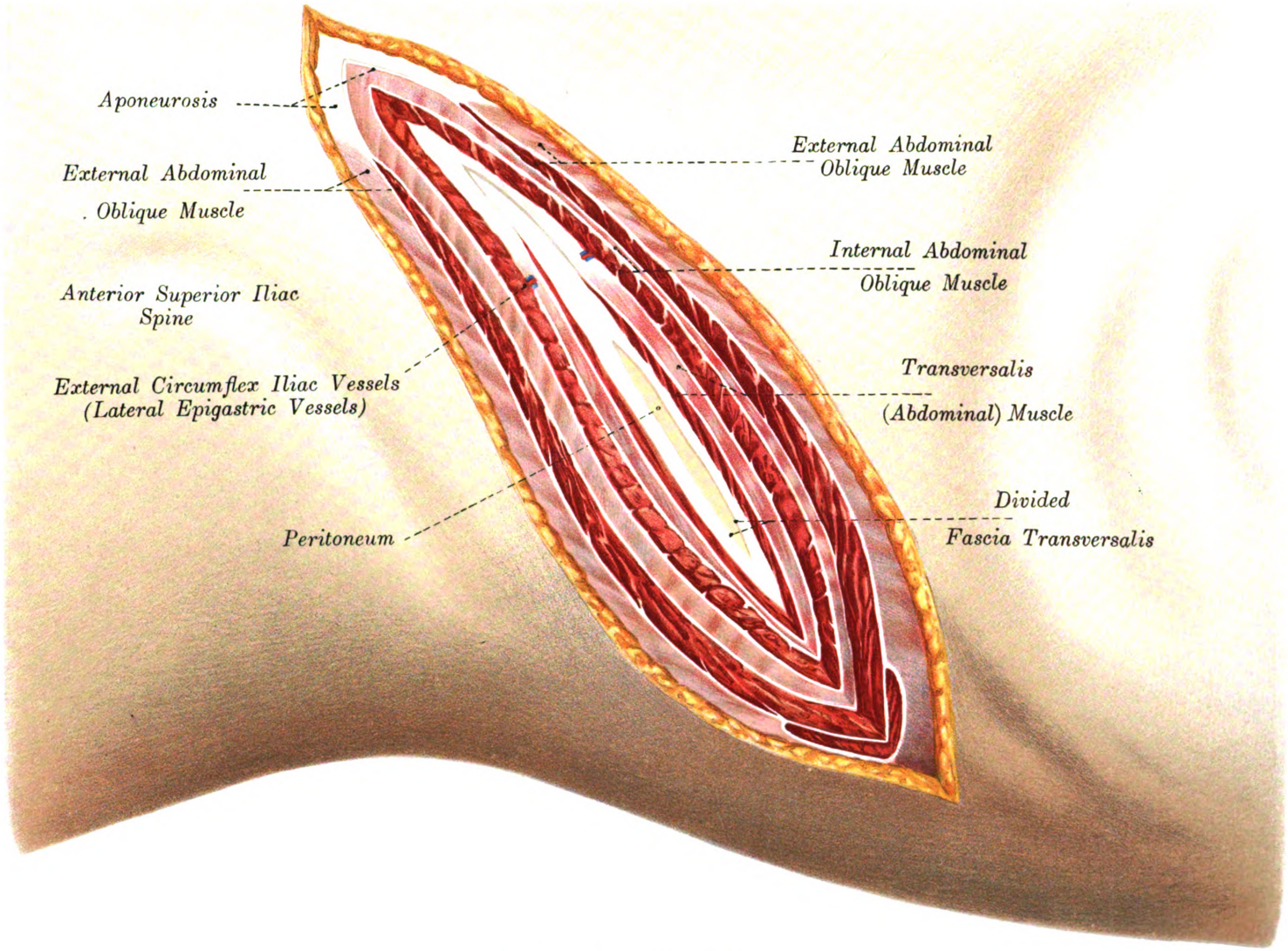

Nephrectomy (Stage I.).

Rebman Limited, London.

Rebman Company, New York.

distinctly at this spot where it is covered by the Latissimus Dorsi; this incision is directed obliquely forward as far as the midpoint of a line drawn from the Anterior Superior Iliac Spine to the Umbilicus.

The Skin and Superficial Fascia are divided; the Muscles are next divided commencing at the upper end of the incision (without injury to the larger blood-vessels: except the 12th intercostal at the upper angle of the wound) in the following order:

1. External Oblique—this muscle is aponeurotic at the inferior extremity of the incision.

2. Internal Oblique.

3. Transversalis—this is divided with great care because it is oftentimes very thin.

Owing to the very close connections of the Transversalis Fascia, Transversalis and Peritoneum, it is difficult to divide Transversalis and Fascia Transversalis without touching the Parietal Peritoneum. The incision should therefore be commenced in the upper part of the wound with extreme caution.

The External Oblique is divided throughout the whole length of the skin incision, but the deeper layers are not so extensively incised. After division of the Transversalis Muscle, the Fascia Transversalis (readily recognised by its white colour and vertical fibres) is drawn up into the wound and carefully divided; this separation is enlarged subsequently. By this precaution there is less likelihood of injury to the Peritoneum, which is separated from the Fascia Transversalis by a variable quantity of Fatty-tissue. The incision can at any stage of the operation be extended forward, if necessary, for the removal of large tumours, especially the Congenital Tumours of the Kidney.

This method is not only applicable for the exposure of the Kidney, the Supra-Renal Capsule and the Ureter, but also for Peri-nephritic, Para-nephritic Abscesses and even Retro-peritoneal Tumours. Moreover, operations can be carried out on the Aorta and its branches when the incision is made on the left side, and on the Inferior Vena Cava and its tributaries when the incision is made on the right side.

Plate XXVII.

Nephrectomy.

Nephrectomy

STAGE 2.

The Fascia Transversalis should be opened up so as to allow the admission of a hand into the space between it and the Parietal Peritoneum. The Peritoneum can hereby be carefully stripped from the posterior Abdominal Wall, so that the Quadratus Lumborum and Psoas Muscles are laid bare. The variations of the different nerves require consideration. Directly below the tip of the last rib lies the last Dorsal Nerve, closely connected with the subcostal artery (already divided).

At each successive inspiration the Peritoneum is pushed forwards; it should therefore be kept forward by a broad retractor throughout the course of the operation.

The position of the Kidney is now ascertained by palpation, when it will be necessary to pass the hand upwards in contact with the dome of the Diaphragm. By now separating the Perinephritic Capsule of Fat the Kidney—thus liberated—can be brought into the wound. Such liberation is not only difficult but is attended with injury to the Peritoneum in those cases of Malignant Tumours where the surrounding tissues have become infiltrated. Again, large Hydronephroses and Pyonephroses are difficult to free. Whenever, under such circumstances the Peritoneum shall have been torn the rent must be sutured (with catgut), the Ureter invariably remains adherent to the Peritoneum and needs dissection from out of the Subperitoneal Fat. The Spermatic Vessels as a rule do not come into view when the Subperitoneal Fat is separated from the Ureter (our plate illustrates the unusual condition). These vessels should be held by a broad retractor while the Ureter is dissected out to a greater extent.

The further technique of the operation will vary considerably.

No definite opinion can yet be formed of the value of "Decapsulation," *i.e.,* stripping the Capsule proper off the Kidney, as recommended—by *Edebohls*—for Nephritis. This procedure is carried out by splitting the True Capsule along the Convex or Outer border of the Kidney; when each half shall have been completely peeled off the Kidney, it is removed. *Tuffier's* procedure in Nephrotomy is an incision along the Convexity of the Kidney, which may be carried through the Kidney substance into the Pelvis of the Kidney.

Compression of the Renal Vessels, which is necessary, is carried out by two fingers of an assistant pressing the hilum of the kidney against the inner surface of the last rib.

On section, the Renal Substance and Pelvis can be well examined. After removal of Calculi a retrograde Catheterization of the Ureter should not be omitted. The divided renal tissue is united by deep catgut sutures passed through the renal parenchyma.

For Extirpation of the Kidney—Nephrectomy—the hilum must be well exposed. The vessels are ligatured separately, considerable attention being directed to those which pass to the lower pole of the kidney. The Ureter is dissected out as low down as possible (especially in malignancy), ligatured and cut across. No urine can subsequently pass from the bladder into the wound; this is an occurrence which might otherwise take place when the patient coughs.

If each vessel cannot be ligatured separately, transfixion should be employed, followed by a ligature en masse, *i.e.,* an encircling ligature of stout silk.

It is only reasonable that in Tuberculosis and Malignant Disease the Perinephritic fat and every suspicious-looking tissue should be removed.

Excision of the Suprarenal Glands can also be accomplished through this route, in cases of *Addison's* Disease (*Harda* and *Oestreich*).

Simon's incision is suitable for Nephropexy.

This operation, which is, nowadays, less frequently performed because the trouble may be done away with by Food and Rest Cures, is most satisfactorily carried out by the method adopted by *Guyon,* namely, suturing the kidney by deep silk sutures to the last rib.

The operation completed, a gauze drain is inserted and brought out at the upper angle of the wound. Muscles and Skin are brought together, except at the upper angle, by means of deep catgut and superficial silk sutures.

During the subsequent treatment Diuresis should be stimulated by our usual methods.

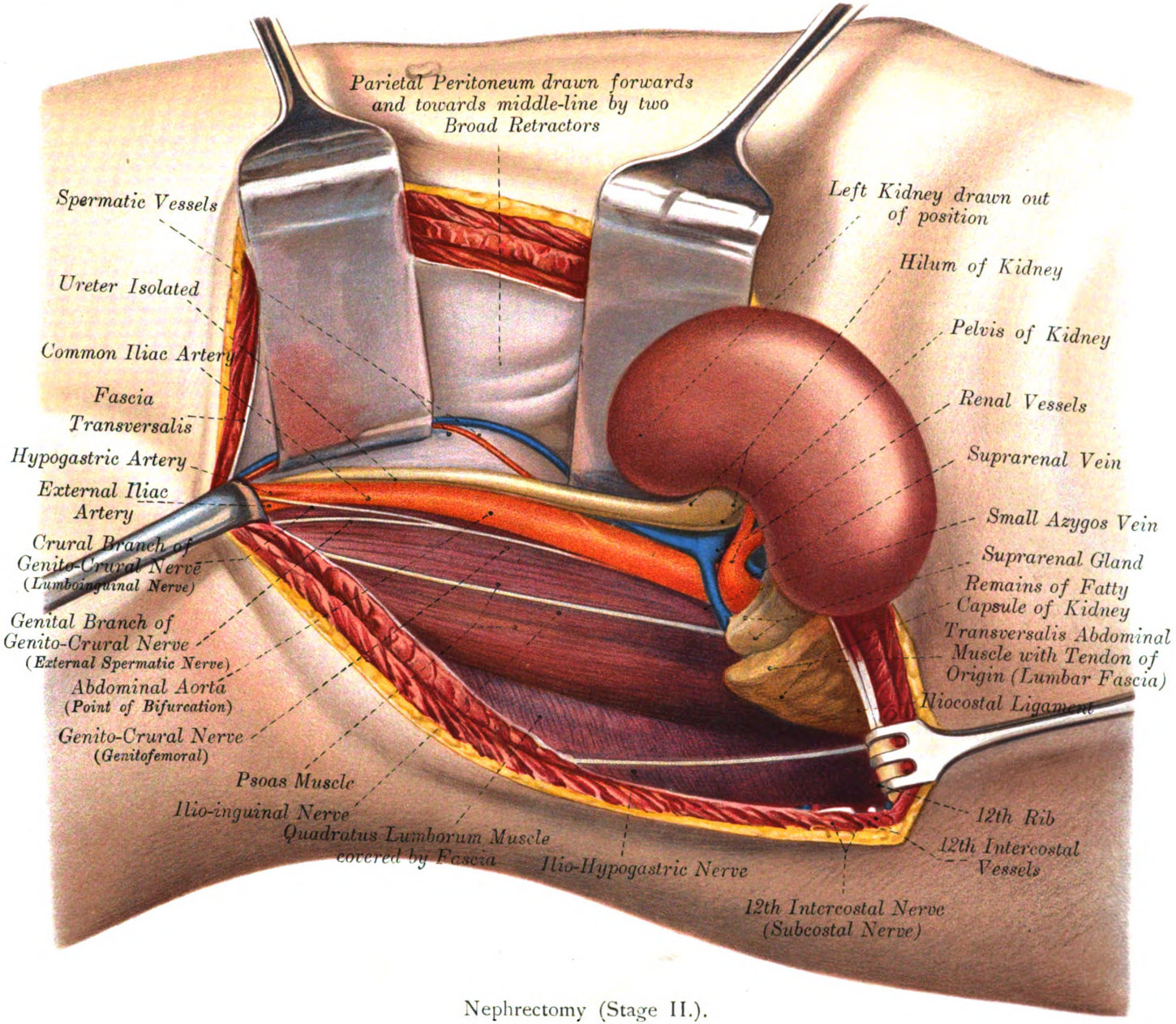

Nephrectomy (Stage II.).

Plate XXVIII.

Femoral Hernia

Femoral Hernia

STAGE I.

Anæsthesia: General.
Anæsthesia: Local. (*Schleich's* Method of Infiltration Anæsthesia.)
Anæsthesia: Lumbar. (*Tuffier's* Method.)

Femoral Hernia differs from Inguinal Hernia by appearing at the upper part of the Fossa Ovalis (Saphenous Opening) after forcing its passage by pushing in front of it a funnel-shaped process of the Fascia Transversalis.

The more frequent occurrence of Femoral Hernia in women is explained, according to us, not only by the greater width of the Pelvis, but particularly because the Abdominal pressure is in the female directed towards the Crural Ring, as practically no Inguinal Canal exists. The course of a Femoral Hernia passes along the inner side of the External Iliac Vein to the Fossa Ovalis (Saphenous Opening).

By the protruding Hernia a large lymphatic gland (Gland of *Cloquet*) is pushed downwards or aside. The neck of the Sac is bounded internally by *Gimbernat's* Ligament, externally by the Femoral Vein.

As a rule the Hernia is small and does not extend beyond the Vessels shown in the figure (the External Pudic and Superficial Epigastric Veins).

In front of the Hernial sac many lymphatic glands, varying in size, are found in the fatty-tissue. At the fundus of the sac, which is oftentimes a large fatty mass, one or more small cysts are seen.

The Contents of the Sac may be: Omentum, Small Intestine, Vermiform Appendix, Bladder, Ovary, Fallopian Tube, Hernia of the Intestinal Wall (*Richter's*), Hernia of an Intestinal Diverticulum (*Littre*), in which only the convex side of the Intestine which is opposite the Mesentery forms the contents of the sac.

Owing to the very narrow Hernial Orifice the contents of this Hernial sac often become gangrenous early. In such cases excision of the Gangrenous portion is imperative.

Before opening, the Hernial sac should be carefully isolated on all sides as far as the Inner Crural Ring, with particular precautions not to injure the Femoral Vein, which is an external relation. Any small vessels are ligatured and divided. The anterior portion of the sac is held upwards by means of a tenaculum-forceps and carefully opened. The opening is enlarged in the vertical direction and the cut

edges of the sac are on all sides clamped by forceps. The contents of the sac, if healthy, are returned. Any omentum, which is generally strangulated, atrophied or adherent, is cut off even when normal. The ligature is applied with great care (as in Inguinal Hernia) because subsequent hæmorrhage from the Omental Stump may prove fatal.

If the sac contains any Intestine the surgeon must be at great care to ascertain whether this Intestine is healthy, particularly at the point constricted. For this purpose on no account should the gut be dragged through the narrow Hernial Orifice, but sufficient space should be obtained by splitting the Hernial Opening from without inwards (open Herniotomy). Now the Intestine can be drawn outside not only with convenience but without any risk of rupture.

Again there is by this open method no risk of Injury to the Spermatic cord which in the Male passes over the pedicle of the sac or to the Deep Epigastric Vessels as they run in a lateral and superior relation. Moreover, injury to the Obturator Artery, which is frequently a branch of the Deep Epigastric Artery running inwards across the pedicle of the Hernial Sac (*Hesselbach's* Corona Mortis), is of no great consequence because the artery can be secured before division.

Any Gangrenous condition of the Intestine is recognised by a greyish-black discoloured patch, dull surface and absence of lustre; Peristaltic movements which are induced in healthy intestine by the application of normal saline are entirely absent. On digital compression the portion of the gut so affected is not blanched as is the case in normal intestine. Such portions of the intestine must be excised (Vide Resection of Intestine).

Any portion of the Intestine which presents a brown or bluish-red colour is suspicious of impending gangrene and demands observation for a few minutes. Such portions frequently recover with marked rapidity when freed from the constriction around the neck of the sac. These may be returned, but should be surrounded by Iodoform gauze in case Gangrene should supervene and Perforation result. The Iodoform gauze protects from general Peritonitic Infection. A radical cure can in these cases only be carried out at a later date.

In those cases in which the contents of the Hernial sac can be returned without any drainage or packing, the sac is twisted on its longitudinal axis and close below *Poupart's* Ligature is transfixed with two silk ligatures, which are firmly secured.

The portion, distal to the ligatures, is cut off and the secured stump returned into the Abdomen through the Internal Crural Ring.

Plate XXIX.

Femoral Hernia

Femoral Hernia

STAGE 2.

Some Surgeons rest contented with simple ligature of the Sac, and do not attempt any radical cure, inasmuch as they do not happen to have seen many instances of recurrence in Femoral Herniæ. We, on the other hand, advocate in every case a radical cure which needs modification according to the size of the Internal Crural Ring. If this opening be small, *Poupart's* ligament is stitched to the Fascia covering the Pectineus muscle by 2 or 3 interrupted silk-sutures; the external suture must be close to the Femoral Vein, which should be well exposed in every case. (Cf. Stage 1.)

Roux closes a small Hernial Orifice by means of a steel staple (⌈⌉) which is hammered through *Poupart's* ligament into the Horizontal Ramus of the Pubis (cf. Plate 28). But when the orifice is larger other methods must be adopted.

Bassini's method consists in uniting *Poupart's* Ligament to the Fascia covering the Pectineus, and this again with the Falciform Process of the Fossa Ovalis (Saphenous Opening); unfortunately, this sometimes leads to a compression of the Femoral Vein.

Fabricius proposed a separation of *Poupart's* Ligament from the Spine of the Pubis, thus rendering suturing to the Fascia more easy. We avoid any separation of *Poupart's* Ligament at its insertion, because such a process would only widen the Inguinal Canal, and favour Inguinal Hernia (*Gersuny*).

The soundest method is undoubtedly to cut a small flap out of the External Oblique of such a size as will extend from the Spine of the Pubis to the inner border of the Femoral Vein (Plate 29). This is reflected and sutured to the Fascia covering the Pectineus (silk-sutures).

In very large openings the radical cure can be carried out by any of the above methods after the gap has been filled in with an osteo-periostal flap from the Symphysis Pubis (*Trendelenburg*), with decalcified bone, paraffin plates, or wire netting.

The skin is sutured after absolute hæmostasis. The patient must remain in bed for 3 or 4 weeks.

Trusses are unnecessary after a radical cure.

Our plates give also the necessary illustrations for the *Alexander*-and-*Adams* Operation.

Plate XXX.

Appendicitis

Appendicitis

STAGE I.

Anæsthesia General: Anæsthesia, Lumbar. (*Tuffier's* Method.)

The three most commonly-performed operations for Appendicitis are:—

1. The simple incision of a Peri- or Paratyphlitic Abscess.
2. The Immediate operation, *i.e.,* removal of the Appendix in every case during the Acute Inflammatory Stage, even during the first 48 hours after onset.

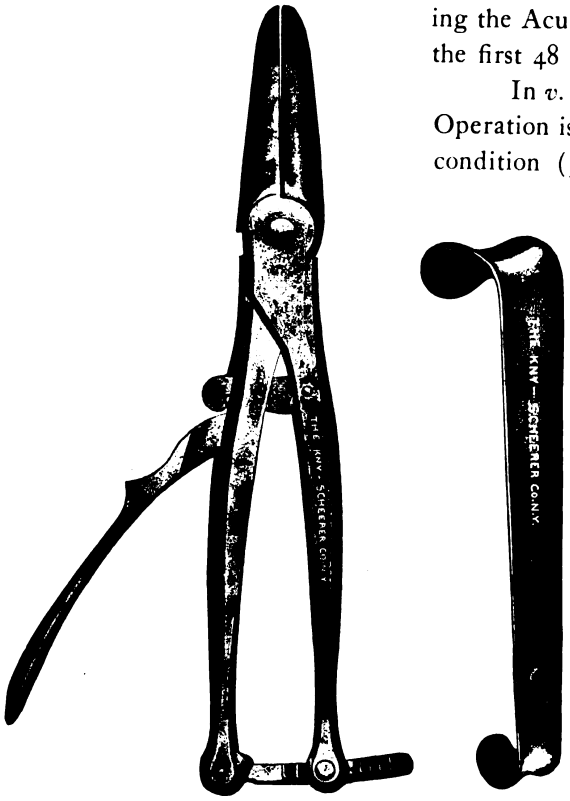

In *v. Bergmann's* practice the Immediate Operation is only undertaken when a very grave condition (perforation, gangrene) is indicated by high temperature, general malaise, jaundice, regurgitation and vomiting. The operation is by no means easy, but is strongly to be recommended on account of the good results obtained, inasmuch as the risk to the patient is increased by expectant treatment. Many cases will recover without operative measures, but in others General Peritonitis will supervene; in these conditions, operation would come too late.

3. Operation during the period of Quiescence and in the absence of symptoms of inflammation.

According to *Roux,* this operation should be performed on every person who has ever had an attack. According to *Kocher* the operation should be carried out on those persons who have had one severe attack or several recurrent minor attacks

which evidence a pathological condition of the appendix (torsion, adhesions, stercoliths, cicatrices, stenoses).

This operation is generally simple.

Incision: We prefer in every case the oblique incision along the outer border of the Rectus Abdominis.

This incision is commenced 3 cm. (1.18 inch) above and internal to the Anterior Superior Spine of the Ilium, and is extended downwards and inwards parallel to *Poupart's* Ligament.

McBurney's point (midway between the Umbilicus and Anterior-Superior Iliac Spine) at which the Appendix is usually discovered, is traversed by this incision.

For Abscess the incision should be very long, extending upwards to the Costal Margin and downwards towards the Symphysis. For an Immediate Operation an incision 8 to 10 cm. (3 to 4 ins.) long is sufficient.

For the Operation during the quiescent period very small incisions (buttonhole incisions) are sufficient. But if the Appendix is very adherent, or in an abnormal position, then, even in this operation, the incision must be enlarged as may be necessary.

Sonnenberg gets his assistant to draw the skin towards the Umbilicus while the incision is being made. By this act the scar comes to lie just above the Anterior-Superior Iliac Spine (avoiding an Abdominal Hernia).

When the Skin and Superficial Fascia have been incised the External Oblique (which is in this situation becoming Aponeurotic) and its Aponeurosis are divided with a knife. In the operation during the quiescent period the Internal Oblique and Transversalis Muscles are divided by separating their fibres with a blunt instrument such as a closed scissors.

By suitable hooks (*Roux's* Instruments) the divided muscles can be separated so as to give plenty of room. In the other operations these muscles are cut through in the line of the skin-incision. After complete hæmostasis (the Epigastric Vessels and their branches in the lower part of the wound are particularly liable to injury), the Fascia Transversalis is drawn forwards and incised, further division being carried out on a director.

In inflammatory conditions the Muscles, Fasciæ and Peritoneum evidence œdematous infiltration.

Great care is necessary in the operative technique. The Peritoneum will retract under these conditions unless, as soon as opened, its edges are seized with Forceps; it is at first, therefore, only incised to the extent of 2 to 3 cm. (an inch).

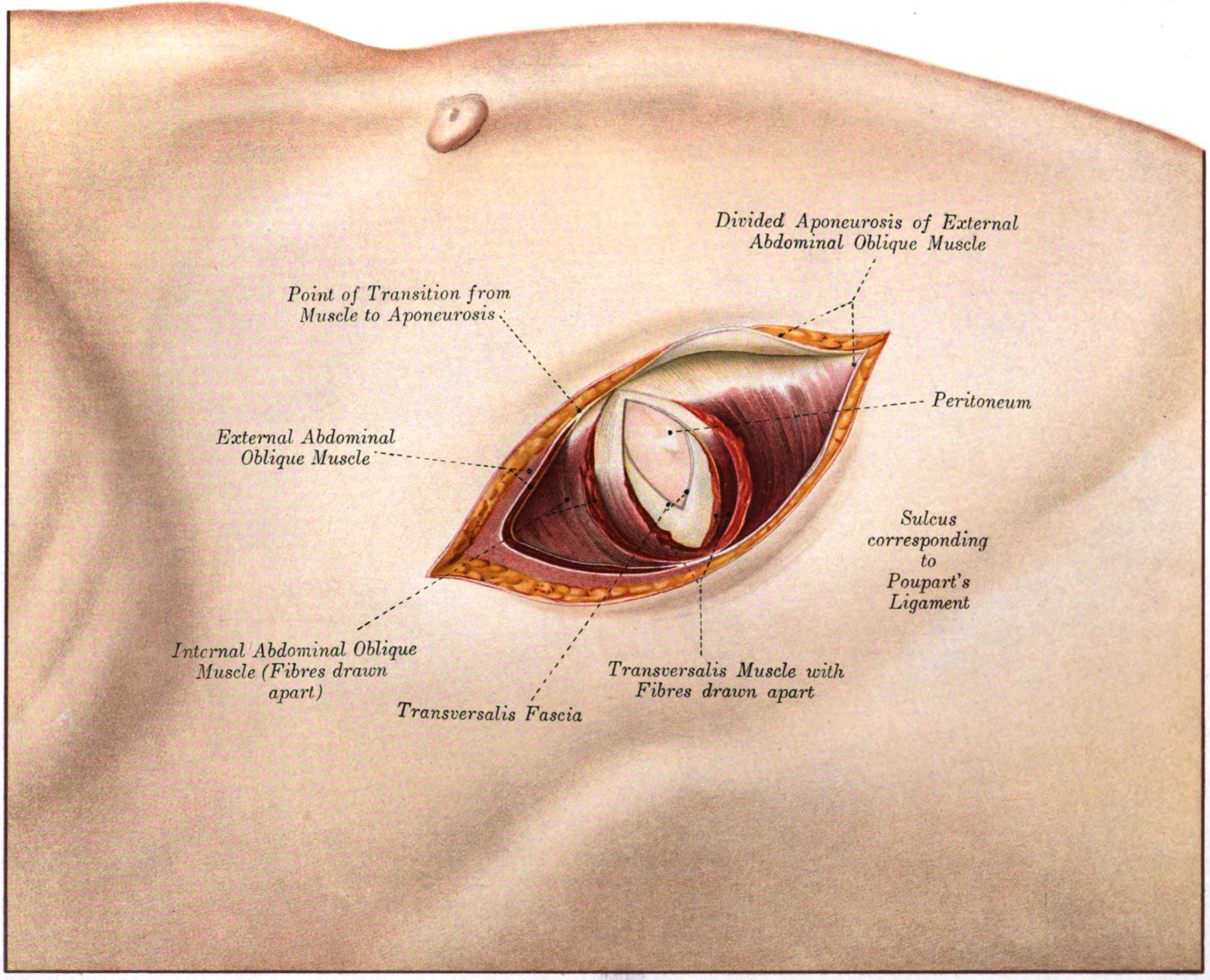

Appendicitis (Stage I.).

Rebman Limited, London.

Rebman Company, New York.

Plate XXXI.

Appendicitis

Appendicitis

STAGE 2.

Before the Peritoneal Cavity is opened, the skin in the neighbourhood of the wound is covered with sterilised compresses. When the abscess is encapsuled it is generally opened directly upon cutting through the Peritoneum; however, in some cases the abscess is formed more Anteriorly above the Bladder or more posteriorly in the region of the Kidney, or in the true pelvis, according to the various positions which the Appendix may occupy, and the lines of extension of pus-formation. Multiple abscesses, *e.g.,* even in the Left Iliac Region, may be present. All these foci of pus must be freely drained; if encapsuled they should be loosely packed.

If the Abscess is not separated definitely from the Abdominal Cavity, gauze packing must be employed to completely shut off the wound-secretions.

Abscesses in the Pouch of *Douglas* are drained towards the Rectum (in males and virgins), or towards the Vagina (in women).

The Appendix should never be sought for in the Abscess Cavity. At a later date (2-3 weeks) the removal of the Appendix is always justifiable because the subsequent pathological changes in the Appendix and the surrounding parts (Periappendicitis-Perityphlitis) frequently give rise to secondary disturbances.

Always work with dry fingers, and avoid irrigations of the wound cavity.

In the Immediate Operation as here depicted, there is usually a small quantity of free fluid found when the Peritoneum is opened.

In all cases insert the fingers and endeavour to palpate the Cæcum and Appendix; the Appendix arises from the angle formed by the junction of the Ileum and Cæcum and is found by tracing the Anterior band of Longitudinal muscle. If the Omentum has formed a covering, after a double ligature the Omentum may be cut off. Protruding coils of intestine are held back by Iodoform-Gauze.

In the majority of cases, there is no great difficulty in bringing the Cæcum and Appendix through the Peritoneal opening and completing the operation outside the Abdomen.

As the Appendix may be of considerable length and extend into the true Pelvis, to the region of the Liver, to lie above the Bladder or to point to the Left, the operative procedure may be rendered more complex.

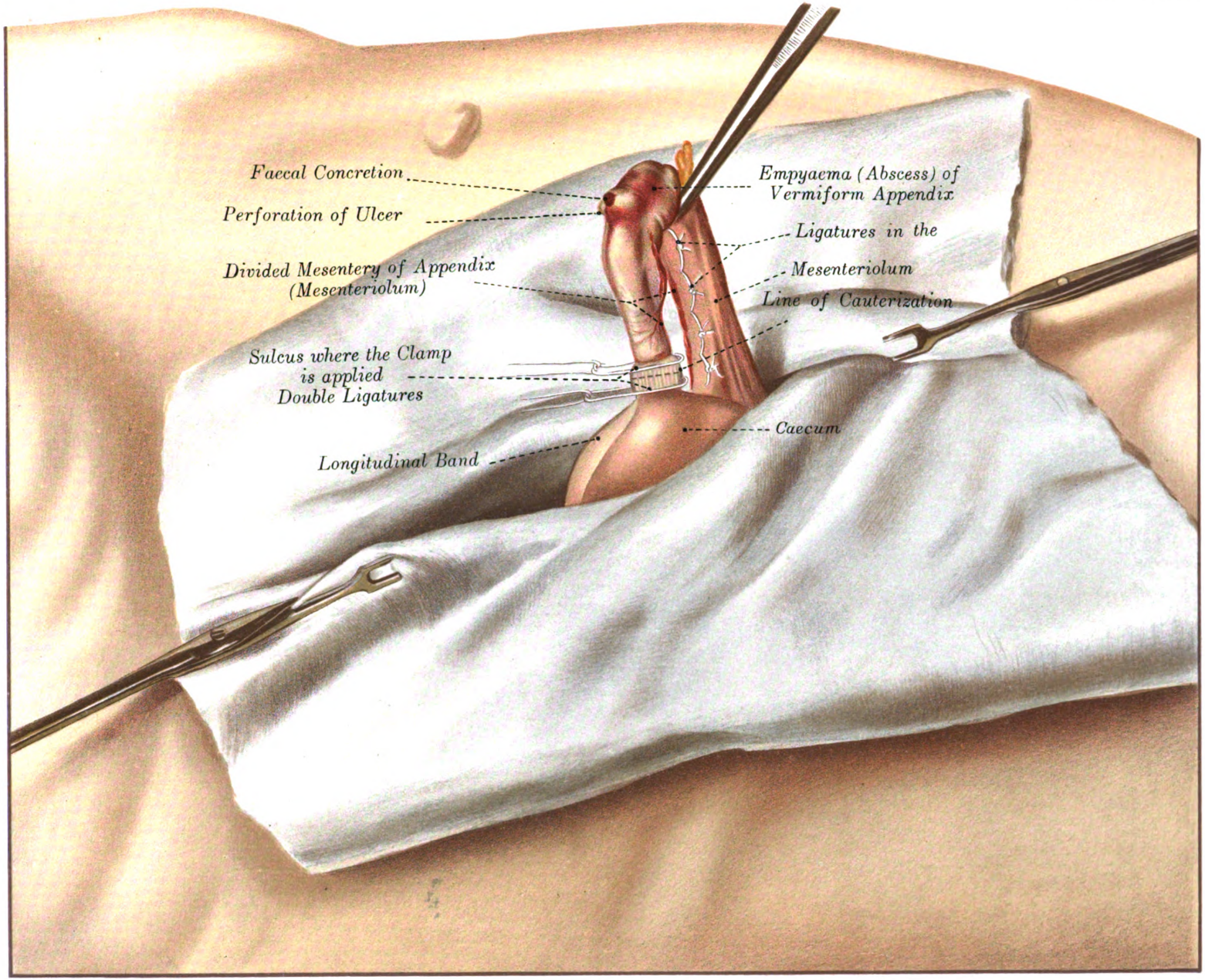

Rebman Limited, London.

Appendicitis (Stage II.).

Rebman Company, New York.

All Appendicular Adhesions must be broken down, and bands ligatured. An incision of 10 cm. (4 inches) in length, if too small, must be enlarged in any direction considered necessary (upwards, downwards, or towards the middle line T-shaped incision).

In the course of the Immediate Operation many difficulties arise, owing to the œdema of the Appendix and its Mesentery (Mesenteriolum), with marked injection of the Blood and Lymph vessels. The Appendix may be acutely inflamed when it is stiff, erectile and several times its normal size, or at the tip there is a large pus-cavity (Empyæma). During the first few days an ulcer may be found to have been perforated by a Stercolith. Even a few hours after the clinical symptoms appeared we have found Complete Gangrene of the Appendix.*

During the quiescent period all such acute inflammatory signs are absent, but pouches and cicatrices occur which render separation of the Appendix no easy task. When the Appendix is soldered to the Cæcum and completely embedded in these pouches, *Schlange* splits the Appendix longitudinally, curettes away the mucous membrane, and reunites the split edges.

In both operations the Mesenteriolum (Mesentery of the Appendix) is ligatured with catgut, and in this ligature is included the Artery to the Appendix. The Appendix is compressed by a *Doyen's* clamp (cf. Plate) so that the muscular and mucous coats are pushed aside, while the serous layer alone remains; around the clamp-furrow 2 silk ligatures are passed at a little distance apart. The Serous layer is now divided between the 2 ligatures with a Thermocautery.

If *Doyen's* clamp is not at hand, simple division between the two ligatures will suffice.

*Lancet November 29, 1902.

Plate XXXII.

Appendicitis

Appendicitis

STAGE 3.

In only a few cases of Peri- or Paratyphlitic Abscesses can the Appendix be secured with sufficient ease to enable the operator to ligature its base after having previously ligatured its Mesentery (Mesenteriolum). When the ligatured-stump has been cauterised a drain is placed on it. In all other operations the stump is dealt with in a special way.

In the Immediate Operation, the tissues may be so œdematous and inflamed that the operator must remain content with ligature and drain. If the Appendix be merely ligatured there is a great liability to Fæcal Fistula. As a general rule the stump can be dealt with in the most desirable manner in the Immediate Operation as well as in the operation during the quiescent period.

The method of greatest simplicity is to cauterise the protruding mucous membrane of the ligatured stump, then to invaginate the entire stump by means of a number of *Lembert's* sutures (Sero-Muscular) passed directly over it through both sides. A single row of sutures will suffice and avoid a Stenosis which might otherwise arise from excessive folding-in of the Cæcum.

The stitches farthest away from the cauterised stump are passed first; their ends are retained long, so that an assistant may employ them as traction and fixation sutures; by this means a more rapid and easy technique is obtained for the almost automatic invagination of the stump, which is observed as the sutures approach the stump and the final sutures are being passed directly over it to render the process complete.

Kocher passes a continuous serous suture over the stump.

By purse-string sutures passing ½ cm. (¼ inch) away from the stump and carried through the wall of the Cæcum an efficient invagination is procurable. Other surgeons make a Cuff-flap from the serous layer of the appendix; the appendix is then circumcised ½ cm. (¼ inch) from its base, so that when the mucous and muscular layers have been brought together the serous cuff is closed over them. When the appendix has a broad Mesenteriolum in a healthy condition, this may be reflected and fixed over the row of invagination-sutures.

In cases of Abscess the wound is left open and well drained.

During the Immediate Operation a gauze-drain is placed on the stump if the tissues are disintegrating.

In a similar manner every portion of Intestine covered with fibrin or pus is isolated. Under such conditions the Peritoneum can be closed only in part (the best method is to use button-sutures) ; the soft tissues, moreover, are only partly united, or, according to *Kocher,* united at a subsequent period. As soon as the condition of the patient permits, the drain is removed, often on the 2nd or 3rd day, hereby allowing a certain degree of primary-union to take place. The earlier the wound unites the firmer the scar and a consequent important diminution in the risk of Ventral Hernia. Untoward results may follow the too early removal of the packing. The most favourable circumstances attend the operation during the quiescent period, inasmuch as in the majority of such cases the wound may be completely closed up.

It is well to unite Peritoneum and Fascia Transversalis with a continuous silk-suture; Transversalis and Internal Oblique are brought together by ***button-hole sutures;*** the External Oblique and its Aponeurosis are stitched together with a continuous suture. Lastly, the overlying skin is united by silk sutures. (It is also justifiable to close the Abdomen by 2 or 3 sutures.)

The more exact and firm the suture, and the more rapid the wound-repair, the less is the chance of a Hernia.

But whenever secondary union has not taken place during the first weeks, where scar-tissue replaces the granulations in the wound-cavity, this scar-tissue should be cut out, the Peritoneum should be pared, and as far as possible normal tissue brought in apposition. We consider it advisable to apply an occlusive-dressing, to confine the patient to bed for three or four weeks, and to recommend the wearing of a bandage for a year, and thereby considerably assist the formation of a firm scar.

Even when primary union occurs, consecutive-hernia may follow, owing to the impossibility of avoiding injury to abnormal nerves in the progress of the operation.

Experience gives evidence of the favourable results of the Immediate Operation (98% cures, *Bernays*). When the patient is seen by the surgeon within the first few days this course can be strongly recommended. If, however, the attack is subsiding at the time of consultation, we await the disappearance of all inflammatory signs, preferably several weeks prior to operation. Thus the operation is performed during the period of quiescence when the prognosis is most favourable.

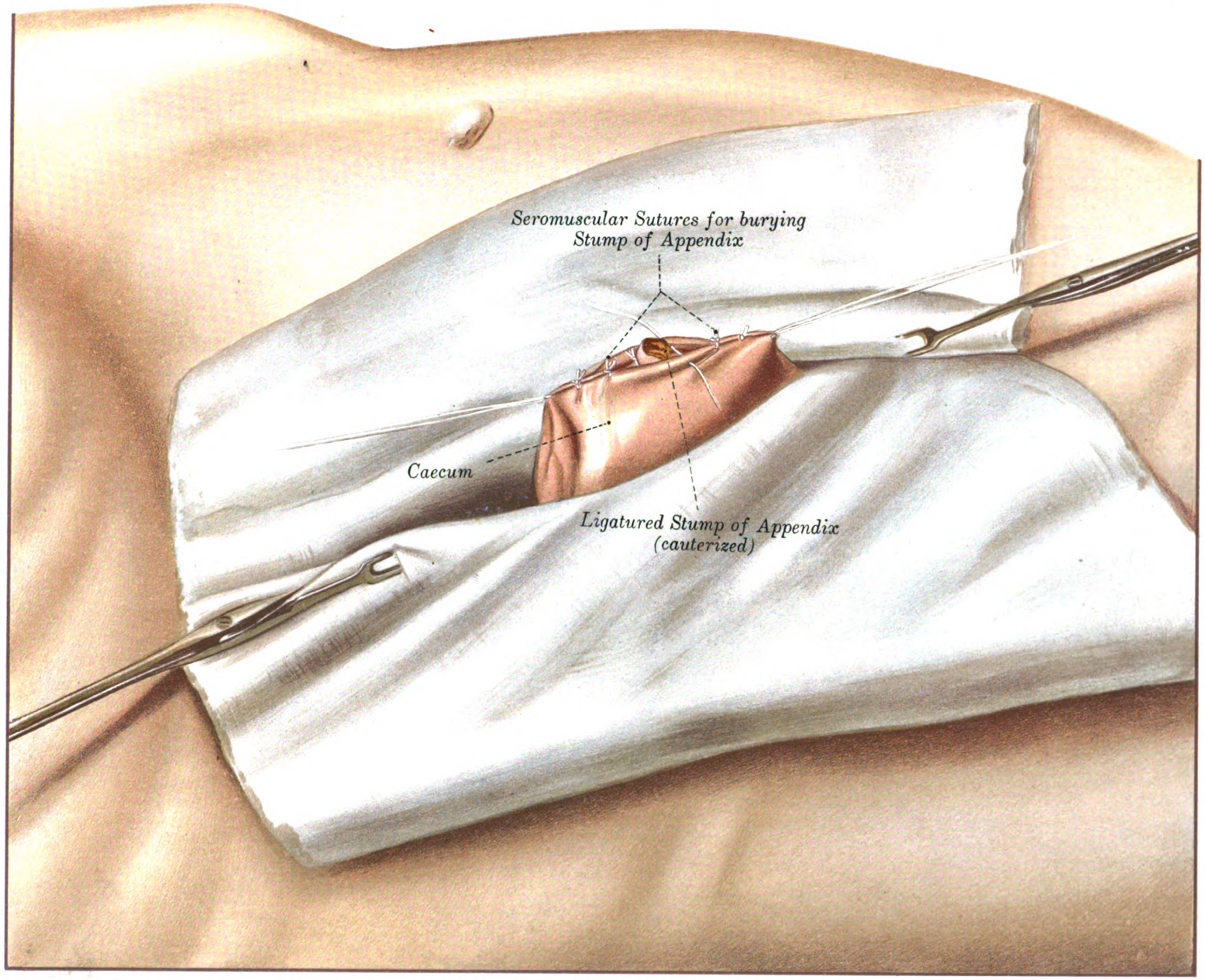

Rebman Limited, London.

Appendicitis (Stage III).

Rebman Company, New York.

Plate XXXIII.

Transpleural or Perpleural Operation, or Transthoracic Laparotomy.

(*Kocher.*)

Transpleural or Perpleural Operation, or Transthoracic Laparotomy

(*Kocher.*)

The object of this Operation is to gain access to the Abdominal Cavity through the Pleura and Diaphragm, *i.e.,* from above.

Indications: Subphrenic Abscess, Abscess and Echinococci in Liver or Spleen.

Anæsthesia: Chloroform-Ether (*Roth-Dräger*): In cases of collapse, Infiltration Anæsthesia (*Schleich's*).

Before commencing the operation, at the point of greatest dullness and most marked tenderness to pressure an exploratory puncture is made with a hollow needle and syringe. We are hereby informed of the position and nature of the fluid collection; with such information the operation may be commenced without withdrawal of the needle, which now serves as a guide.

The patient lies on his healthy side. An incision 15 cm. (6 inches) long (the midpoint of which corresponds to the Mid-Axillary line) is carried obliquely downwards and forwards in the axis of a rib (8th, 9th or 10th; in our figure it is the 10th).

The incision is carried directly on to bone as in the operation for resection of a rib. In the Figure the Latissimus Dorsi has been cut at the upper angle of the wound.

When the rib has been stripped of its periosteum without injury to the artery, a piece 8 cm. (3 inches) is resected. Through the same incision with due precaution to the soft parts the next rib (11th) is similarly treated. After ligature of the 10th Intercostal Artery the muscles of the 10th Intercostal Space are cut away, so that a large area of Costal Pleura is laid bare. In the majority of cases the lower part of the Pleural Cavity is found obliterated; the Costal Pleura is adherent to the Diaphragmatic Pleura, which is bulged upwards, by the underlying Abscess. The Parietal Pleura takes no part, therefore, in respiratory movements; but if respiratory movements of the Parietal Pleura occur, the Costal Pleura must be sutured to the Diaphragmatic Pleura by means of a circular suture, which includes the underlying Diaphragm; within the limits of this suture the next incision should be made. If the sutures fail to hold, Iodoform-gauze is packed around the future Diaphragmatic opening, to prevent any infection of the Pleural Cavity.

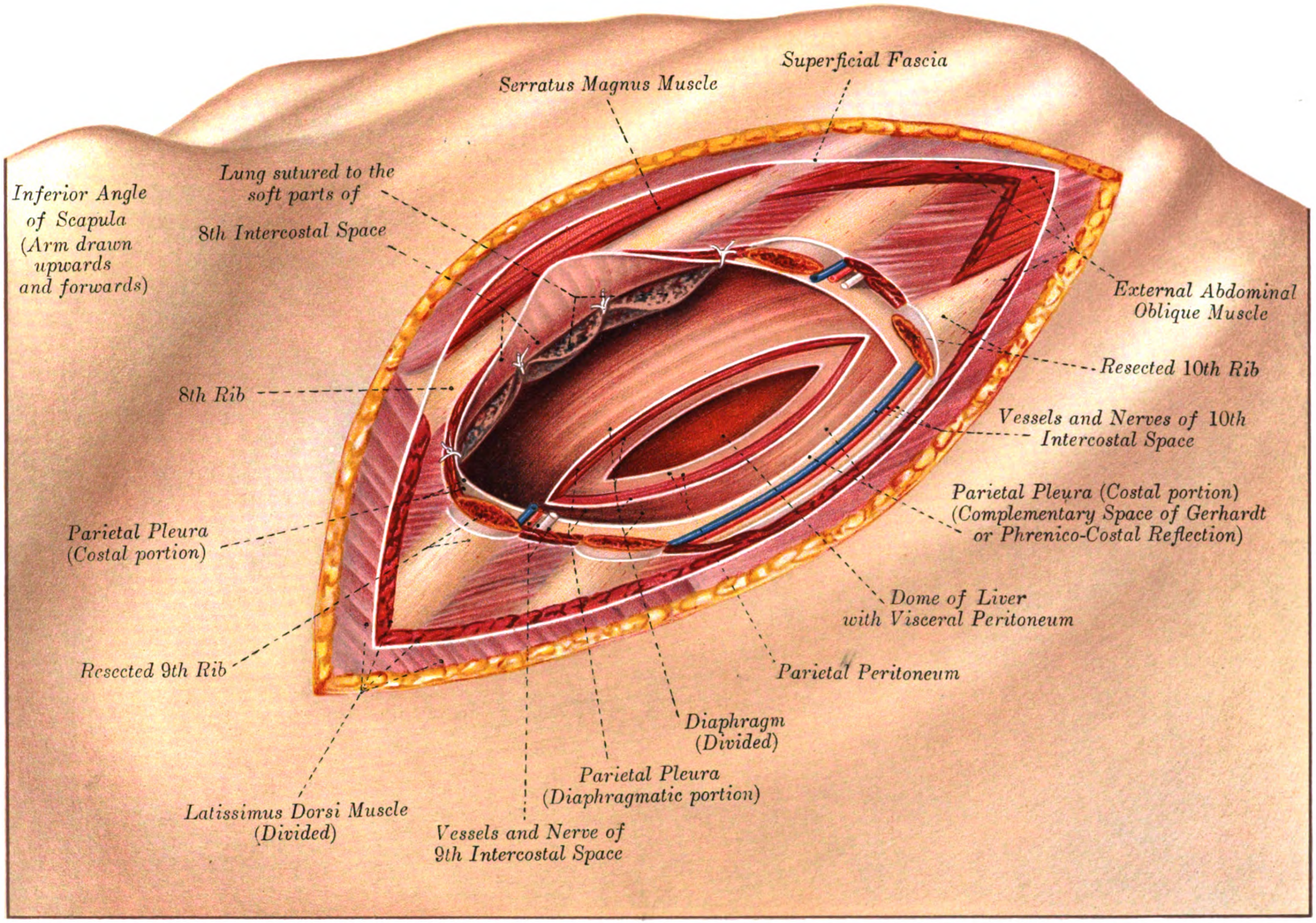

Transpleural Operation.

Rebman Limited, London.

Rebman Company, New York.

The elaboration of the operation by two stages to ensure occlusive-adhesions is often rendered quite impossible by the wretched state of the patient. When there occurs, as is occasionally the case, an encapsuled pleural exudation, the Costal Pleura may be opened straightway without any risk of Pneumo-thorax. When this encapsulation is absent (as in the figure) Pneumo-thorax is produced upon opening the Costal Pleura. Severe shock hereupon results, because the other lung is overtasked. The non-encapsuled exudation must in all cases be drained. Perhaps the simplest procedure is to bring the collapsed lung (with blunt forceps), into the wound and suture (silk) it to the soft parts of the Intercostal Space. (Pneumo-pexy. *Bayer.*) We have employed this method with repeated success. This course can be adopted for the removal of Foreign Bodies, for Abscess, for Echinococcus Cysts of the Lung, and for Tumours (all of which are usually encapsuled) without having recourse to complicated forms of apparatus which have been invented for the avoidance of Pneumo-thorax (*Sauerbruch* Chamber, *Brauer-Petersen's* Apparatus). When fixed in the way advocated above, the Lung cannot retract and may even become inflated so that Shock is much lessened. Iodoform gauze is employed to secure a more perfect closure of the Pleural Cavity to the outside. The incision is carried through Diaphragmatic Pleura, Diaphragm and Parietal Peritoneum which is forthwith stitched to the Visceral Peritoneum (on the right side, upper surface of Liver; on the left side, Liver, Spleen, or Hollow Viscera). Not until this technique has been completed is the Hepatic, Splenic Abscess or Hydatid Cyst opened. Gauze is packed around the incision as a special precaution against infection of the Peritoneal Cavity.

If the Abscess is deeply seated in the gland-tissue an incision may be made with the Thermo-Cautery (also for operations on the Lung).

Drainage tubes enveloped in Iodoform gauze protrude from the wound, which is united at its upper and lower extremities by deep sutures (through muscles and skin).

For extensive Abscesses counter-openings in the back are necessary.

Plate XXXIV.

External Urethrotomy (Prostatectomy)

Plate XXXIV.

External Urethrotomy (Prostatectomy)

INSTRUMENTS

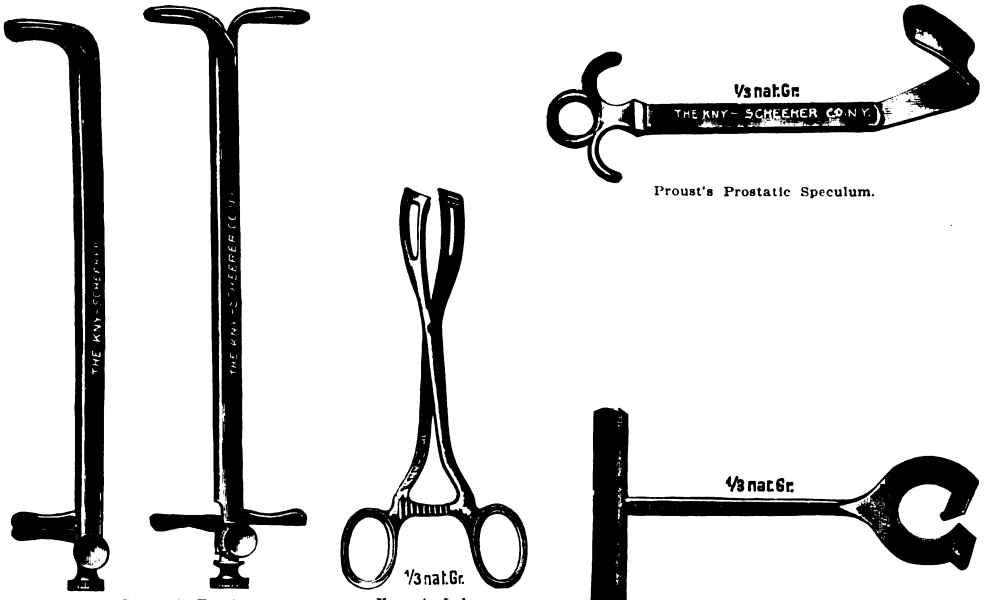

Young's Prostatic Tractor.

Young's Lobe Forceps.

Proust's Prostatic Speculum.

Proust's Prostatic Retractor.

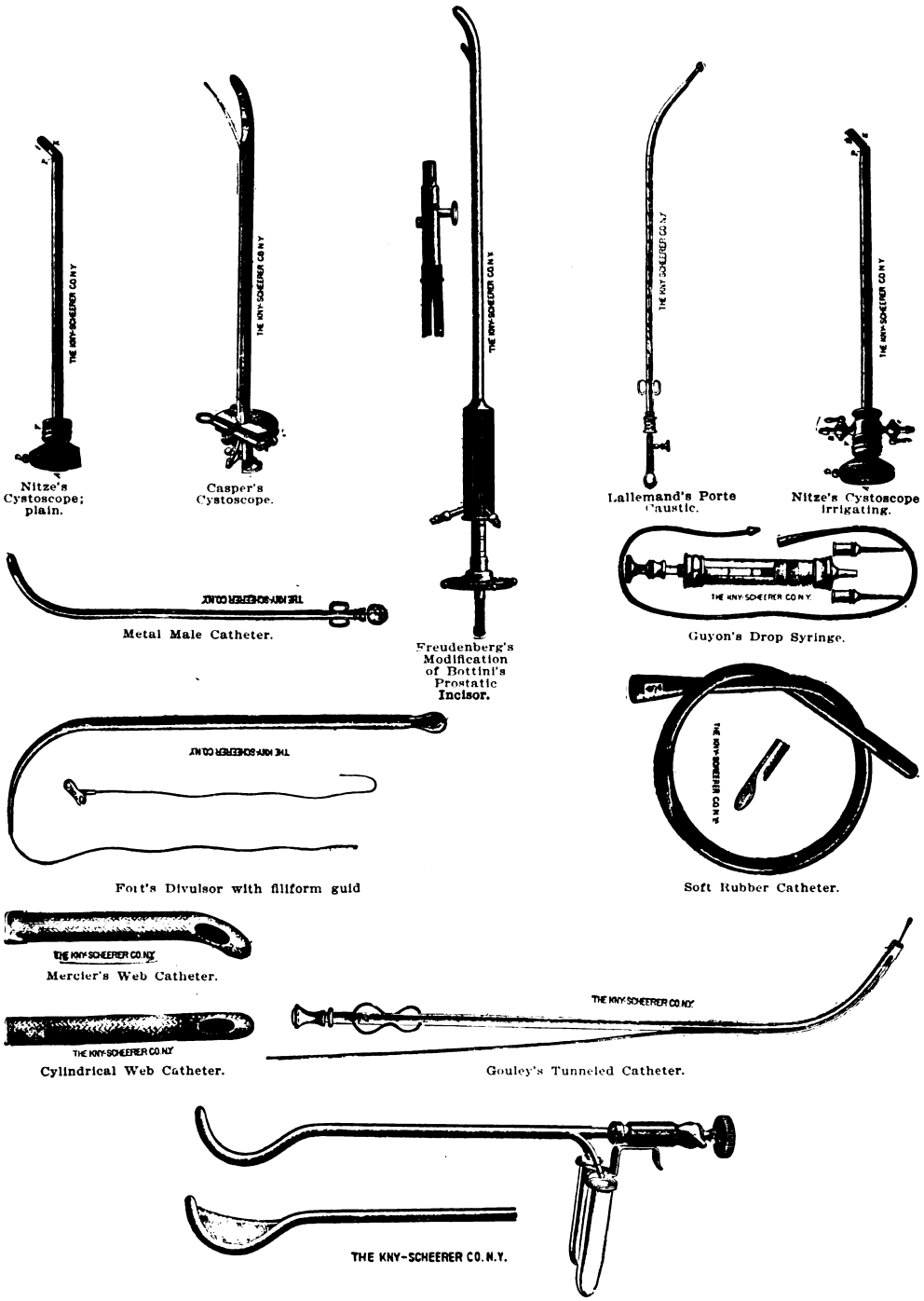

Nitze's Cystoscope; plain.

Casper's Cystoscope.

Freudenberg's Modification of Bottini's Prostatic Incisor.

Lallemand's Porte Caustic.

Nitze's Cystoscope irrigating.

Metal Male Catheter.

Guyon's Drop Syringe.

Fort's Divulsor with filiform guid

Soft Rubber Catheter.

Mercier's Web Catheter.

Cylindrical Web Catheter.

Gouley's Tunneled Catheter.

Luy's Urine Segregator.

External Urethrotomy (Prostatectomy)

STAGE I.

In Retention of Urine we generally have to deal with Enlargement (Hypertrophy) of the Prostate or Stricture of the Urethra. Rectal examination will best reveal any Enlargement of the Lateral Lobes of the Prostate. Enlargement of the Middle Lobe is generally ascertained by catheterisation. Cystoscopy, as a rule, informs us of the size and condition of the Prostate. Strictures (generally the result of Gonorrhœa), if callous, can be felt in the Perinæum, whereas cicatricial strictures are better investigated by the introduction of Urethral Bougies.

The greater majority of strictures (Gonorrhœal in origin, and oftentimes multiple) are situated in the Bulbous Portion and at the Bulbo-membranous Junction of the Urethra; nevertheless, strictures are found to occur, more anteriorly, in the Penile Portion or near the Bladder in the Prostate Portion.

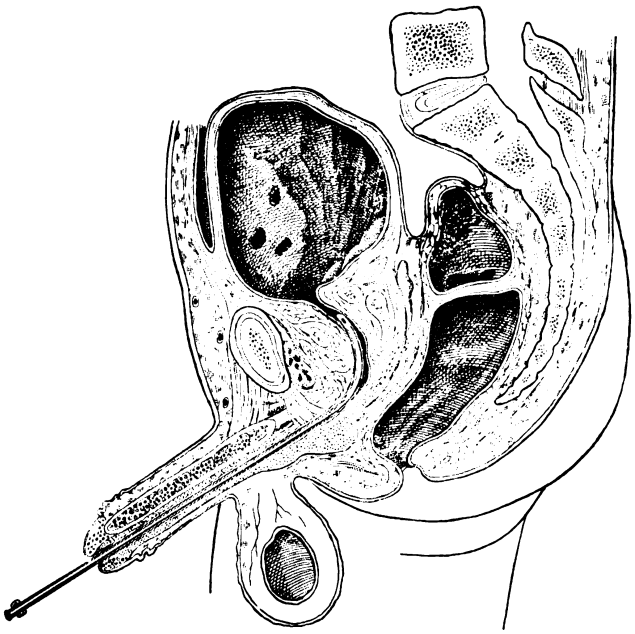

Median Section of Male Pelvis, illustrating Hypertrophy of the Prostate (Von Bergmann's Clinique).

In retention of Urine, the practitioner should first try catheterisation.

In any case whether the retention be due to Prostatic enlargement or to Stricture, we first employ a stout metal catheter because such an instrument is less liable to injure the Urethra. In cases of Enlarged Prostate Catheters with a special curve and those devised by *Mercier* are recommended because their curve corresponds more closely to the course of the Urethra in this affection (Cf. Instruments and drawings).

Should the Catheter of large calibre meet with failure, bougies of various sizes are tried, and ultimately delicate filiform bougies. When several such bougies shall have been passed as far as the stricture an attempt is made to push one of them through the stricture. Filiform bougies often crown with success the attempts of a patient practitioner.

Chloroform Anæsthesia is to be recommended (several deaths have occurred during Cocaine-Anæsthesia of the Urethra).

When once a filiform bougie has been passed into the Bladder, this should be allowed to remain there for 24 hours, at which time it is replaced by a catheter of small calibre or Rapid Dilatation with suitable bougies might ensure the introduction of *Le Fort-Frank's* Stiff Catheter or *Gouley's* Catheter. The further treatment of stricture consists in gradual dilatation by means of bougies or catheters of larger calibre. When the Urethra will admit of the passage of a Catheter of large calibre the patient is given a Zinc-bougie to pass for himself (for the period of one year).

If the stricture is at first impassable, the introduction of a stout catheter which is retained in this position for a few hours, is useful, and often allows of complete introduction later. It is essential to stimulate micturition by means of hot baths.

In those cases in which no repeated unsuccessful efforts have been made to introduce a catheter into an apparently impassable stricture, where presumably there is no false passage, repeated puncture of the bladder may be performed. The puncture is made accurately in the middle-line and directly above the Symphysis (the bladder must extend above the Symphysis), by means of an aspiration-syringe; in emergency by an ordinary Hypodermic Syringe.

The urine is then aspirated by means of the syringe.

If False-passages are present, if Hæmorrhage or Rigors have occurred, then Immediate External Urethrotomy should be carried out because the Extravasation of Septic Urine may easily and rapidly be followed by Cellulitis.

The operation is rendered easier by the passage of a stout curved metal catheter or staff as far as the stricture; for this purpose an Anæsthetic is usual (General Anæsthesia or *Tuffier's* Lumbar Anæsthesia). The Thighs are flexed upon the trunk and a cushion is placed under the pelvis.

Incision: The best incision is made longitudinally along the raphé of the Scrotum extending the whole length of the Perinæum and passing through the skin and Superficial Fascia. In our figure a transverse incision is shewn extending from one Tuber Ischii to the other. (This incision is preferable to the longitudinal

incision in the operation of Prostatectomy.) The incision may be made on to the Bulbo-Cavernosus Muscles, as they unite in their accurate median raphé. If the disease will allow, the Bulb of the Urethra deep to these muscles should not be exposed as injury to the cavernous tissue gives rise to disagreeable hæmorrhage.

If the Bulb must be exposed, the incision should be made exactly through the median raphé and continued down on to the Urethra. The Central Point of the Perinæum where the several muscles meet, as indicated in our figure, *is rendered evident prior to exposure of the Prostatic Portion.* "Behind this Central Point a transverse incision is made, while a finger introduced into the Rectum ascertains the size and extent of this Canal." At this stage these muscles are pulled forwards with blunt hooks, whereas the divided Sphincter Ani and the partially divided *Recto-urethral muscles* are pulled downwards. In this way the Prostate is exposed. The Urethra into which a catheter has been inserted is incised on the side distal to the stricture, two silk traction-sutures are passed through the edges of the Mucous Membrane; by means of these the frequently narrow and tortuous stricture is easily found.

Opened Bladder, showing Prostate with very large middle lobe. (V. Bergmann's Clinique.)

The stricture is incised throughout its length, and if not too extensive the urethra in the region of the stricture is excised (*i.e.,* a cylindrical portion is removed).

The edges of the healthy urethral mucous membrane are united anteriorly and laterally by sutures. The posterior wall is left open (Introduce a Catheter).

If the stricture is extensive the Urethra should be slit up and a catheter passed through this slit into the Bladder. The distal end of the catheter is pushed in a retrograde manner towards the External Meatus until the end protrudes.

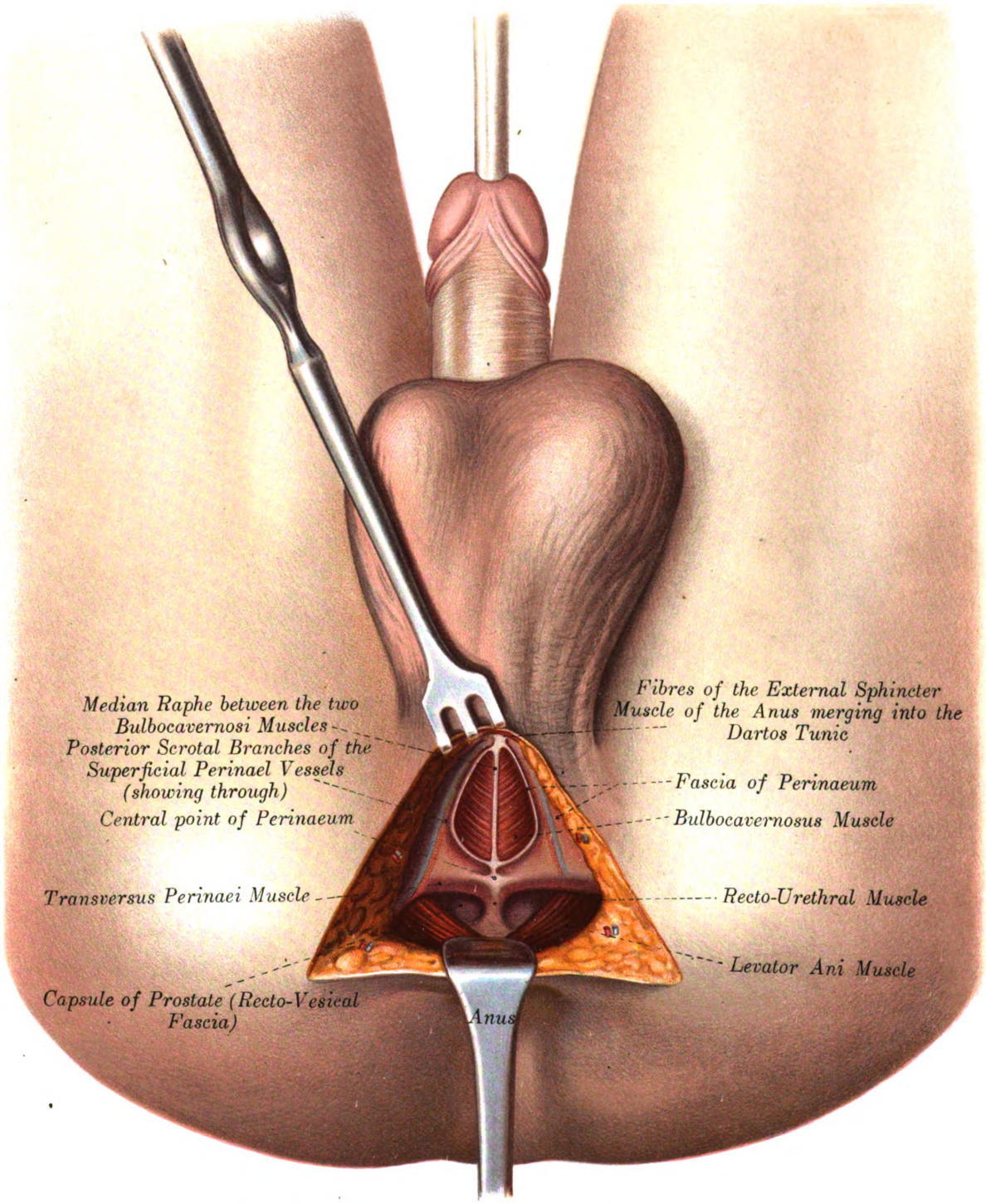

Enucleation of the Prostate (Stage I.).

The Perineal wound is only sutured in part; the unsutured part is packed with Iodoform-gauze.

The after-treatment consists in Methodical and Gradual Dilatation with bougies and metal catheters; the Bladder must be disinfected with Urotropin,* or Camphoric-Acid to avoid or improve a Cystitis.

*Heluntol.

Plate XXXV.

External Urethrotomy (Prostatectomy)

External Urethrotomy (Prostatectomy)

STAGE 2.

Plate 34, which illustrates the operation for External Urethrotomy, also represents the first stage in the operation of Prostatectomy.

When the diagnosis of Hypertrophy of the Prostate has been arrived at, the following three ways have to be considered in view of treatment.

1. Catheterisation, which the patient can do for himself (after due instruction), is the procedure most to be recommended, when the prostate is only slightly enlarged and catheterisation can be easily carried out.

2. *Bottini's* Operation (Incision of the Prostate. cf. Instruments); Cystoscopy having first revealed the extent of the Hypertrophy, incisions with the Thermo-cautery are accordingly made. By division of one or both lateral lobes or of the middle lobe, the flow of Urine can be markedly improved.

3. Prostatectomy, the best method is through the Perinæum. The indications for this operation are:—

1. Marked Hypertrophy of the Lobes (Tumours).
2. Considerable amount of Residual Urine in the Bladder.
3. Catheterisation almost impossible.
4. Extensive Hæmorrhage.
5. Frequent and painful desire to micturate (*Strangury*).
6. Acute Cystitis.

The operation is by no means devoid of danger and should only be performed at the request of the patient, who should be informed that the sexual functions may be considerably affected after the operation.

Cystitis must be cured or partly cured before undertaking the operation.

Contra-indications: Diseases of the kidney, especially Pyelo-Nephritis.

Cystoscopy is employed to determine the presence of a large Middle Lobe and to ascertain the size of the Lateral Lobes.

Anæsthesia: Chloroform, Ether, *Roth-Dräger* apparatus. *Tuffier's* Lumbar Anæsthesia.

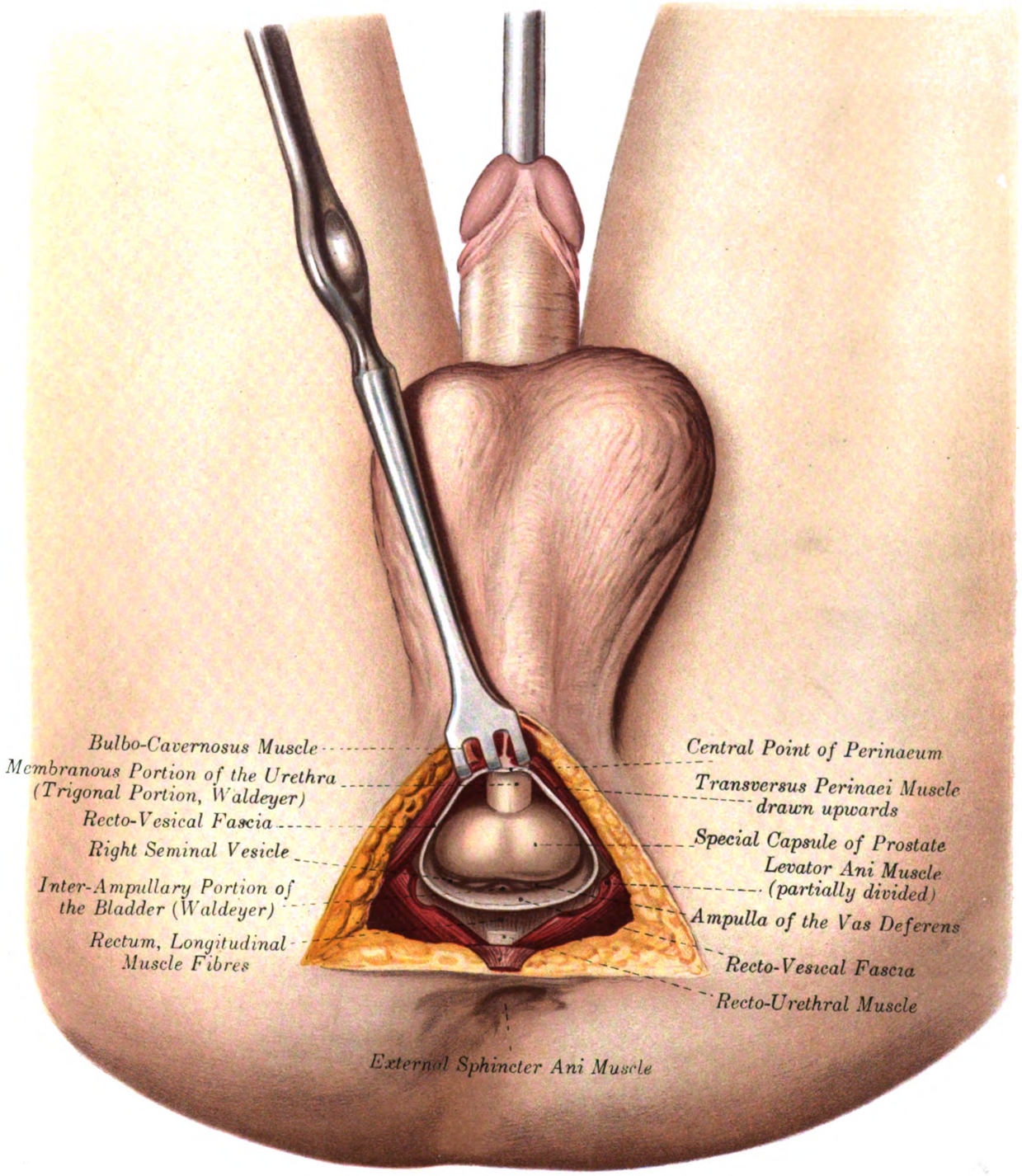

Enucleation of the Prostate (Stage II.).

Rebman Limited, London. *Rebman Company, New York.*

A stout catheter is introduced into the Bladder.

The transverse incision behind the central point of the Perinæum having been made, the Prostatic Portion is rendered more accessible by drawing the muscles upwards (towards the pubes) so that the Transversus Perinæi muscle becomes directed obliquely; the Membranous as well as the commencement of the Prostatic Portion of the Urethra is thus exposed to view.

In order to gain access to the posterior part of the Prostate Gland the Levator Ani (here called the Levator Prostati) Muscle is divided to a slight extent on both sides. The divided External Sphincter Ani and the partly divided Recto-urethral Muscle are drawn downwards (towards the Coccyx) by means of (*Proust's*) hooks.

The Hæmorrhage from the Perinæal Vessels and the vessels of supply to the posterior part of the Scrotum (these generally escape injury) is of no consequence.

The more the Lateral Lobes are enlarged the more room is sought by division, as far as is necessary, of the muscles which surround the gland and by drawing them apart.

Plate XXXVI.

External Urethrotomy (Prostatectomy)

External Urethrotomy (Prostatectomy)

STAGE 3.

In the performance of these operations a careful consideration of the fascia is important (to avoid the wrong partition).

In accordance with our routine we follow up the Recto-vesical Fascia, because by carrying the incision posterior to this injury may result to the rectum. Divide this Fascia transversely (Cf. Stage 2) and proceed forwards towards the Prostate (towards the catheter which has been introduced).

When the Prostate is well exposed *Young's* tractor (Cf. Instruments) is passed (in the closed condition) through the Urethra into the Bladder. The instrument is now opened and drawn towards the operator, so that the Prostrate can be bought into the wound. When the Prostate is of very large size this instrument is worthless (*Bockenheimer*). By now incising the Capsule of the Prostate longitudinally the gland-substance can be scooped out (with Elevator or *Cooper's* scissors). The removal may be complete.

When the parenchyma is soft the removal is carried out piecemeal (*V. Mikulicz* in 20 pieces, *Bockenheimer* in 6 pieces). Both Lateral Lobes should in succession be completely removed, because, in many cases after separation, the lobes appear only to be adherent to the Urethra and neck of the Bladder.

Urethral and Vesical drainage should be employed as little as possible. It is wise to divide the posterior urethral wall in the middle line, and to remove the Prostate with as little harm as possible to the Urethra and Bladder. By opening the Urethra in this manner, further injury to the neck of the Bladder is avoided, whereas the finger passed through the neck of the Bladder gives the special advantage of examination of the Middle Lobe of the Prostate. This Middle Lobe, if present, can be removed by the Thermo-cautery loop. Should this Middle Lobe be of extreme size a secondary high operation will need consideration. (Cf. Drawing, Stage 2.) A drainage tube is passed into the Bladder through the opening in the Urethra, while a Retentive Catheter is introduced through the External Meatus and passed over this opening into the bladder. The wound is packed with Iodoform-gauze and partly sutured on both sides.

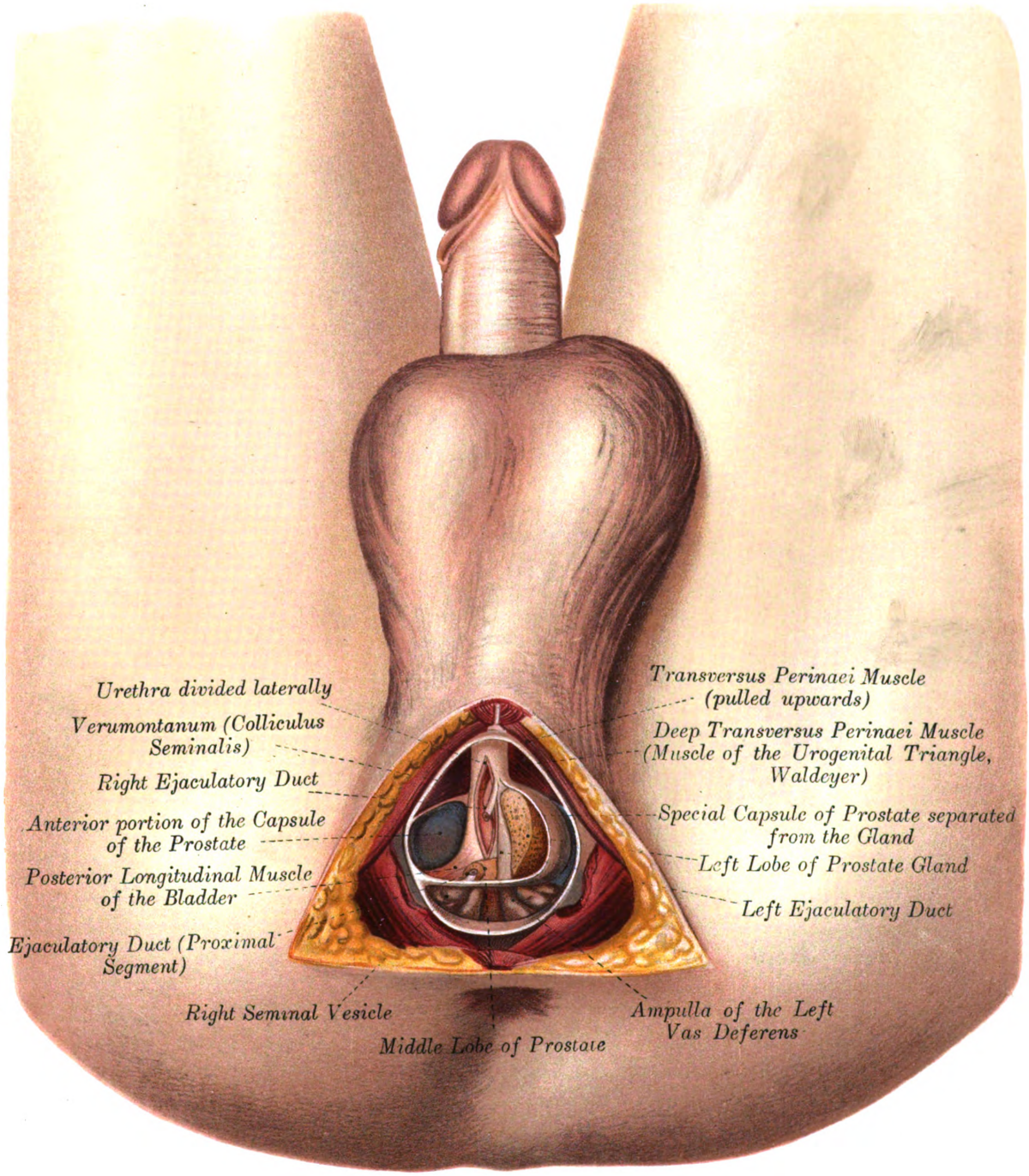

Enucleation of the Prostate (Stage III.)

Rebman Limitea, London. *Rebman Company, New York.*

Hæmorrhage from the Prostatic Plexus of Veins is avoided by allowing the Capsule of the Prostate to escape uninjured. Under other conditions the bleeding is slight. We desire to draw attention to the Shock which follows tearing of the Bladder wall.

This operation appears to have a future before it, inasmuch as the patient feels immediate comfort, and micturition is permanently improved when the operation carefully carried out. Statistics of 400 operations show a mortality of only 6.5%, an exceedingly low figure in consideration of the advanced age and generally weak constitution of the patients.

The permanent results have also been good. (*v. Mikulicz.*)

Plate XXXVII.

Cellulitis of the Neck

Cellulitis of the Neck.

General Anæsthesia.

Aetiology: Dental Caries, Angina, Infectious Diseases (especially Scarlet Fever), Eczema, Furuncle, Disease of the Jaw, Foreign bodies in the Throat, Otitis Media, etc.

We assume that the reader is familiar with the Anatomy of the Neck. A thorough knowledge of the Cervical Fasciæ and glands is indispensable for the study of Cellulitis of the Neck. Under the skin and superficial fascia lies a dermal-muscle, the Platysma, which is separated from the Infra-Hyoid Muscles by a fascia. This fascia ensheaths the entire laryngeal and pharyngeal regions and blends laterally at the anterior border of the Sterno-Cleido-Mastoid Muscle. As a rule there is no fascia superficial to the Platysma which could be displayed as a separate structure. Deep to the Platysma the fascia above mentioned passes over the Sterno-hyoid to the outer surface of the Sterno-Cleido-Mastoid on either side (Fascia Propria Colli.) Deep to the Infra-hyoid and Sterno-Mastoid muscles, lies the Fascia Media which bifurcates to enclose the Neuro-Vascular bundle, Larynx and Oesophagus—the prevertebral muscles and the uncovered portions of the cervical veterbræ are enclosed in the Fascia Profunda.

The new B. N. A. nomenclature only recognises a "Fascia Colli" (corresponding to the Fascia Propria Colli) and a Prevertebral Fascia (Fascia Profunda).

The arrangement of the lymphatic glands in the neck is as follows:

1. Sub-Maxillary glands.
2. Superior Submental glands in the Submental region. Inferior Submental glands on the Mylohyoid muscle above the Hyoid bone.
3. Superficial Cervical glands on the Sterno-Cleido Mastoid muscle.
4. Deep Cervical glands along the large vessels of the Neck.

One or other group of these lymphatic glands is, according to the localisation of the disease, the primary seat of the infection; the fasciæ are only of importance in the spreading of the cellulitis.

The most common form of Cellulitis of the Neck,—most frequent in young individuals—is the circumscribed variety which leads to the formation of abscess. In 50 per cent of all cases of cellulitis of the neck the submaxillary region is involved, the lymphatics around the Submaxillary Gland being diseased, whilst this Salivary Gland remains unaffected. (*Jordan's* Extra-capsular Phlegmons.)

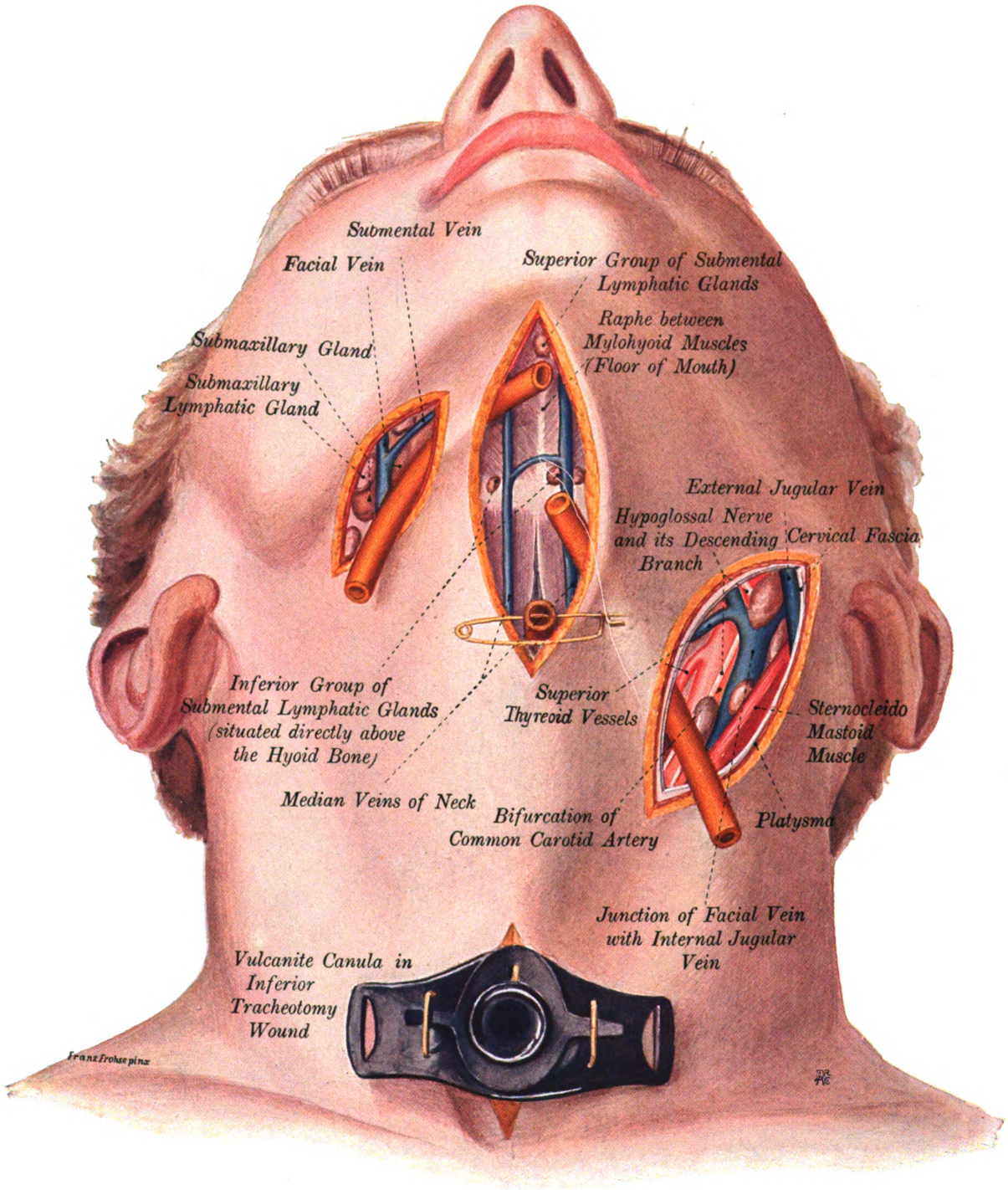

Cellulitis of Neck.

The head is strongly inclined backwards, a cushion being placed under the scapulæ. The incision is made 2/5ths inch below, and parallel with the lower border of the lower jaw. The skin, Subcutaneous tissue, Platysma and Fascia Propria are divided. The Submental and Facial Veins which lie in front of the Submaxillary gland are ligatured.

The pus is removed, the wound swabbed, and a drainage tube inserted. Burrowing into the deeper cervical regions is not common. *Ludwig's* Angina (Intracapsular Submaxillary Cellutitis) is recognisable by enormous swelling of the Suprahyoid region, Protrusion of the Floor of the Mouth, Dyspnœa, General Malaise. The œdematous parts should be incised and the Submaxillary gland (cf. fasc. I, No. 11) cleared out of its sheath, before abscesses have been formed. If necessary, multiple incisions towards the middle line, or even beyond it, incisions through the floor of the mouth and low tracheotomy should be performed. The prognosis is less favourable owing to the possibility of general infection.

For Submental cellulitis, we incise exactly in the middle line. The Mylohyoid raphé and the Anterior Jugular Veins serve as landmarks. Where too great a swelling obscures these landmarks, palpation of the hyoid bone will guide the operator. In these cases, lateral incisions may be sometimes necessary.

For deep median cellulitis, the connective-tissue between the Sterno-Hyoid Muscles has to be divided; a drainage tube is then inserted between the muscles, right down on to the Trachea and Larynx.

Superficial lateral cellulitis of the neck involves the superficial cervical glands and is treated by an incision through the skin and platysma.

Deep lateral cellulitis of the neck, which involves the glands in the carotid sheath, is liable to produce Oedema, Dysphagia, Dyspnœa; owing to the possible formation of abscess under cover of the Sternomastoid with abnormal positions of the head, deep incisions should be made; contrary to *Kocher,* we cut down along the inner border of the Sterno-Mastoid and expose the Muscles carefully, after having divided skin, superficial fascia, platysma, fascia propria of the neck and the muscular fascia.

The muscle is then drawn outwards and thus the carotid sheath exposed. This sheath is then split open; hereupon the Jugular Vein (frequently as thick as the thumb) comes into view; deep and internal to the vein lies the Common Carotid Artery; on the latter the descendens hypoglossi (for the muscles between the Hyoid Bone and the Sternum), which should not be injured, passes downwards.

The small veins in front of the Jugular Vein have to be ligatured beforehand if necessary. As the anatomy is frequently obscured in these cases by much œdema, the Jugular Vein may be injured when our method of operating is adopted, however cautious one may proceed. The danger would be an air-embolism.

As soon as the danger to the vein is observed the operator should place his finger upon the vein and seek the perforation; punctures may be closed by a lateral ligature, slits by a continuous suture; but the double ligature is always safer. Injury to the arteries is rare. In cases of lateral cellulitis, abscess extending into the Supra-clavicular region is not uncommon. This latter region, under these conditions, demands incision and drainage.

With the Retro-pharyngeal and Retro-œsophageal abscess and cellulitis, protruding laterally, we shall deal when discussing Oesophagotomy.

In those cases, where the relations of the seat of the cellulitis to the chief groups of glands cannot be determined, multiple incisions are made wherever Oedema is present. Diffuse cellulitis (generally due to Streptococci) spreads rapidly; the prognosis is bad; surgical measures should be adopted immediately. It is wrong to wait until an abscess has formed; frequently there is only purulent œdema with necrosis (Bacterium coli). Oedema of the entire neck extending to the thorax, with lymphangitic streaks is characteristic. The Cervical fasciæ being very strong, an abscess in process of formation cannot perforate them rapidly. We lay stress upon the fact that cellulitis of the most serious form may be unaccompanied by fever. (*Bockenheimer.*)

Incisions, as indicated, should be made very freely in such cases.

Whenever (œdema encircling the neck, bad general condition, etc.) there is ground to suspect diffuse cellulitis, we perform low tracheotomy before dyspnœa (recognisable by the condition of the tongue and slow speech) sets in. This is the only chance of saving these cases; without treatment, œdema of the glottis or sepsis kills the patient quickly.

Even when incised early, diffuse cellulitis has a tendency to perforate into the Oesophagus, Trachea, and Mediastinum. Perforation of the vessels by pus has also been observed, as well as Pericarditis and Pleuritis. The incisions are kept open by gauze-drains and drainage tubes.

Only when purulent conditions cease, granulations appear and the temperature falls, should the tubes be removed. In special cases, the tracheotomy tubes may be removed at the same time.

Plate XXXVIII.

Supra-pubic Cystotomy.

Plate XXXVIII.

Supra-pubic Cystotomy

INSTRUMENTS

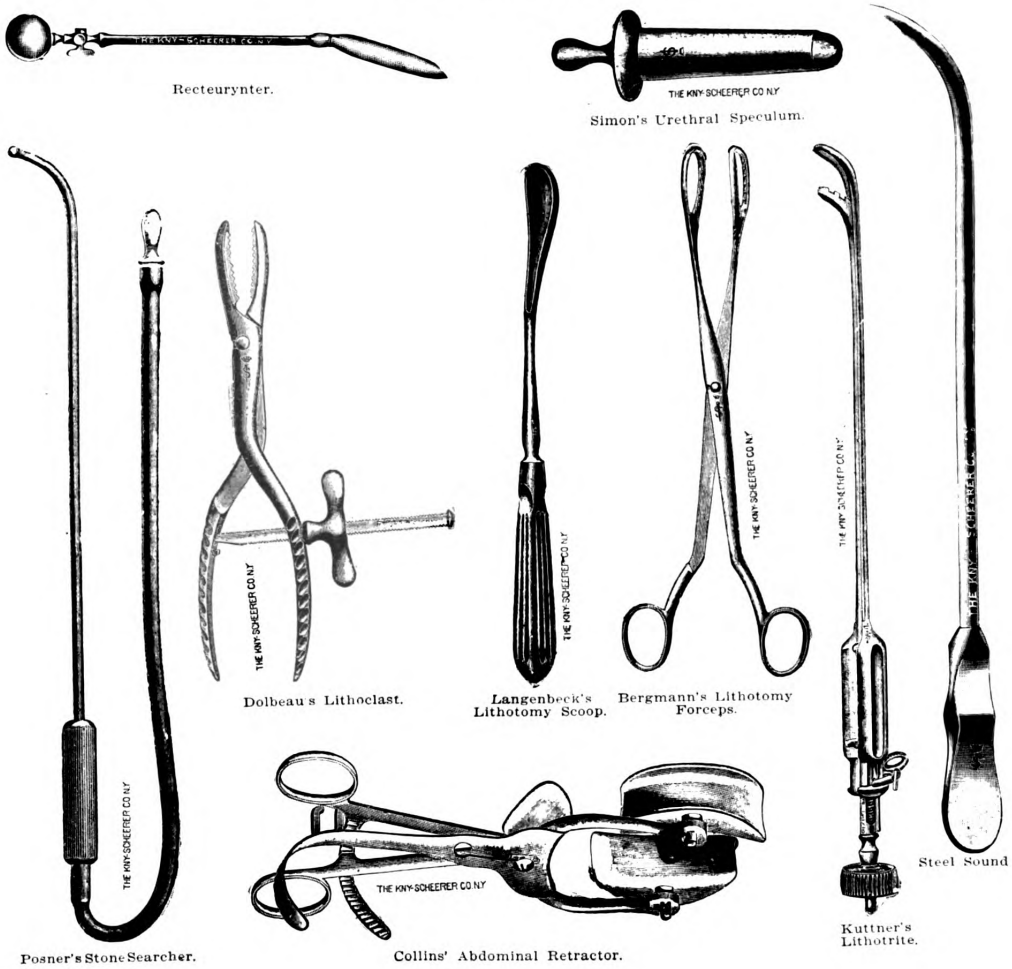

Suprapubic Cystotomy

Opening of the Bladder above the Pubis.

Chloroform or Ether for General Anæsthesia; *Tuffier's* Lumbar Anæsthesia.

Position: *Trendelenburg's.* The operating table is adjusted in such a way that the Thorax and Head are the most dependent parts; the legs are flexed and tied to supports.

Indications: Whilst in women the Urethra may be gradually dilated by means of *Simon's* specula, and stones of moderate size be removed by this route, large and hard stones must always be removed, in men and children, by suprapubic cystotomy. Other indications are Tumours, Traumatism, Disease of the Bladder, Prostate, Parasites (Bilharzia Hæmatobia), Purulent Cystitis, Tubercle, Inoperable Strictures of the Posterior Urethra, Intra-Peritoneal Rupture of the Bladder.

Preparations: Lavage of the Bladder for several days with normal saline solution (*v. Bergmann,*) Introduction of a Metal Catheter into the Bladder which is left during the operation with a rubber tube and clip attached.

In order that the Bladder should rise above the Pubis:

(1) 200-300 cc. (= 7-10 oz.) air are introduced into the Bladder; the rubber tubing is then clipped, a tourniquet is placed around the base of the Penis.

(2) A *Recteurynter* (cf. Instruments) is introduced into the Rectum, and inflated. The bladder then bulges forwards above the Symphysis. The line of reflection of the Peritoneum can, by further inflation be pushed upwards as far as midway between the umbilicus and symphysis. The umbilicus is pulled upwards with a sharp hook; the linea Alba is thus made tense.

The incision is made exactly in the middle-line through skin and superficial fascia. Its length is 2/3rds of the distance between the Symphysis and Umbilicus.

The place where the 2 anterior lamellæ of the sheaths of the Recti meet, is exposed and the incision carried through this point.

In its lower part, the incision must be exactly in the middle line between the 2 Pyramidales Muscles and should these muscles be absent (either on one or on both sides), the incision has to be made between the 2 Recti, which are then pulled aside by hooks. Should much room be required (*e.g.* for extirpation of the bladder) that portion of the symphysis which gives attachment to the Recti should be chiselled away. At the lower angle of the wound the fat in the Cavum Retzil, the anterior wall of the Bladder with its veins (Plexus of Santorini) are exposed. The most important point is the line of reflection of the Peritoneum, which should be carefully exposed. If necessary, veins must be ligatured. At the upper angle of the wound, the obliterated Hypogastric Arteries, the Urachus, and the posterior lamella of the sheath of the Rectus Muscle (which ends at the Semilunar Fold of *Douglas*), are seen. *Collin's* double retractor (cf. Instruments) is very useful when operating without sufficient assistance.

The incision of the anterior wall of the bladder should be made as near as possible to the summit of the viscus (the suture heals better).

Two silk traction-sutures are passed through the bladder wall; the organ is then drawn into the wound and incised with a small knife. The mucous membrane is immediately seized, on either side, with sharp hooks. For the removal of foreign bodies an incision one inch in length is ample, because the wall is elastic and stretches readily. The urine having been drawn off, the interior of the bladder is carefully investigated. Tumours of the mucous membrane are removed with the cautery. If the muscular layers are implicated Partial Resection of the Bladder-wall is performed.

In some cases the whole Bladder must be removed. The Ureters are then implanted into the Rectum. A Hypertrophied Isthmus of the Prostate is also removed with the cautery.

For Tumours of the Prostate, which implicate the neck of the Bladder, a division of the Ramus of the Pubis on either side is to be preferred (*v. Bramann, Lexer*). All blood and clots having been washed away with normal saline, the parts are sewn up. The mucous membrane should never be included in the stitches, because the latter would soon become encrusted by deposits. We never employ the continuous suture; if possible, we apply 3 layers of silk *Lembert*-stutures (*i.e.*, the needle enters the bladder wall 3/5th inch away from the wound and leaves it again on the same side. The needle is next entered on the other side, near the

margin of the wound, and leaves the bladder wall at a distance of 3/5ths inch from the wound.).

The edges of the mucous membrane are thus invaginated into the interior of the bladder. For 8 days an Iodoform gauze-drain is placed over the suture at the lower angle of the wound. The remainder of the muscle and skin incision is closed; the bones are wired where they have been divided.

No permanent catheter, but careful catherisation every 3 hours and irrigation of bladder is carried out. Urotropin 3 times per diem is administered. A Vesical Fistula (if it should occur) will usually heal by the application of Aluminium Acetate solution; otherwise a secondary-suture may be inserted.

In cases of Purulent Cystitis, Iodoform gauze-drain and permanent drainage tubes are used.

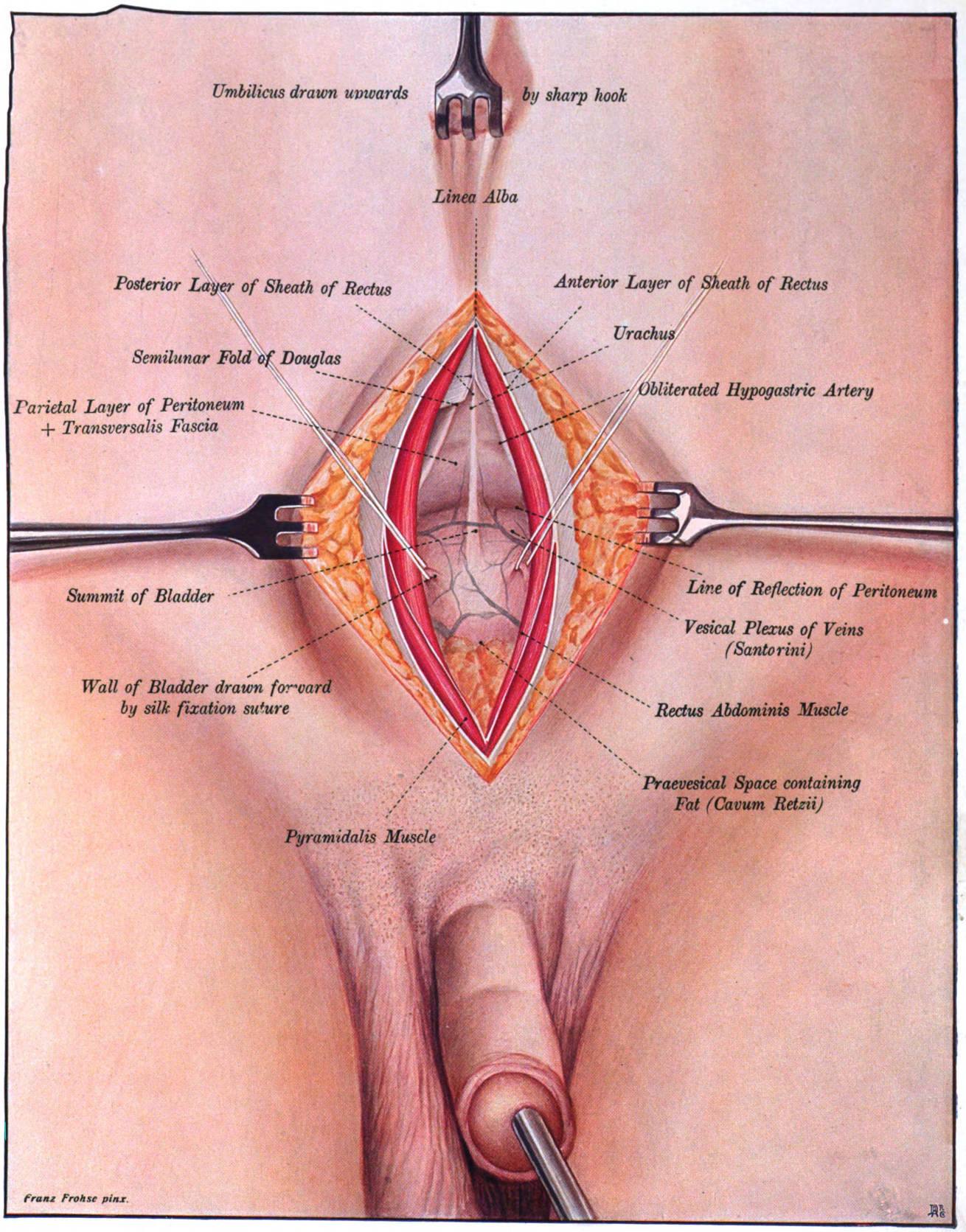

Suprapubic Cystotomy.

Plate XXXIX.

Laminectomy.

Plate XXXIX.

Laminectomy.

INSTRUMENTS.

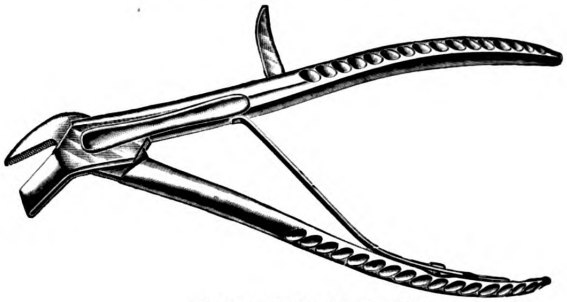

Hoffmann's Cranial Rongeur.

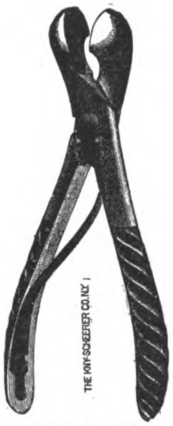

Esmarch's Bone Rongeur.

Van Buren's Sequestrum Forceps.

Anaesthesia Syringe for lumbar injections.

Liston's Angular Bone Forceps.

Curved Sequestrum Forceps.

Tuffier's Rachicocaine.

Stacke's Guard.

Laminectomy.

STAGE I.

General Anæsthesia: Chloroform or Ether. Lumbar Anæsthesia for the lower half of the Trunk as high up as the Umbilicus.

Technique of Lumbar puncture and Lumbar Anæsthesia:—Disinfection of the skin; the space between 2nd and 3rd, or 3rd and 4th, or 4th and 5th Lumbar Vertebræ is sought.

According to *Bier,* a line connecting the crests of the Ilia passes through the space between 3rd and 4th L. V. We perform the puncture at the 2nd space.

Bier places the patient on his side, with his left index finger he finds an intervertebral space and pushes the needle in 2/5ths inch below this spot (*i.e.,* 2/5ths inch towards the operating table). The Ligamenta Flava offer but little resistance.

Tupper gets his patient to bend as far forward as possible while in the sitting position. The needle is pushed in 2/5ths inch externally to the middle line forwards and slightly towards the middle line; it enters without any difficulty.

Platino-Iridium needles, 4 inches long and not too thick, are used (cf. Instruments); their point should not be too oblique. They should be sterilised in boiling water only, because alkalies, etc., precipitate the Cocain-base. The puncture is made without an Anæsthetic. The needle is pushed in to the depth of about 3 inches, until Cerebro-spinal fluid is drawn off. Should the needle become obstructed (*e.g.* by blood clots) a wire must be pushed through it in order to clear it. Coughing facilitates the flow of cerebro-spinal fluid (well visible in old and debilitated patients).

We use *Tuffier's* Prepared Spinal Cocaine (*Carrion,* Paris, Rue du Faubourg St. Honorée 54), sold in glass tubes (cf. Instruments). The point of the tube is broken off and the Cocaine aspirated with the syringe (the needle being fixed to it). The needle is then removed and used for the lumbar puncture.

As soon as cerebro-spinal fluid escapes, the filled syringe is connected with its needle; a small amount of fluid is aspirated, then the entire fluid contained in the syringe is injected very slowly (1-2 minutes). The needle is rapidly withdrawn and the puncture closed with collodion. This method (*Tuffier's*) is simple and safe.

Bier injects first 1 cc. of 0.5 per cent Adrenalin solution and allows the syringe to remain on the needle, in order to prevent any fluid from escaping. Five minutes afterwards he injects *with another syringe* 0.02 gr.—0.05 gr. of Cocaine in a 1 per cent solution.

Recently he has used a mixture of Stovain and Paranephrin as injection fluid (sold by *Eschbaum,* Bonn).

Children under 12 are excluded from this method; but old and debilitated patients bear it very well.

After the injection the head should be placed upright. Anæsthesia follows 10-45 minutes later, and frequently reaches as high as the nipple. The value of lumbar puncture for diagnostic purposes is well known (extravasation of Blood, Tubercle, Meningitis, etc.).

Laminectomy was first performed by *Macewen* in 1886; the first tumour of the cord was successfully removed in 1887 by *Gowers* and *Horsley*. Since that time the technique has been wonderfully improved.

By means of Segmental Diagnosis the seat of the disease of the cord can be accurately determined.

Indications: Disease of the Vertebral Column and of the Spinal Cord (Traumatism, Tumours, Inflammation, Foreign Bodies, Parasites).

Absolute Asepsis is necessary: the area of operation is protected (cf. abdominal operations) from the rest of the body by sterile towels, which are fixed on to the margin of the wound by hooked forceps.

The incision should be exactly in the middle-line, varying according to the seat of the disease, over the spinous processes. The latter are freed from their periosteum with a raspatory, and the Sacro-spinalis Muscle from its attachment to the periosteum with a knife. The spinous processes are freed right down to their root, thus the neural arches become exposed; the periosteum of the latter is also scraped off. The lumbar aponeurosis has already been somewhat severed. Large intramuscular vessels are clipped; the oozing from the numerous minute vessels is stopped by placing two broad retractors into the wound, and forcibly pulling aside the Erector Spinæ muscles.

The operation on the bones is performed as follows: As it is dangerous to use a chisel, a spinous process well exposed to its base is removed either with proper bone forceps (cf. Instruments) or with a *Gigli-Hyrtl* saw. The neural arch having been further exposed on either side, *Doyen's* Trephine (cf. Hemicraniotomy) is

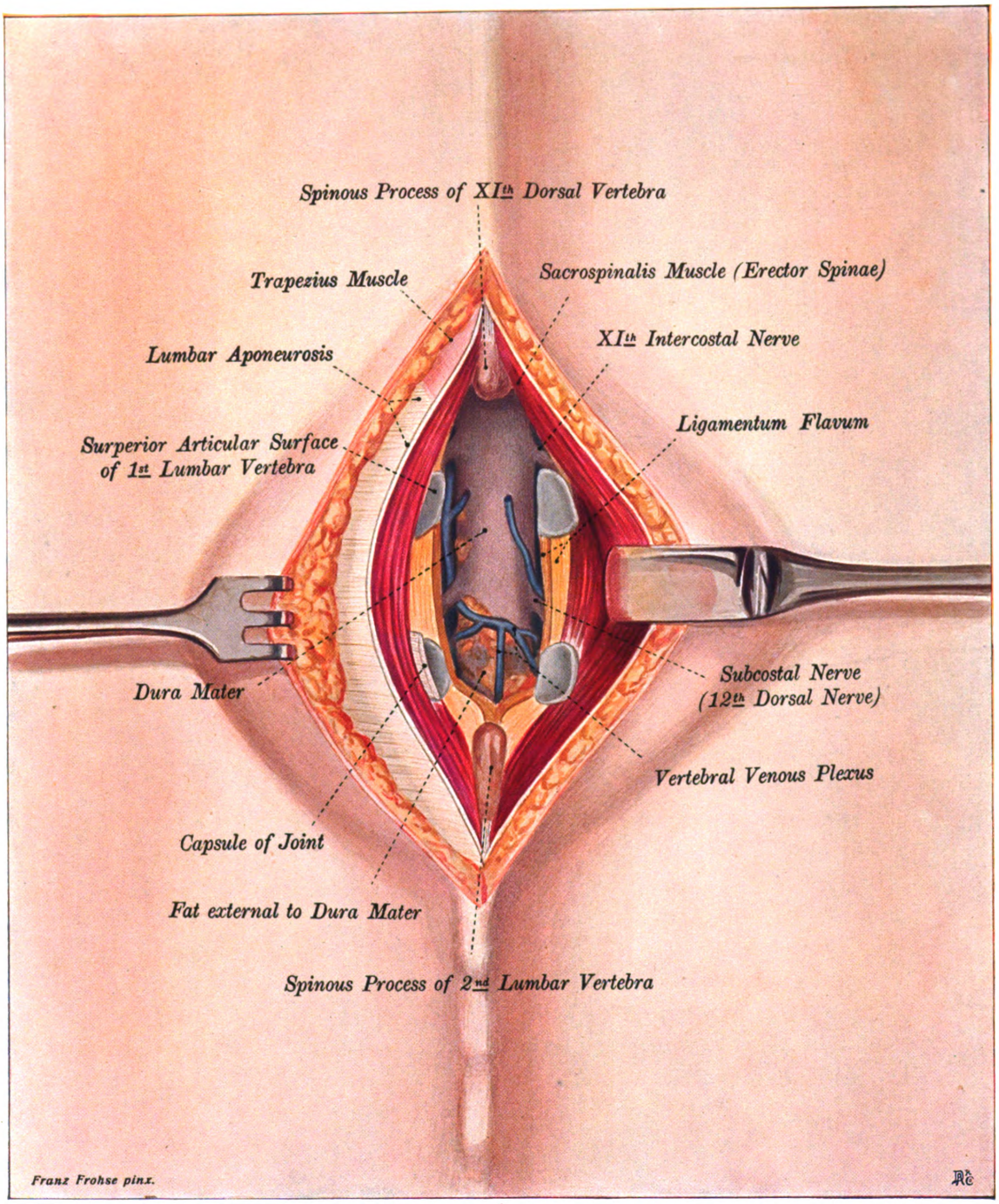

Laminectomy — Stage 1.

used to drill a hole into the spinal canal, either at the root of the spinous process, or directly external. In this way the Cord and the Dura Mater covering it are exposed. The cord can be guarded against injury during further removal of bony parts by pushing it away from the bones with a catheter or by *Stacke's* Instrument.

The several Arches are removed with curved bone-forceps or with *Luer's* instrument. It is advisable to divide the ligamenta flava attached to the upper and lower borders at an early stage in the operation.

Krause makes 2 trephine holes and then proceeds with an instrument invented by himself. (Laminectomy, cf. Instruments.)

If necessary, the skin incision must be prolonged, either upwards or downwards.

The temporary resection of neural arches, as practised by *Urban,* has become obsolete, because the bone easily becomes necrosed and interferes with subsequent healing.

After removal of the neural arches, the Dura Mater is exposed, covered by much fatty tissue and veins.

Plate XL.

Laminectomy

Laminectomy.

STAGE 2.

In cases of Bone or Epidural disease (*e.g.* Tumours, Lipomata, Myxomata—which occur in some forms of Spina Bifida) the Dura Mater should never be opened. In other cases, the Dura must be opened.

The fatty tissue over it is pushed aside; the veins are ligatured. The Dura Mater and the Arachnoid Mater under it are then incised longitudinally. The edges of the incision are fixed by traction-sutures and drawn aside. Thus an excellent view of the Cord and the Posterior Nerve-roots is obtained. There is an abundant flow of cerebrospinal fluid which may be diminished by lowering the head.

Tumours of the cord, mostly benign (Gliomata), are usually encapsuled, and easily removable. They are often found on the posterior aspect; when these occur on the anterior aspect, the cord should be gently lifted out of the spinal canal. In some cases this is only possible after a section of nerve-roots, which must subsequently be united by sutures.

Care should be taken to injure the cord itself as little as possible, because its regenerative powers are limited.

Recently, Spinal Nerves have been operated on inside the spinal canal, for the radical cure of Neuralgia (analogous with the removal of the Gasserian Ganglion). The choice lies between removing the mixed nerve outside the Dura Mater (cf. Stage 1), or opening the Dura Mater and resecting the Posterior Root of the affected spinal nerve. This plate shows the Intradural exposure of the Posterior Roots of the Great Sciatic Nerve (*Chipault*).

The posterior roots are carefully isolated and divided where they reach the

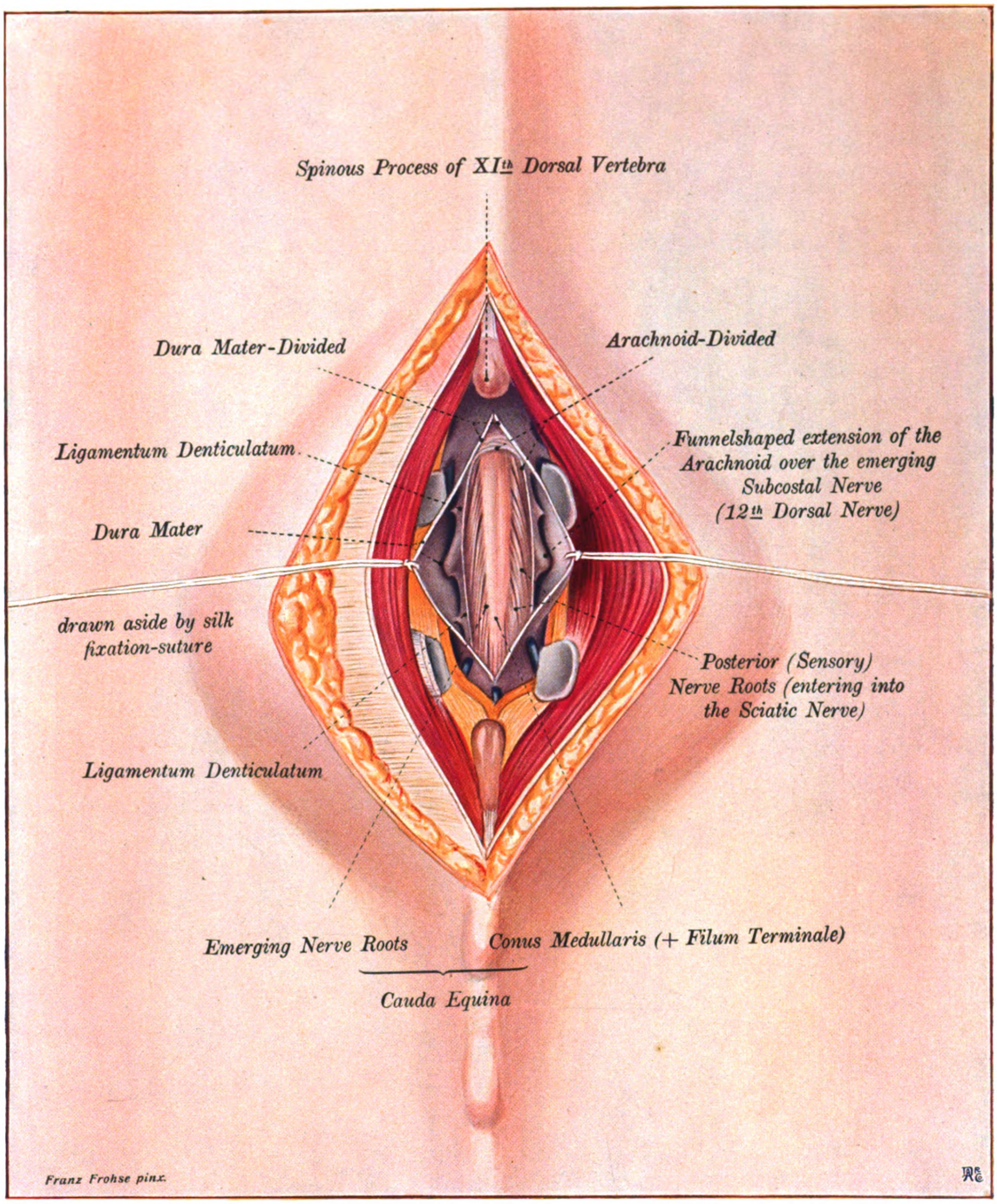

Laminectomy — Stage 2.

cord. As a simple division does not safeguard against recurrence a piece 2/5th-4/5ths inch long should be cut out of the nerve-root.

Excitation of the motor roots with a sterilised electrode (Faradic current) and the resulting motor twitches, do not necessarily (unlike stimulation of the cortex) yield information as to the origin of the sensory fibres, because the motor and sensory elements do not correspond exactly in the Spinal Cord.

The Intradural operation should be reserved for very severe cases; the results have been hitherto favourable.

Operations on the bodies of the vertebræ are dangerous, because the nerves are only too easily damaged during the operation.

The operation having been done, the Dura Mater is united with a continuous catgut suture, the muscles in a similar way, and over these the skin with further silk sutures. The dressing is sealed with adhesive plaster. The patient should be kept lying on his abdomen, with the head hanging down, in order to prevent the escape of the cerebro-spinal fluid, for the first few days. As soon as the dressing has become wet, it should be removed, because infection is liable to spread (*Bergmann*). Only where pus is present should drainage tubes be inserted and gauze-drains employed. Should profuse hæmorrhage make a drain necessary, the tampon should be removed early, and a secondary suture inserted.

All depends upon Primary Union! Apart from collapse, infection (meningitis) is the most frequent cause of death after operations on the Spinal Cord. Excessive escape of cerebro-spinal fluid may also prove fatal. The Dura Mater and the soft parts must, therefore, be sewn up with accurate approximation.

It is a good plan to place a sandbag over the dressing during the first 24 hours.

The nearer to the cervical portion of the Spinal Cord the operation is performed, the greater is the danger.

Plate XLI.

Permanent Inguinal Colotomy—Colostomy

Plate XLI.

Anus Contra Naturam.

INSTRUMENTS.



Schleich's Local Anaesthesia Syringe.

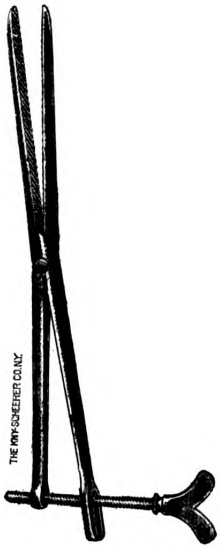

Dupuytren's Intestinal Clamp.

Pouch for Artificial Anus.

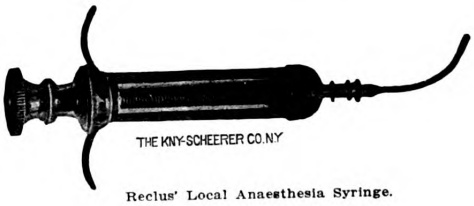

Reclus' Local Anaesthesia Syringe.

Permanent Inguinal Colotomy—Colostomy.

Local Anæsthesia (*Schleich, Reclus*), Lumbar Anæsthesia or General Anæsthesia.

The operation is indicated:

(1) If the Fæces are to be permanently evacuated at this situation.

(2) If no more Fæces are to pass into the distal portion of the Intestine (*e.g.* preliminary to operation for Excision of Rectum).

Indications: Disease of Colon and Rectum (Tumours, Syphilitic and Gonorrhœal Strictures).

The advantage of complete deviation of the fæces is the rest given to the diseased parts.

The situations selected for an Artificial Anus are the right and left inguinal regions; the seat of the disease determines whether a right or a left colostomy should be performed. Preference should be given, if possible, to the left, because on that side the fæces are already formed and of a firmer consistency; the patient, therefore, runs less risk of soiling himself. In our plate, the incision has been made as for Enterostomy (cf. Plate 42). The abdominal cavity being opened, the peritoneum is at once united to the skin by a continuous silk-suture. A portion of the Sigmoid Flexure (or if it be diseased, of the Descending Colon), is drawn out; a strand of gauze is passed through its mesentery, so that a large loop is kept outside the abdomen; in order to prevent this from slipping back into the abdomen, it is fixed by 4 sutures, one suture at the upper angle, a second at the lower angle of the wound, so as to unite the serous and muscular layers of the intestine to the peritoneum, already sutured to the skin; on the inner and outer aspects a fixation suture fastens the Mesosigmoid in the same manner on either side.

The operation is usually performed in 2 stages, in order that adhesions may be formed (after 1-3 days) between Parietal and Visceral Layers of Peritoneum. When the operation is carried out at one sitting, the serous layer and the mesentery must be well stitched to the peritoneum, which has been previously united to the skin. To protect the abdominal cavity, iodoform gauze should be placed around the entire loop, which is then opened with a knife or cautery. It is best to open the gut

transversely, first by a small opening, which is extended 8 days later to a complete transverse section. The mucous membrane of both lumina of the intestine is then fixed on to the freshened edge of the skin, which is again separated from the peritoneum, by means of button sutures in order to prevent retraction.

According to *Schinzinger,* one may divide the gut completely, close the distal part with a suture and bury it. The proximal end is fixed in the wound.

There should not be complete obstruction in the distal end because the Succus Entericus requires a means of escape. Therefore, the first method is to be preferred; another advantage is that it allows of irrigation of the distal part, and consequent disinfection of the diseased region.

The methods thus far described for obtaining an artificial sphincter are not indispensable.

As soon as the wound in the muscles and skin is healed, the patient may get up, wearing an adapted Truss. *Bergmann's* model (modified by *Kuster*) consists of a rubber ampulla, which is introduced into the gut, and there insufflated; it closes the anus very well. The most commonly used Truss (cf. Instruments) consists of an elastic india-rubber ring, which is placed around the anus. On this ring is a cup, which is applied to the abdomen by means of a spring similar to that of a Hernial Truss. Abdominal bandages with lappets may be used.*

The closure of an Enterostomy may occur spontaneously after excision of the mucous membrane; the Enterostomy may be cut out, the Mucous Membrane invaginated by suture and a skin flap sewn over (*Dieffenbach*). Wide Enterostomies can only be closed by separating the intestines from the abdominal wall, excising the fistula by cutting through healthy parts and sewing up the different layers of the intestine.

The safest method of removing an artificial anus is the application of *Dupuytren's* Intestine Clamp. By this means the spur between the distal and the proximal ends disappears slowly, the artificial anus is converted into a simple fistula which can be closed by the above method.

In some cases (*e.g.* in a fistula following an incarcerated hernia) the opening is closed by a laparotomy carried out at a short distance from it. After having opened the abdominal cavity, the intestine is divided through healthy and non-adherent tissue (Cf. Excision of Intestine) with a clamp; the 4 stumps are ligatured and sewn together. We next connect up by a lateral entero-anastomis. The part of the intestine which has been shunted out, containing the Anus or fistula, is

freed inside the peritoneum after ligature of the mesentery and separation of the adhesions.

When a fistula of the abdominal wall is removed, a circular incision should be made in order to allow the intra-peritoneal movable intestine to be drawn out of the abdomen. The laparotomy wound is sewn up in the usual manner; tamponade for the former fistula.

Such extensive operations should not be done, if possible, on the large intestine because the sutures are more liable to give way.

*The improved Aseptic Colostomy apparatus made by Pengelly,(Bailey & Co., London,) is the best pattern I am familiar with.—J. Howell Evans.

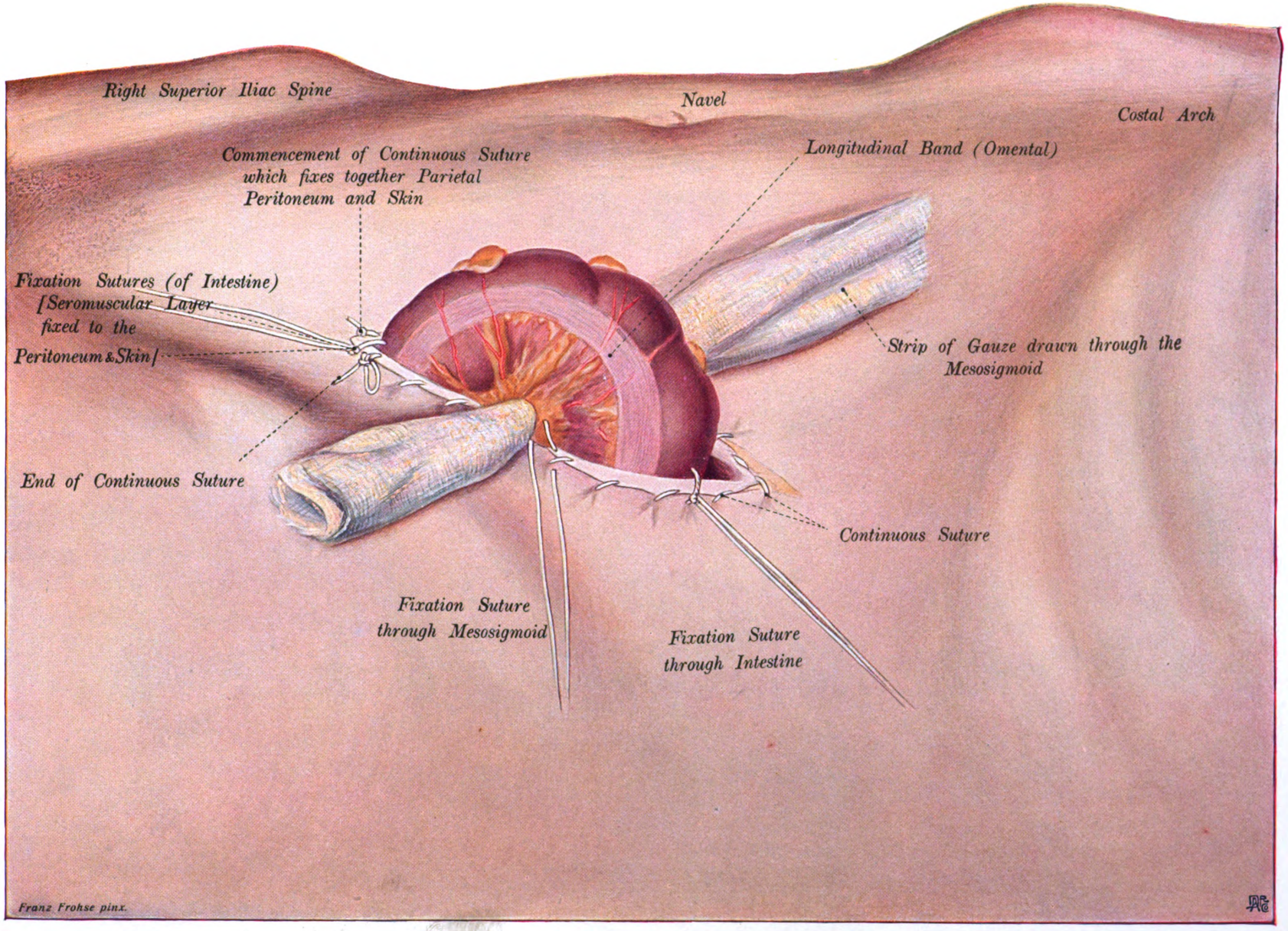

Colostomy (Permanent Colotomy).

Rebman Limited, London.

Rebman Company, New York.

Plate XLII.

Enterostomy

Enterostomy.

Schleich's or *Reclus'* Local Anæsthesia. General Anæsthesia or Lumbar Anæsthesia.

The opening of the lower portion of the intestine is intended to give temporary or permanent evacuation of the fæces (Ileostomy, Colostomy). In the so-called Enterostomy, only a portion of the intestinal wall is sewn to the wound; complete defæcation does, therefore, not take place at the opening; a portion of the fæces pass along the natural channel. In most cases the evacuation is only intended to be temporary.

Indications: Stenosis of Intestine, Atony, Peritonitis (Ileostomy), Disease of Colon (Colitis Polyposa), Disease of Rectum (Tumours, Strictures). In those cases where the Sigmoid Flexure is already implicated, the operation should be performed on the right side; this rule holds good also for all cases where any doubt, as to the seat of the disease, exists. Otherwise the intestine should be opened as near the anus as possible (*i.e.,* on the left) in order to avoid any impairment in the nutrition of the patient. The points of selection are the right and left inguinal regions (Inguinal Colotomy; Cæcum or Descending Colon).

In the middle line Enterostomy may be necessary after a laparotomy, if the diseased intestine is much distended and atonic. A loop of Ileum, as near as possible to the Cæcum, is then fixed to the wound.

The Enterostomy shown in our plate is on the right side. The skin incision 2—4 inches long is made one inch above and parallel with the outer half of *Poupart's* ligament. The External Oblique Muscle and its aponeurosis are divided as well as the Internal Oblique and Transversalis Muscles under it. The Muscles are drawn apart by blunt retractors so as to expose Fascia Transversalis.

Before opening the peritoneal cavity the region is covered with sterilised

towels. With 2 hooked-forceps the Fascia Transversalis and the Peritoneum, which are frequently adherent to each other, are lifted up and carefully incised between the forceps. The edges are immediately secured. Through the incision, which is usually 1-1.1/5 inch long, the distended intestine (usually small intestine) protrudes.

The only way of differentiating between large and small intestine is the presence of Appendices Epiploicæ, because the Haustra and Longitudinal Bands may be unrecognisable, and the direction of the Mesocolon indistinguishable. The Mesentery proper arises in front of the vertebral column near the middle line; the Mesocolon runs along the outer side (with the exception of the Transverse Mesocolon which does not come into the question).

For Ileostomy, a loop of Ileum as near as possible to the Cæcum is chosen. The part opposite the mesentery is sewn in. In Colostomy, the longtitudinal band opposite the Mesocolon is fixed to the wound.

The intestine is fixed to the skin by a continuous circular silk-suture, which passes through serous and muscular coats and takes up the peritoneum and fascia transversalis. The stitches should be 1/5th inch apart from each other. The portion of the gut fixed should be 1 3/5th inches long and 1.1/5th broad.

At this stage the muscles and the aponeurosis of the abdominal wall are sewn up as far as the opening of the intestine.

It is best to open the intestine in two stages, (at the very earliest after 24 hours), in order to avoid cellulitis of the abdominal wall. It is advisable in these cases to sew the gut to the peritoneum with button sutures, leaving these long and tying them over a strip of iodoform gauze placed around the fixed portion of the intestine. The intestine is then incised with a knife or cautery. The mucous membrane is stitched to the edges of the skin wound. Only at the upper and lower angles of the wound are gaps left for gauze drains, a rubber tube is introduced into the proximal portion of the intestine to carry off the fæces. A thick layer of Zinc-Ointment (Vaseline base) is rubbed over the skin.

If the operation is done in one stage the Parietal Peritoneum should be stitched circularly to the skin (cf. Inguinal Colotomy) in order to avoid infection of the abdominal wall (an infection of peritoneum has not been described). This procedure facilitates the sewing of the gut by *Lembert* sutures to the peritoneum.

Catheterisation of the Enterostomy is often necessary in order to prevent contraction. If necessary, a second operation must be performed. The intestine has to be incised more freely and the mucous membrane has to be stitched once more to the skin. Closure of the Enterostomy, Trusses, etc., are described under Permanent Inguinal Colostomy.

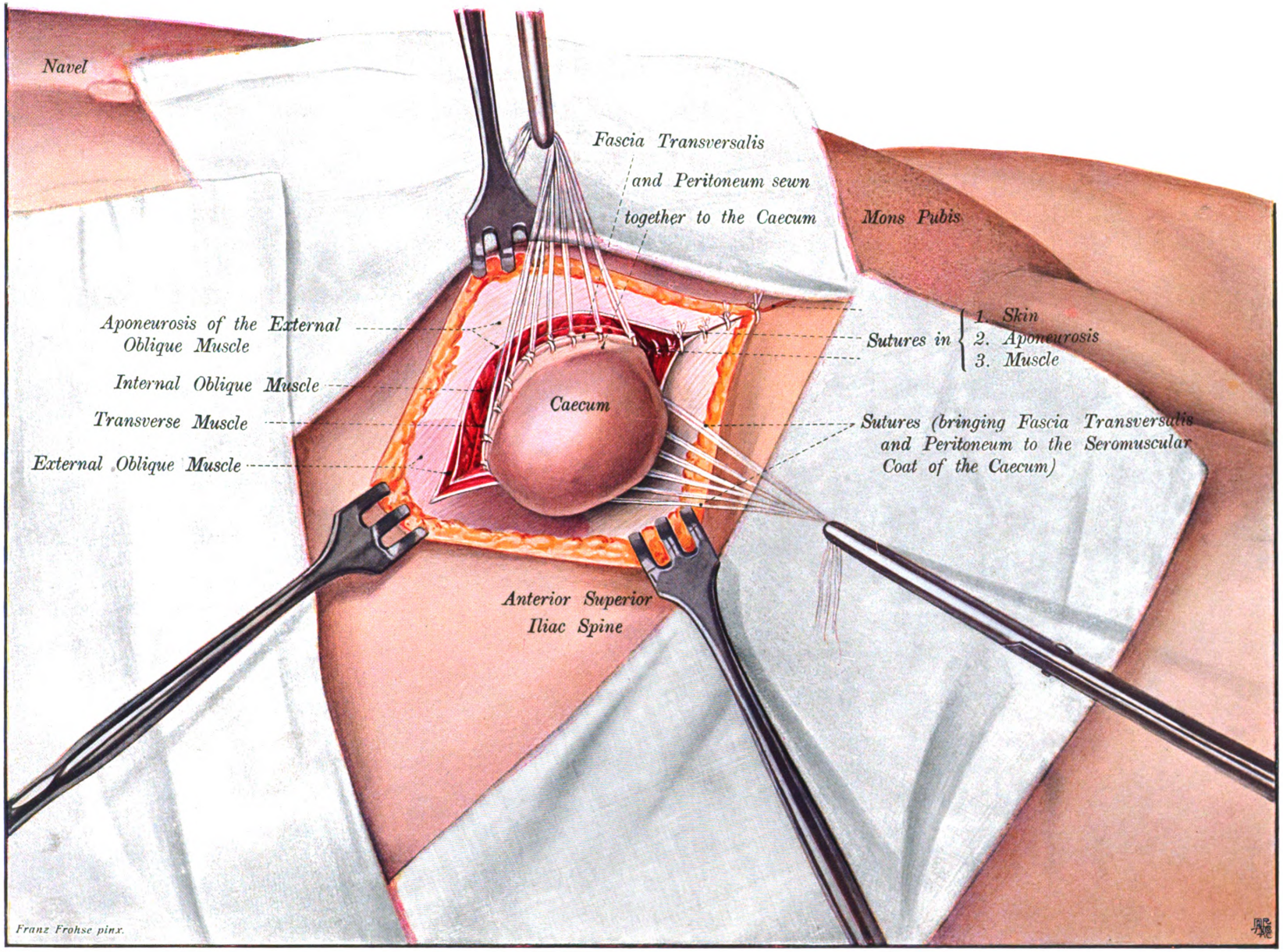

Enterostomy.

Rebman Limited, London.

Rebman Company, New York.

Plate XLIII.

Anterior Gastroenterostomy

Plate XLIII.

Anterior Gastroenterostomy

INSTRUMENTS

Kausch's Stomach Tube

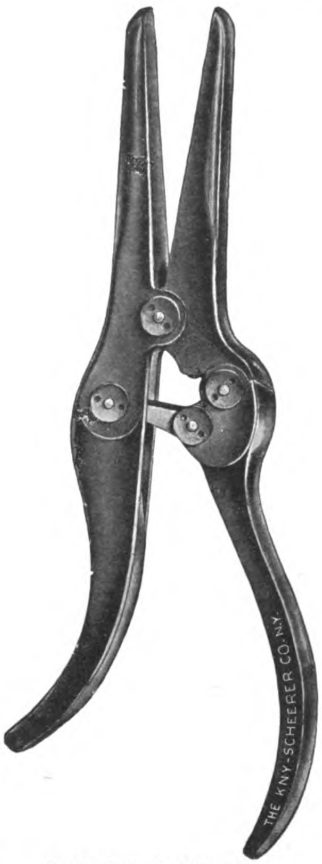

Roux's Stomach Angiostribe.

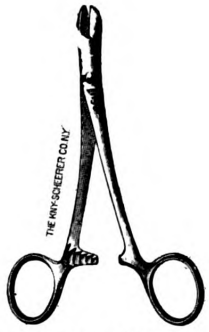

Doyen's Haemostatic Forceps.

Narath's Gastrophore.

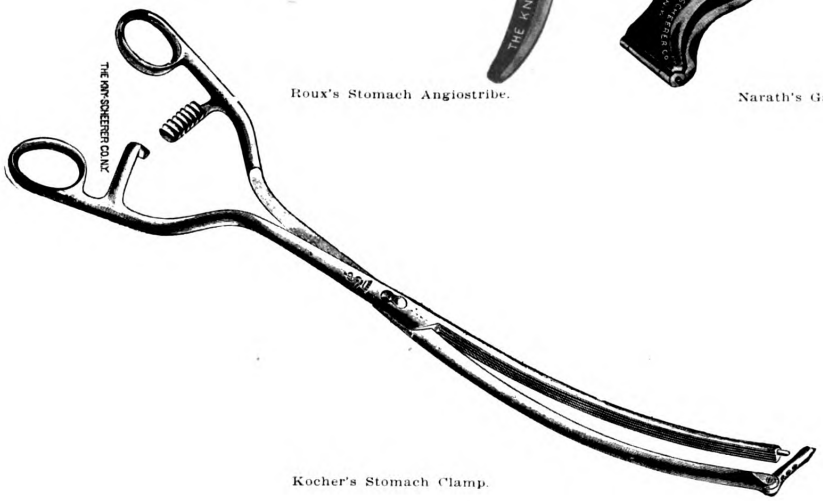

Kocher's Stomach Clamp.

Anterior Gastroenterostomy.

Gastro-Jejunostomy was first performed by *Wolfler* in 1881.

Indications: Gastric Diseases; Stenoses due to Cancer of Stomach (Metastases are no contra-indication), Gastric Ulcer; Strictures of the Pylorus, Hour-glass Contraction of the Stomach, Tumours and Ulcers of the Duodenum.

[Preparation: cf. No. 17.]

Rigorous Asepsis, Gastric Lavage. Introduction of *Kausch's* Stomach Tube (cf. Instruments).

General Anæsthesia; *Schleich's* Local Anæsthesia.

The incision is made in the middle line, beginning at the Xiphoid Cartilage and extending to the Umbilicus or only 2/3rds of this distance.

The abdominal wall is incised; careful Hæmostasis is secured. The skin is covered with sterile towels fixed (with forceps) to the edges of the wound.

A fold of Peritoneum and Fascia Transversalis is lifted up with hooked forceps and opened. When dilated, the Stomach lies well in the wound; it is recognised by the direction of its vessels. When contracted, the organ lies behind the left costal arch, to the left of the Vertebral column.

We will here describe Anterior Gastroenterostomy, the Standard operation in *Bergmann's* Clinique. It is easier to perform than Posterior Gastroenterostomy, which will be described in Plate 49, and gives excellent results.

The anterior wall of the Stomach is held by an assistant, the Transverse Colon and Omentum are thrown upwards so as to expose the Duodeno-jejunal Flexure (cf. Plate 49, Post. Gastroent.) free. It is not necessary that the operator should actually see this flexure. The operator should introduce his hand on the left of the Vertebral Column, and follow the Transverse mesocolon; the fact that the loop cannot be drawn into the wound is evidence that the Jejunum has been secured.

The Jejunum is now followed downwards for 16-20 inches. At this point the anastomosis is made. In our operation a loop of Jejunum is fixed in front of the Transverse colon to the Anterior Wall of the Stomach (2nd method of *Billroth*). The loop should be at a certain distance from the flexure, so as to avoid pressure on the Transverse Colon with resulting obstipation.

Everything (coils of Colon and Small Intestine) is then replaced except the anterior wall of the Stomach and the loop of the Jejunum. These parts are surrounded by gauze outside the wound.

The loop of Jejunum is emptied by digital pressure, and clamped with *Doyen's* clamps, or temporarily ligatured with a silk suture, which is passed through the mesentery at a point where there is no vessel. It is useless to clamp the Stomach, because clamps do not guarantee a safe closure.

The Loop is now fixed to the Anterior Wall of the Stomach by a serous button-suture, or a continuous serous suture (1st Posterior row of sutures—always use silk). The direction of this suture must be oblique, from the left and above running downwards to the right.

The end of this fixation suture should be at a certain distance from the Pylorus and just above the greater curvature. The sutures are passed through the intestinal wall near its mesentery.

The most important point is the "isoperistaltic attachment" of the Jejunum; *i.e.,* the Jejunum must be placed in such a way that the afferent part lies to the left, and upwards. Thus the contents in the stomach and intestine flow in the same direction; therefore, the gastric contents flow readily into the efferent part. The flow of gastric contents into the afferent part ("Vicious Circle," *Mikulicz*) is moreover prevented by the fact that the loop of the Jejunum has been sewn on obliquely, and that the afferent part has been kinked by a suspension suture (*v. Bergmann*).

The anastomosis should be half as long as the serous suture (4 inches), *i.e.,* 2 inches. About 1/10th inch from the serous suture the serous and muscular layers of both Stomach and Intestine are incised right down on to the Mucous layers which are recognised by their rich blood-supply.

The incisions must correspond exactly and be made in such a way that they are overlapped on both sides by the serous suture.

The incised layers of Stomach and Jejunal walls are then united by a 2nd posterior row of sutures (*Lembert's*)—either button sutures or continuous.

This having been done, the mucous membranes lie free 2-3 mm. broad, within.

For Laparotomy, we never use swabs, but towels; these towels are at once clipped in order to prevent them from disappearing in the abdomen.

All towels should be counted.

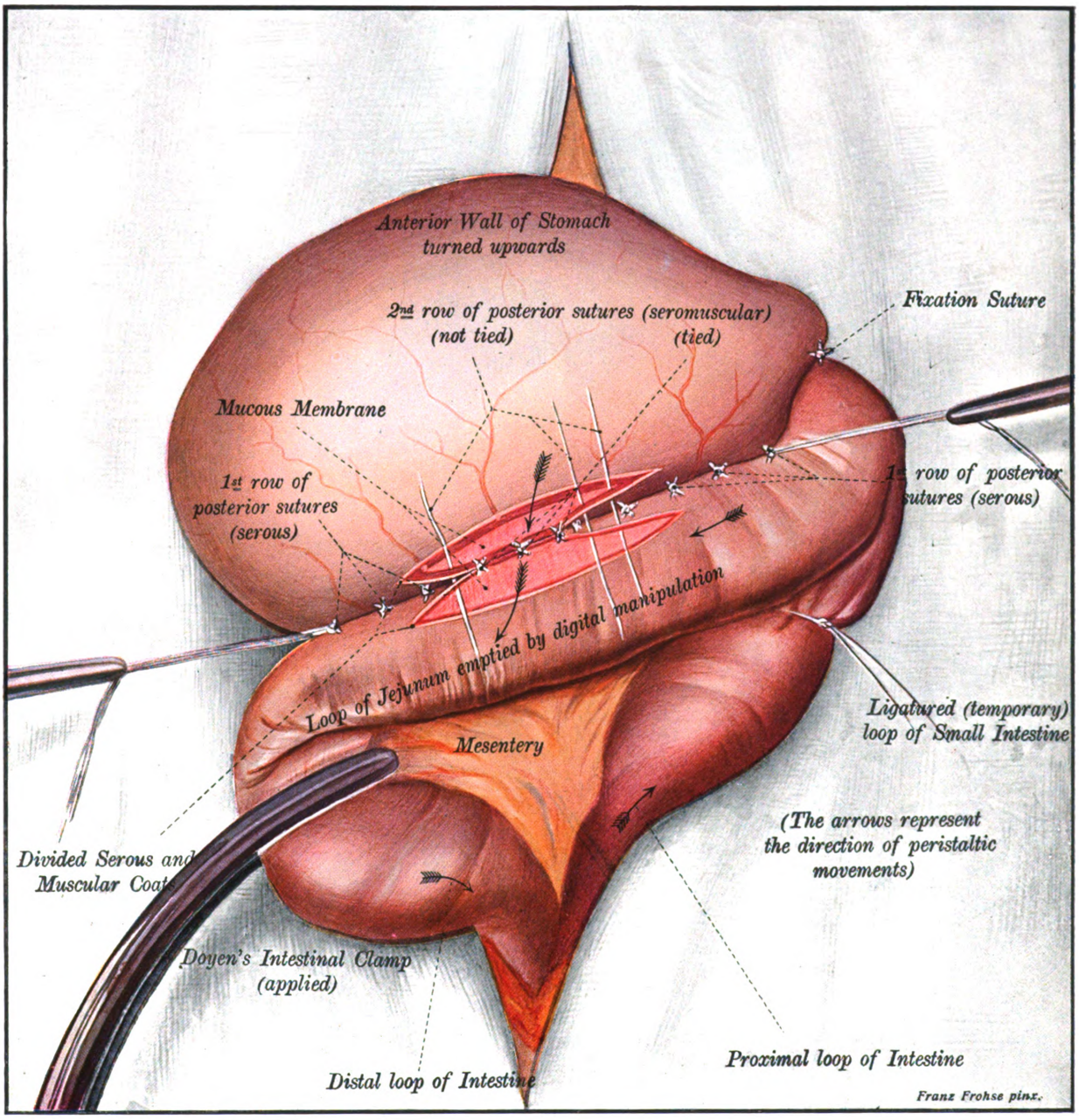

Gastroenterostomy — Anterior Method — Stage 1.

Plate XLIV.

Anterior Gastroenterostomy

Anterior Gastroenterostomy.

STAGE 2.

Before opening the mucous membrane, all vessels which can be seen are clipped and tied with a double ligature.

It is of extreme importance that no contents should pass out from the Stomach or the Intestine when these are opened.

With towels and Iodoform gauze the organs must be well swabbed in the situation of the anastomosis.

The clamps or silk-sutures which have been applied keep the intestine practically empty; it is infinitely more difficult to keep the stomach empty at the seat of the future anastomosis. Clamps are hardly of any use. It is better to get an assistant to compress the anterior and posterior gastric walls together; this manœuvre prevents any gastric contents from escaping.

The "Gastrophor," invented by *Narrat,* is intended to imitate and replace this manipulation. *Lexer's* method is more simple and safe. He puts a suture (cf. figure) at each end of the opening through the serous layer and by means of this pulls the stomach and intestine upwards. This prevents the escape of any contents when the alimentary canal is opened.

The opening is made with a small pointed knife which is pushed in boldly. The incision is enlarged with scissors. All bleeding vessels are ligatured in order to avoid blood from flooding the field of operation.

The upper or gastric edge of the opening and the lower or intestine edge of the opening are drawn forward by forceps. This manipulation further prevents any escape of the contents. Minute pieces of gauze may be placed, temporarily, after swabbing, into the lumen of the intestine.

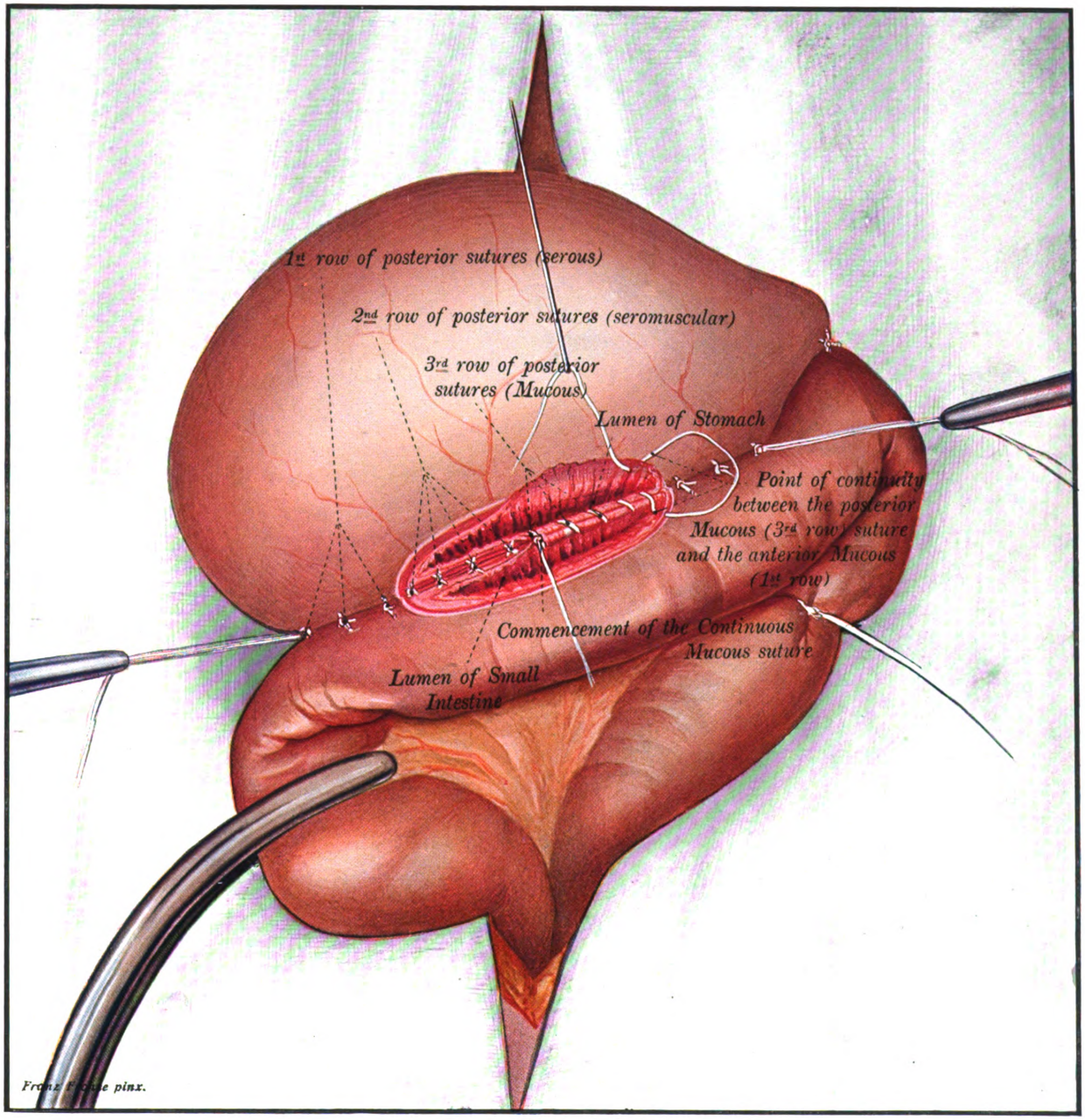

Gastroenterostomy — Anterior Method — Stage 2.

Plate XLV.

Anterior Gastroenterostomy

Plate XLV.

Anterior Gastroenterostomy.

STAGE 3.

The 3rd Posterior Mucous-suture is continued into the 1st Anterior Mucous-suture, and is continued as far as the middle of the communicating opening. A posterior continuous mucous-suture is now commenced in the middle and continued forwards on the other side, until anteriorly and opposite the middle it meets the anterior suture. The ends of these continuous mucous sutures are tied together.

When the continuous suture is employed, the surgeon should take care that the suture is kept tense, and that the stitches are always tightened. After having sewn for a short distance, a retrograde stitch should be made to fix the suture.

Two rows of sutures should be placed over the first anterior row. For the 2nd anterior row either *Lembert* or *Czerny*-suture may be used. We apply a 3rd row of *Lembert* sutures over this second row. The third row may be covered with omentum which is fixed to the serous layer of the stomach by means of sutures.

The method here described takes up much time; we, therefore, mention an excellent method invented by *Lexer* (cf. figure). He begins with the serous suture Ia to the left and above. At its end he ties a knot, but leaves the silk and needle attached (Ib.) He then incises all 3 layers of the Stomach and Intestine. *Lexer's* IIa continuous suture is again commenced at the left and above, and forms first the posterior wall of the anastomosis, stitching together all three layers. Next passing on to the Anterior wall, he allows his needle to enter the Intestinal mucous membrane from within outwards, that of the Stomach from without inwards. When the suture has been finished at the right angle of the wound, only serous and muscular coats are taken into the stitches. On the anterior surface *Lexer* sews from right to left and ties the end of his thread (IIb) to its commencement (IIa). The thread

of the first posterior suture (Ib) is then sewn as a *Lembert*-suture over the anastomosis as far as the beginning (Ia) from right to left, and tied.

This suture can be completed in 10 minutes, which is of great value when the patient is collapsed.

It is difficult to use a button for Gastro-Enterostomy; such requires just as much time. We, therefore, advise against this precedure.

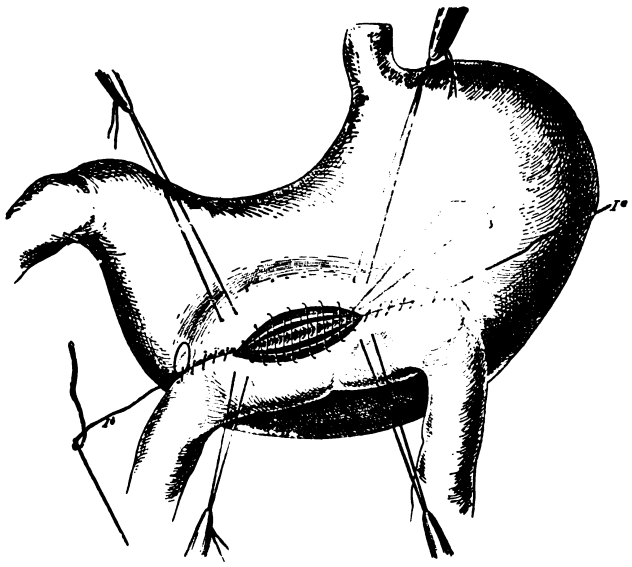

When the anastomosis is finished, the clamps are removed. The alimentary tracts are once more irrigated with normal saline at 38° C. The rows of sutures may be wiped with Iodoform gauze. All towels are removed and counted.

The viscera are now replaced into the Abdominal Cavity. The abdominal walls are sewn up as described under "Resection of Intestine."

A "Vicious Circle" has not yet been observed after our method of operating. Should such a "Vicious Circle" be suspected, the abdomen must be opened immediately, and an Enteroanastomosis between Efferent and Afferent portions of the intestines made (*Braun*).

In cases where a large "Plate Carcinoma" is present and the entire Gastric Wall diseased, Jejunostomy may be necessary. A loop of Jejunum is then drawn through the substance of the Rectus Muscle into a wound made at the outer border of the Rectus and sewn to the edges of the incision analogous to our Gastrostomy operation (cf. fasc. II, No. 17).

The loop of Jejunum is then opened, and the patient fed through this opening.

Heineke advocates Pyloroplasty for benign stenoses. A longtitudinal incision is made at the Pylorus over the stricture and sewn up in such a way that the angle of the wound in the duodenum is joined on to the angle of the wound in the stomach, thus producing a row of sutures directed transversely to the original longtitudinal section.

The operation can be considered nowadays as not dangerous; the results are excellent in cases of benign diseases. In cases of Carcinoma, it does away with the pain and vomiting, and prolongs life.

The sooner the Carcinoma has been recognised, the greater is the chance of finding a movable, operable tumour, for which *Roux* advocates Pylorectomy as the best form of Gastro-enterostomy.

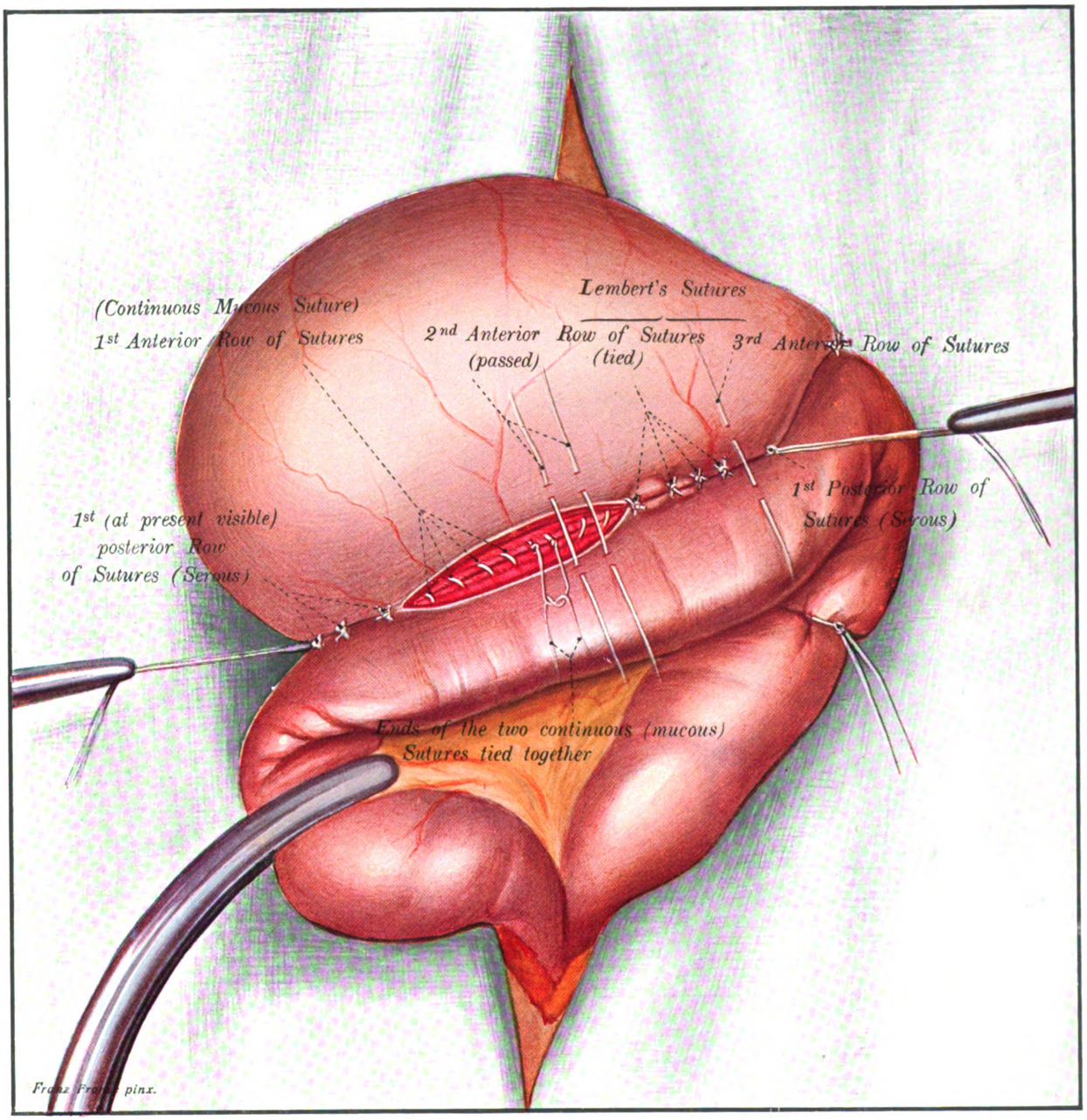

Anterior Gastroenterostomy. — 3rd Stage.

Plate XLVI.

Enterectomy

Plate XLVI.

Enterectomy

INSTRUMENTS



Doyen's Stomach Clamp.

Reverdin's Set of 3 Automatic Needles.

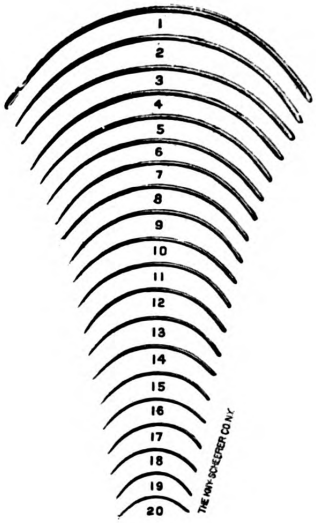

Surgeons' Needles.

Felizet's Perineum Needle.

Abdominal Spatula.



Kny-Scheerer Co.'s Improved Thermo-Cautery.

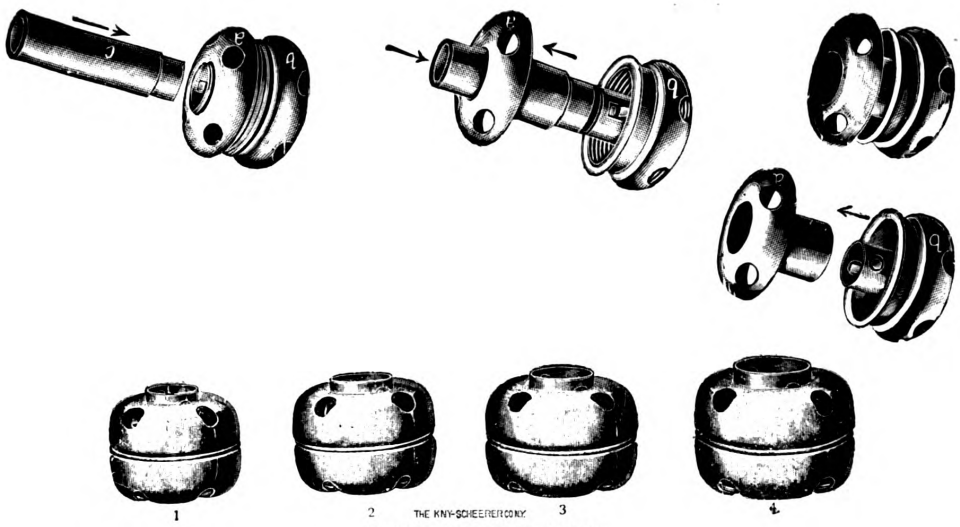

Murphy's Anastomosis Buttons.

Hagedorn's Needle Holder.

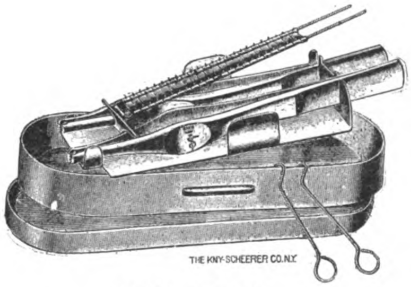

Michel's Suture Set.

Gacz's Canulated Needle.

Frank's Decalcified Anastomosis Buttons.



Mikulicz's Enterotriptor.

Enterectomy.

Resection of Intestine.

STAGE I.

Preparations for Laparotomy, cf. No. 17.

General Anæsthesia. *Schleich's* Local Anæsthesia when the patient is collapsed.

Indications: Intestinal Diseases, Traumatism, Inflammation, Stenosis, Stricture, Volvulus, Intussusception, Incarceration, Foreign Bodies, Adhesions, Closure of a Colotomy (cf. No. 41).

Laparotomy is usually made in the middle line; in all doubtful cases, the median incision is employed. For other cases, incision along the outer border of the Rectus, a transverse, or arched incision with its convexity downwards, in order to avoid the nerves as much as possible.

(For Incarcerated herniæ, followed by Enterectomy, extension of the herniotome incision upwards and backwards.)

Rigorous asepsis during the operation and careful hæmotasis before opening the peritoneal cavity are important.; the skin is covered with towels which are fixed by clips to the edges of the wound (cf. 17 and 42). A fold of Peritoneum is lifted up with 2 hooked-forceps and then incised; the incised peritoneum is clipped.

The portion of gut to be excised is pulled out of the abdomen (often impossible when excising a portion of large intestine). Always excise through healthy parts, even if long pieces of gut must be sacrificed (Resection of as much as 6 feet is possible). The contents of the portion to be excised are squashed out with the fingers, *Doyen's* clamps are applied on either end in order to prevent any contents from flowing into this portion. The mesentery is ligatured 1/10th inch from its attachment to the intestine, along the length of the gut to be excised.

Thrombosis and circulatory disorders in the Mesentery demand excision of the corresponding portion of Intestine. The pulsation in the vessels is therefore observed. The mesentery is ligatured with catgut; these ligatures may be fixed with silk-sutures (cf. Herniotomy). Each successive ligature should include, if possible, a portion of the already ligatured mesentery; accordingly each ligature is passed over its neighbour, *i.e.,* in such a way that the last ligature is further distant from the gut. The Mesentery is divided between the ligatures and the Intestine; a careful inspection is made and any vessels which may bleed are ligatured. The Intestine is next severed between the clamps with straight scissors, more being cut away at the convexity of the intestine, because the mesenteric vessels spread out fanshape towards the convexity. The open lumina of the gut are at once washed with corrosive sublimate 0.5% solution.

If clamps are not employed, a small opening should be made into the mesentery at a spot free from vessels and the intestine should be ligatured with a double temporary silk ligature at either end. The intestine is divided between the double ligatures. It is best to divide with *Doyen's* special broad clamp (cf. No. 30). Mucous and muscular layers pass out of the way, the highly elastic submucous and the serous layer remaining. In the furrow thus produced two ligatures are placed, and between them the intestine is divided with knife or cautery. The stump is then cauterised.

The sutures are made with fine silk, small fine curved needles for the button suture (which is easier) for the more difficult continuous suture a round straight needle (*v. Bergmann*), or lancet-shaped needle for gastric and thick intestinal walls, is used. If there be a scarcity of assistants, the needles should be prepared beforehand. (It is advisable to have *Esmarch's* Intestinal needle case.)

The most important intestinal suture is *Lembert's* (1824) by which the serous layers are invaginated and brought into contact with each other, thus producing firm adhesions (cf. Gastroenterostomy). The needle enters the serous layer, passes through the muscular and again leaves the serous layer. This suture allows broad surfaces of gut to be fixed to one another (cf. Gastroenterostomy).

In order to close a gut lumen by *Lembert* suture (*e.g.,* after removal of a foreign body—incarcerated gall-stone—when a longitudinal incision of 1 inch may be made), the needle should enter the serous layer 1/10th inch from the edge of the incision, and leave it again at a short distance from the edge of the incision; the needle should now be passed across the wound and enter the other side in a similar manner. By tying the ends the edges are invaginated and broad serous surfaces are

brought into contact. The needle should enter longitudinally, *i.e.,* parallel with the axis of the intestine, in order to avoid stenosis.

A circular opening is well closed by an *Albert* or *Czerny*-suture (cf. Gastro-enterostomy).

In the operation of Enterostomy, the divided intestine may be closed by *Albert* sutures, *i.e.,* the needle is passed through Serous, Muscular and Mucous coats on one side and passes through Mucous, Muscular and Serous on the other; the suture should begin at the attachment of the Mesentery and extend down to the convex border of the section. The fact that in the application of this suture stitch-holes are made from the interior of the intestine which pass to the exterior, is of no importance.

Czerny's suture gives a better invagination of the mucous layer (cf. Gastro-enterostomy) because only the serous and muscular layers are taken into the stitches. Over this suture (*Czerny's* or *Albert's*) a second row of *Lembert* sutures must always be placed. Either continuous or button-sutures may be used. *Roux* uses 3 rows of sutures (*Czerny, Lembert, Albert*) in order to obtain a greater apposition of the serous coats (cf. No. 42). We think that this is only indicated when the operation is performed on the large intestine or on inflamed and œdematous gut.

The Intestine divided with scissors is closed as described. Compressed and ligatured stumps are sewn up with a purse-string suture. This suture is made by commencing at the attachment of the mesentery. The needle enters as far as the submucous layer and leaves the gut 1/10th inch distant. This process is repeated until the attachment of the mesentery is again reached. Now a retrograde stitch (*Meyer*) is made; this is to prevent the serous suture from slipping at the attachment of the mesentery. The ends are next tied, the stump being invaginated with forceps. Another (*Lembert*) suture is, however, placed over it.

Instead of making a purse-string and then a *Lembert* suture, 2 *Lembert* sutures may be used.

A purse-string suture is absolutely necessary for *Murphy's* button. In the figure, the male portion has been introduced into the gut lumen, where it is held in position with forceps. The purse-string suture is placed 1/5th inch from the edge of the incision; it must be pulled quite tight, where it retains the button in its place well. Protruding mucous membrane is carefully cut off; at the button, only serous layer should be visible, after the suture has been tightened.

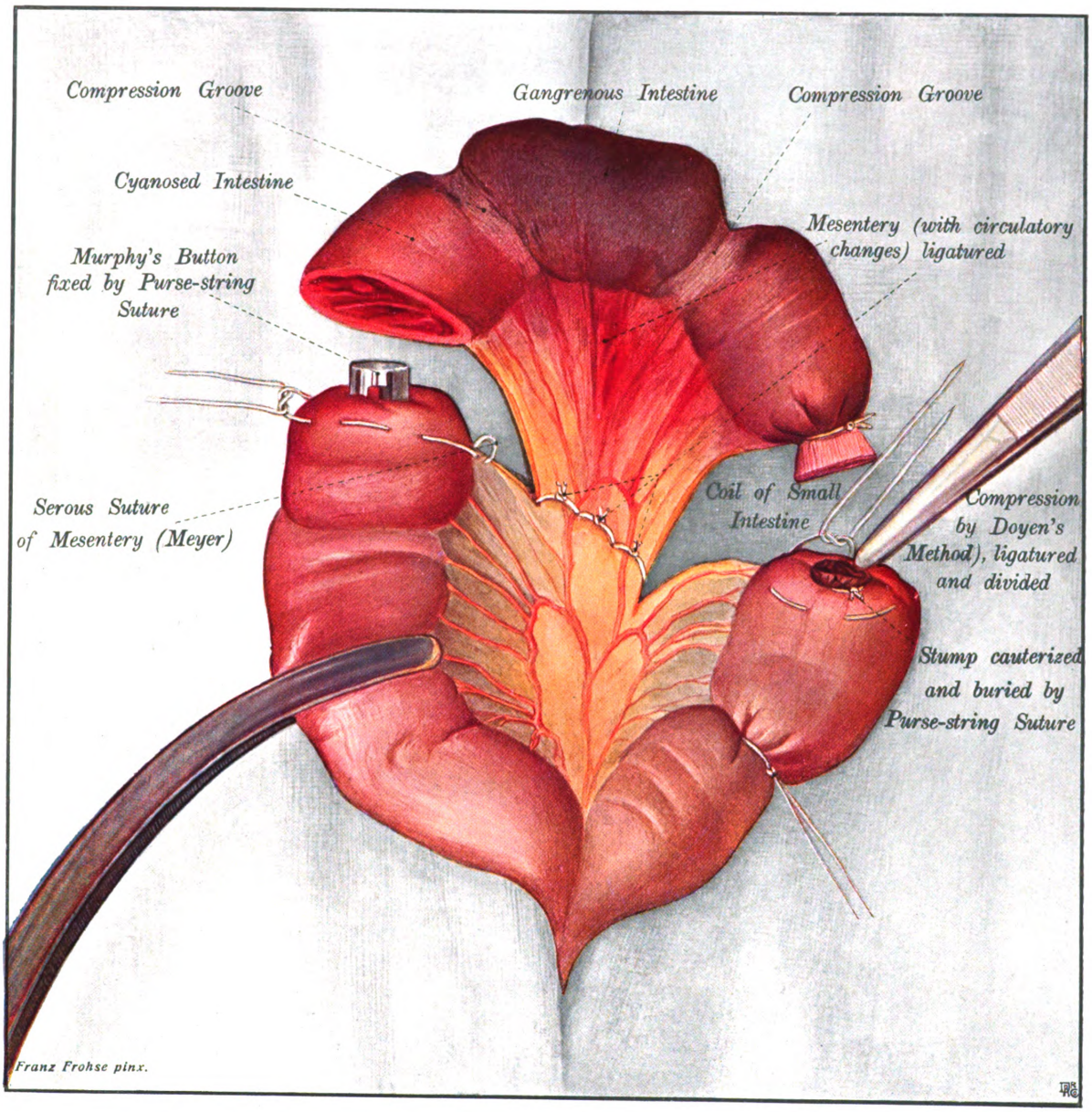

Resection of Intestine. — 1st Stage.

Plate XLVII.

Enterectomy

Enterectomy.

STAGE 2.

The operation described is such as is usually performed in *Bergmann's* Clinique; *i.e.*, both ends of the Intestine are closed and then joined by a lateral enteroanastomosis. Both portions are fixed isoperistaltically (this is, however, not as necessary in this case as in a Gastro-enterostomy) to each other by means of a serous (button or continuous) suture (5 inches long).

The anastomosis is made exactly as in the Gastro-enterostomy operation. The slit in the mesentery is closed after apposition of the 2 coils of gut; we prefer to sew it up in order to prevent loops of intestine from making their way through it.

We have given up the Circular Enterorraphy because the method is more difficult and only possible if the lumina of the 2 ends are of equal size; moreover, stenosis has followed this operation is some cases.

The Implantation-method (to be used between large and small intestine) is described in Fig. 50.

If the patient is very weak, and unable to stand the operation well, we rapidly apply *Murphy's* button, which is the best of such contrivances. It should be well finished and show no sharp edges. For beginners the use of this button is easier than the other method of Intestinal Anastomosis. The disadvantages are possible pressure, gangrene (too early dislodgment of the button before the 8th day) followed by perforation; or it may remain too long (danger of Volvulus) or pass regressively towards the stomach and cause trouble. In Enteroanastomosis joining large intestine together, the button may become obstructed by fæces.

The male portion is put into the efferent end; gravity will then make it pass towards the rectum, where it often lies for weeks (seen with X-rays) and may be removed with an enema.

The female part is fixed in a similar way (cf. Stage 1). Both are then pressed together, care being taken to press only on the outer round edges (pressure on the inner sharp ones may produce necrosis) (cf. Figure). The male portion has a movable

cylinder with a spring which presses on the inverted intestine and thus brings about its necrosis. The button can then pass on. The openings on the rounded edges are designed to afford passage to the secretions of the necrosis-portion of the gut. Union by suture is necessary after the button has been pressed together, but one may pass a few *Lembert* sutures, especially at the insertion of the mesentery.

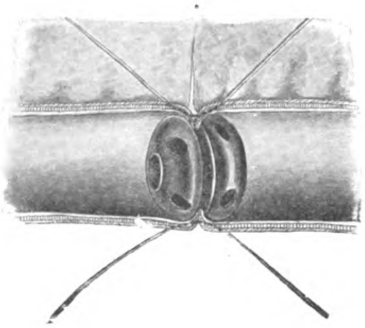

The button can also be used for Lateral Enteroanastomosis. An incision 2/3rds of the length of the button is made, the button is introduced and fixed with a purse-string suture. A lateral anastomosis on the large intestine should *not* be made by means of a button.

It may be necessary to do an anastomosis when it is impossible to remove the intervening diseased portion. In cases of Intussusception traction should never be exerted on the invaginated portion, but endeavour to free this portion should be carried out by squeezing the invaginating part. Enteropexy has been suggested as a means of preventing a recurrence of intussusception. The part of the intestine in question is fixed to the anterior abdominal wall. Intussusception is often brought about by a tumour which should be excised.

Should the gut be much distended (*e.g.* Atony) after the Anastomosis, it may be punctured and a rubber tube inserted. The puncture is then closed by transverse sutures.

Should there be any doubt as to the reliability of the sutures, a gauze-drain is placed around it (*v. Bergmann*). This is also to be recommended when a button has been used. If perforation occurs, the peritonitis would, by this means, be localised.

Whenever possible drainage should be avoided, because healing is hindered and adhesions are favoured. During the operation the intestine should be constantly irrigated with warm saline solution and covered with towels to prevent it from becoming cold; it is thoroughly irrigated before being put back into the abdomen. The sutures are wiped with Iodoform gauze, and all towels removed.

The abdomen may be closed by several layers of sutures; one catgut suture for the Peritoneum, one for the muscles (either button or continuous), and a silk-suture for the skin.

The following procedure in sewing may be employed: *Felicet's* Mounted-

Needle is passed through the skin, Muscles and Peritoneum; here it is threaded and withdrawn. These sutures are left untied. Between them the Peritoneum and Fascia Transversalis are sewn up with catgut; next the muscles are sewn in a similar way. The chief sutures are now tied, and the skin united by a few superficial sutures. The gauze-drain, if any, is allowed to hang out at one end. Careful suturing is necessary in order to prevent ventral herniæ. If everything goes well, no bandage (belt) is required; if drainage has been employed a belt is advisable. In cases of suppuration, it may become necessary to reopen the wound. Atony, which is not produced by food or medicine, demands a temporary enterostomy.

As starvation diminishes the vitality of the patient, he is fed on the first day with normal saline by the mouth, nutritive enemata and Somatose.*

According to the particular case, Gastric lavage, insertion of tube into Rectum, ice bag on abdomen, etc., should be employed.

In the first 2 days saline enemata, if required; on the 4th, 5th and 6th none, because these are the days of greatest danger of a perforation (*Chlunsky*). After 10 days the patient is out of danger, and may eat soft food.

The stitches are removed on the 14th day, if the stitch-holes are not inflamed.

---

* Within a few hours after such an operation I have found the administration by the mouth of Sanatogen—a milk-food combined with Glycerophosphates—is not only well-borne but considerably aids the patient during the period of reaction following the shock from the operation.—J. Howell Evans.

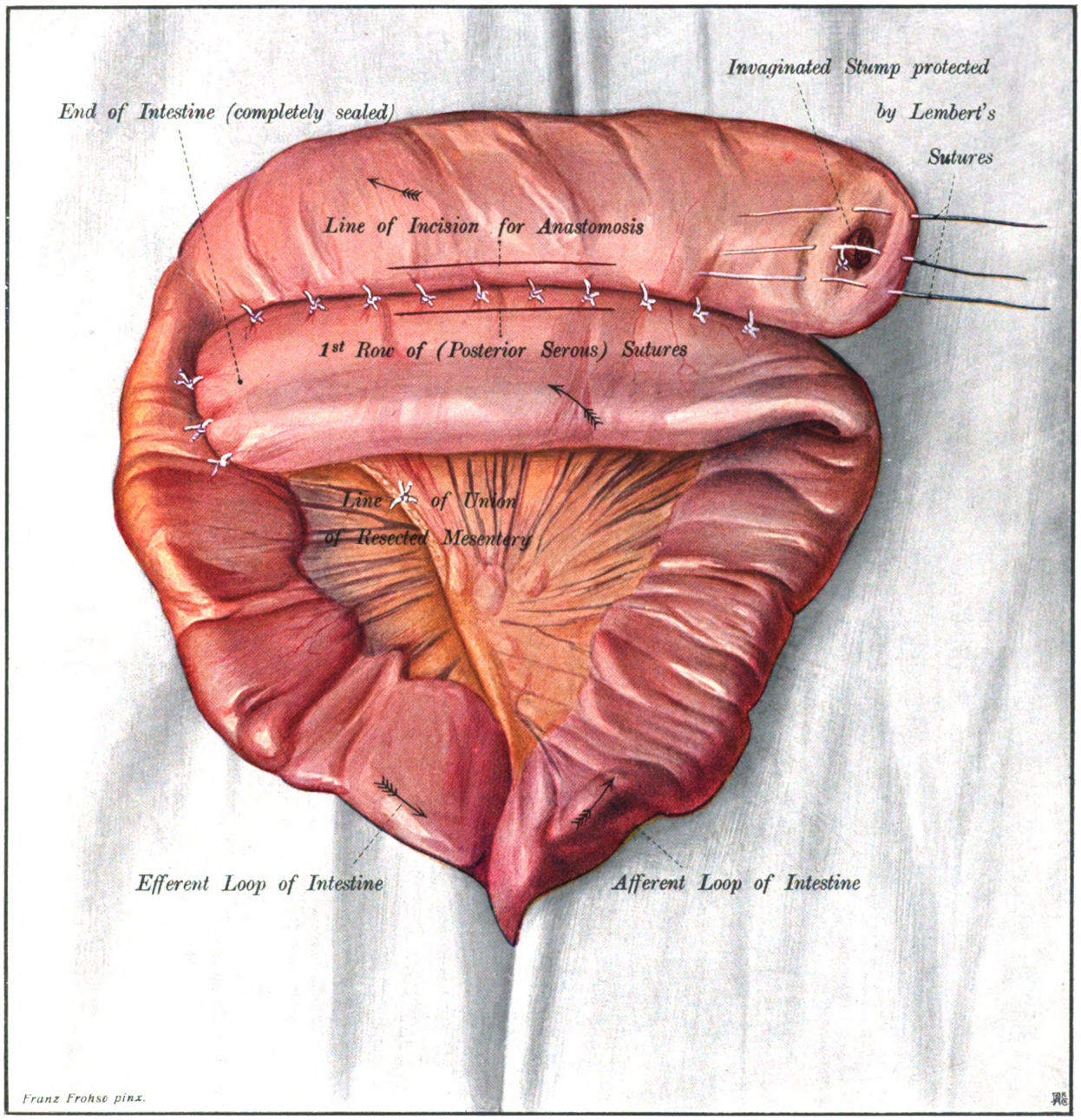

Resection of Intestine. — 2nd Stage.

Plate XLVIII.

Pericardiotomy

Pericardiotomy.

General Anæsthesia; Cloroform or Ether.

As Pneumo-thorax may occur during the operation, or may have been present before, the operation can be carried out in *Sauerbruch's* Chamber (negative pressure) or in *Bauer's* Apparatus (increased pressure). Both prevent the collapse of the lungs and thus of the heart.

But, as the Pneumo-thorax is usually slight, it is sufficient to fix the edges of the lungs to the soft parts (cf. No. 33) or to press iodoform-gauze into the hole in the costal pleura.

Puncture of the Pericardium is only performed for diagnostic purposes, in the 6th left interspace close to the border of the sternum, with a trocar which is pushed in from below upwards, with an aspirator attached.

Indications for Pericardiotomy: Serous, Bloody, and Purulent Effusions: Injuries to the heart (Foreign bodies). For effusions excision of the 5th and 6th costal cartilages is sufficient. Small foreign bodies (needles, etc.) can be extracted at once. In cases of injury one may simply track up the wound, enlarge and remove, temporarily or permanently, the part of bone which obstructs one's progress (*M. Borchardt*). It should be mentioned that foreign bodies may not give rise to any trouble.

Operation is only justifiable when severe symptoms are present (dyspnœa, cyanosis, compression of the heart by a bloody effusion).

In severe cases, death occurs almost immediately after the injury. The subacute cases, however, in which the patient faints, and then recovers consciousness to faint again, etc., demand surgical treatment. Even 48 hours after the injury a successful operation has been performed.

As the Pleura is, in the majority of such cases, injured owing to the varying extent of the left pleura, and as there is a considerable liability to its injury in the course of the operation, we prefer *Rotter's* method,—opening the plural cavity.

The incision begins 3/5th inch from the border of the Sternum, and follows the lower borders of the 3rd and 5th ribs for a distance of 3-4 inches. The ends of this incision are joined by a vertical incision inside the Mammary Line.

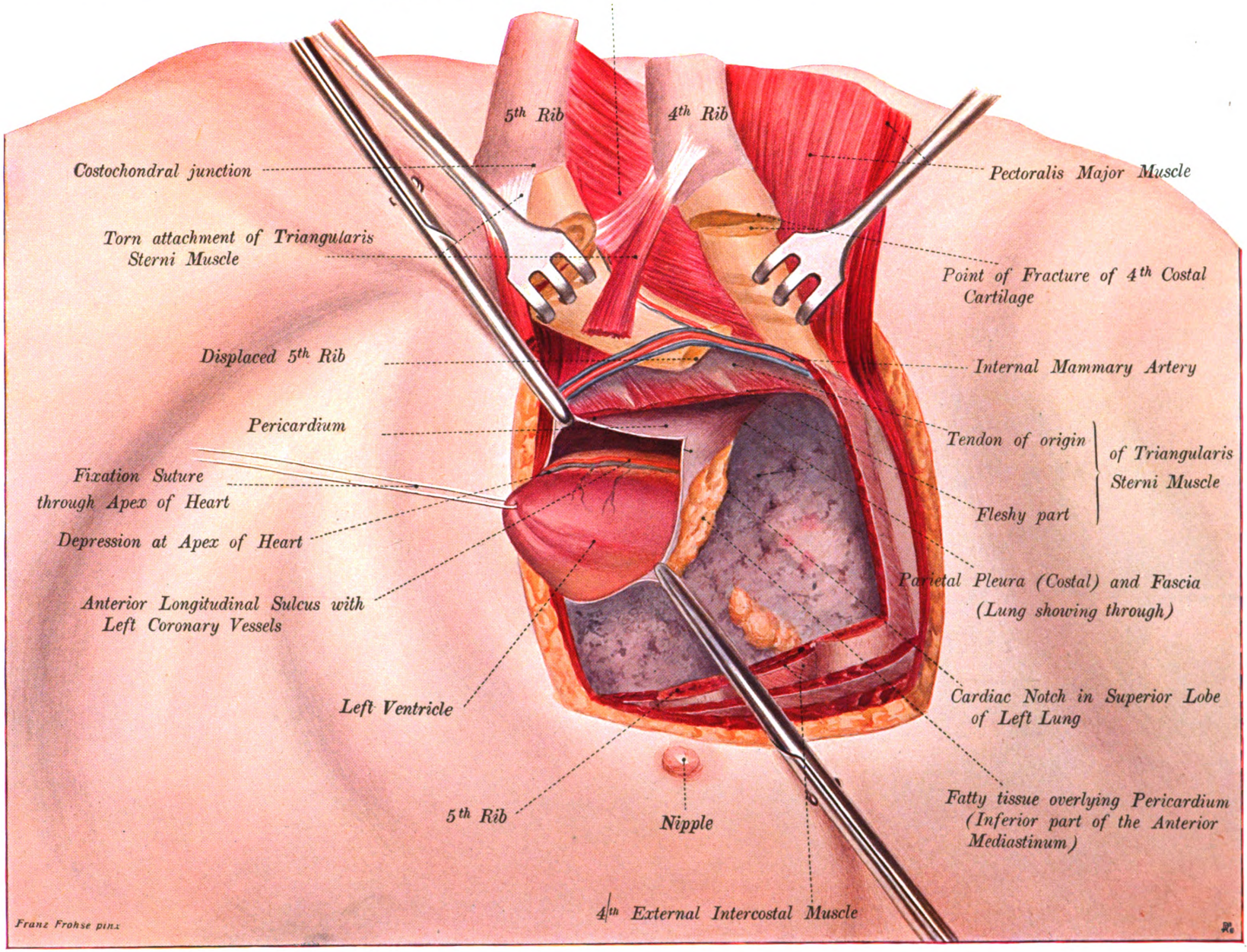

Pericardiotomy.

Tuffier exposed the heart and performed massage in cases of collapse during anæsthesia; the result was bad. *Brauer* has indicated cardiolysis for those cases of Mediastinal-Pericarditis where there is an extensive systolic drawing-in of the thorax. The operation consists in resection of 2-3 ribs near the left border of the Sternum, in order to ease the heart. *Paterson* performs, in addition to this, a partial longitudinal resection of the Sternum.

The periosteum of the bones removed has to be excised carefully, in order to prevent the formation of new bones, which would otherwise occur. The success of this operation is doubtful. The breaking down of internal pericardial adhesions with the hand (adhesions between heart and pericardium) after exposure of the heart, as practised by *Delorme,* has so far never been successful.

Plate XLIX.

Posterior Gastro-Enterostomy

Posterior Gastro-Enterostomy.

A communication between the Intestine and Posterior Wall of the Stomach, behind the Tranverse Colon meets the same indications as an Anterior Gastro-Enterostomy. (Cf. 17 and 34.)

The main object of this operation, first adopted by *Von Hacker,* is to avoid compression of the Transverse Colon by the Loop of Jejunum—a disadvantage which has been known to follow Anterior Gastro-enterostomy. It has been asserted that adhesions are less liable to occur by the posterior route. Furthermore, the opening being made in the Posterior Wall of the Stomach, the gastric contents flow with greater ease into the Jejunum, even when the patient is lying in bed.

The Abdominal Cavity having been opened in the usual way, the Great Omentum is sought and thrown upwards, pulling the Tranverse Colon with it. The Tranverse Colon is thus stretched so that it becomes distinct from its root to its Colic attachment, in this way the large Colic Vessels are visible and can be avoided during the subsequent operative procedure. The Meso-Colon is now divided and drawn apart in all directions.

The divided Meso-Colon is fixed to the Posterior Wall of the Stomach, which is now sufficiently exposed, by 4 silk sutures (seromuscular).

By throwing upwards the Great Omentum the Duodeno-jejunal Flexure is brought into view. In some cases the Duodeno-jejunal Fossa, of great importance in certain varieties of Internal Herniæ, is also seen. But owing to considerable variations the operator frequently has to push coils of Small Intestine to the right side before finding the Duodeno-jejunal Fossa.

For Posterior Gastro-enterostomy the Duodeno-jejunal Flexure only need be sought. The commencement of the Jejunum is the part employed in the Anastomosis, *i.e.*, a small loop, about 4 inches distal to the Flexure; this is so situated that

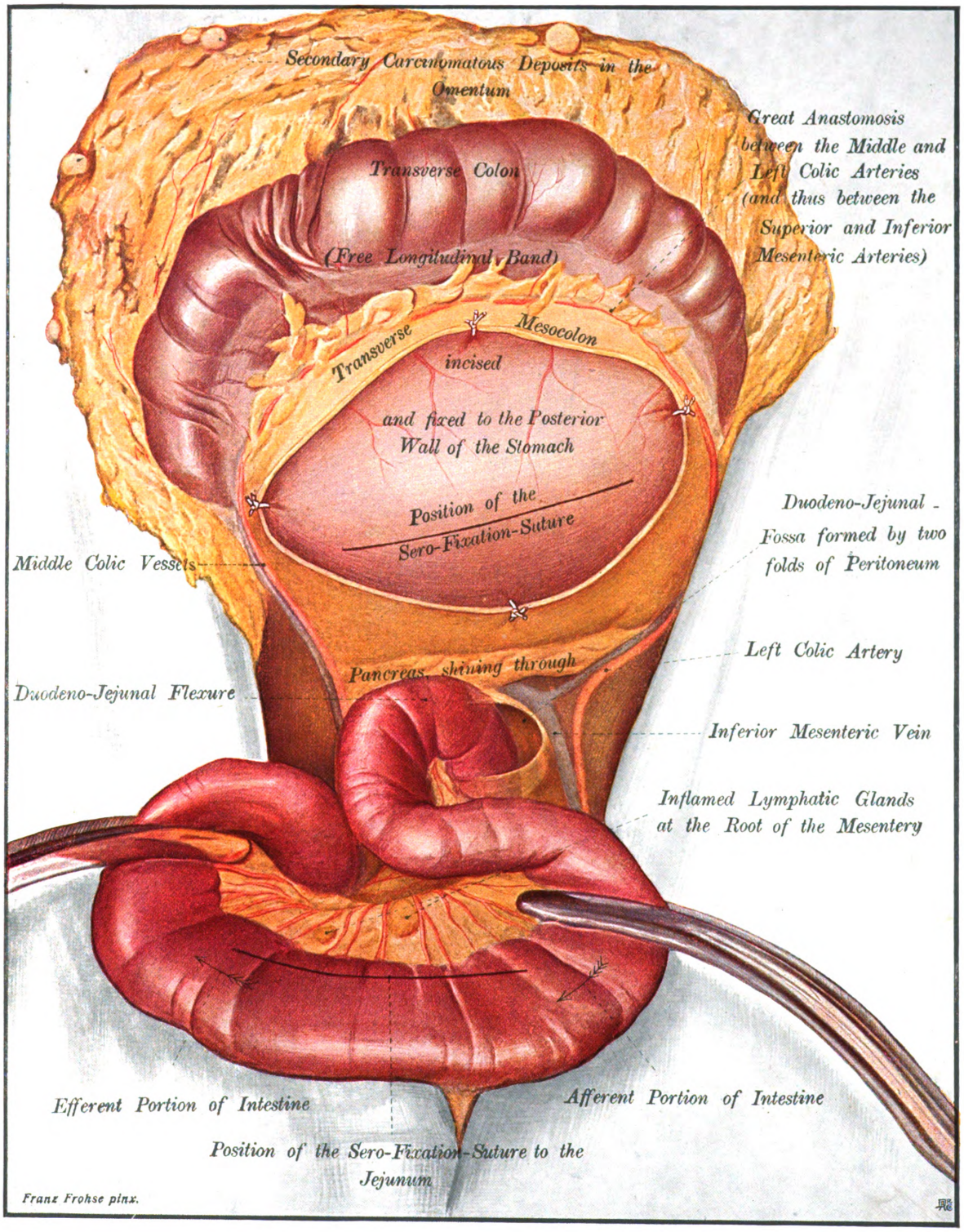

Posterior Gastro-Enterostomy.

after the establishment of the short-circuit there is neither stretching (loop too short) nor sagging (loop too long) of the Jejunum.

The Loop of Jejunum being held in the usual way by *Doyen's* Clamp is fixed on to the Posterior Wall of the Stomach. The first fixation-suture for the Intestine (serous suture) is placed as near as possible to the Mesentery, for the Stomach above the Greater Curvature as near as possible to the Pylorus (cf. Plate).

In this method, as in the Anterior Operation, the Intestine is attached in an *Isoperistaltic* manner to the Stomach, also in an oblique plane, *i.e.,* from the left obliquely downwards to the right (cf. 43).

Fixation having been procured by means of the Serous Sutures the Anastomosis is carried out as in the other operation, *i.e.,* by means of 3 posterior and 3 anterior rows of sutures or, according to *Lexer,* by means of 2 posterior and 2 anterior rows of sutures.

When the Anastomosis is complete the Omentum is returned and may even be stitched over the site of the anastomosis with silk-sutures.

The employment of *Murphy's* Button is as follows: A purse-string suture is passed through the Serous and Muscular Coats of the Stomach, a small opening is carefully made within this suture and the female portion of the button introduced into the opening. The purse-string is drawn taut and any protruding mucous membrane cut off. In a similar manner a purse-string suture is passed through the Serous and Muscular Coats of the Jejunum, this is opened; the male portion of the button is introduced and fastened. The two portions of the button are pressed together and a few serous sutures are passed between the Stomach and Intestine.

In our opinion the suture is the safer: we would reserve the Button for operations of extreme urgency, carried out by the Anterior route. The Abdominal Cavity is closed, as described in No. 47.

Plate L.

End-to-Side Anastomosis

End-to-Side Anastomosis.

End-to-Side Anastomosis or Lateral Implantation is in mimicry of the Ileo-cæcal Junction and is, likewise, carried out between a portion of the Small Intestine and a portion of the Colon.

Preparation for a Laparotomy (cf. 17 and 43).

Indications: Tumours of the Colon: (Ileocæcal Region, Hepatic and Splenic Flexures.) Tuberculosis: Chronic Appendicitis with Stenosis, and Sutures as the result of post-operative adhesions.

Tumours of the Small Intestine are treated by Resection of the gut, followed by Lateral Entero-anastomosis (cf. 46) (Lateral Apposition). But this procedure is frequently inapplicable, owing to extensive adhesions, when the Large Intestine is the seat of a tumour.

In many cases the tumour may be circumvented, by a lateral Anastomosis between the portion of the gut proximal to the tumour and the portion distal to the mass, in the usual way (Small Intestine and Colon, or Two portions of the Colon).

The unilateral method demonstrated in the figure, in which a tumour of the Cæcum is supposed to be present, has many advantages over Entero-anastomosis, *i.e.*, the absence of disorders in the passage of fæces, impossibility of fæces coming into contact with the diseased parts, production of healthy channels for the fæces. In this way the diseased parts are less irritated and, in many cases, the progress of the growth of the tumour is less rapid.

This method is, however, difficult and necessitates considerable time, so that Lateral Anastomosis should be selected in Tuberculosis.

In Malignant Tumours, Lateral Anastomosis may also be performed prior to the Radical Operation for Extirpation: even in these cases, the Unilateral or Bi-

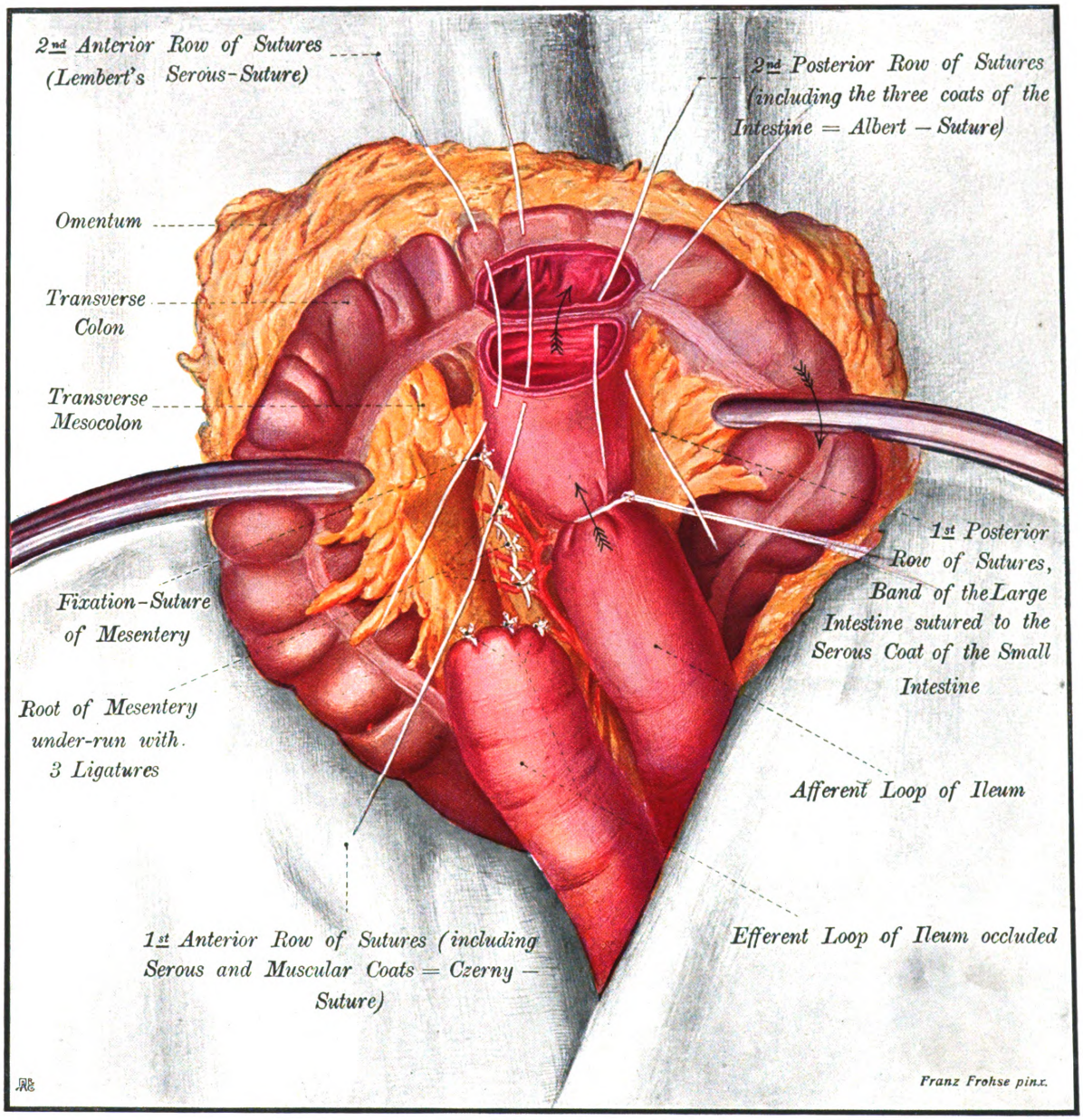

Lateral Implantation.

lateral Method seems preferable if total removal was not possible at the first operation. In the Plate, the Ileum has been dvided by means of *Doyen's* Clamp close to the Ileocæcal Junction, the end leading to the Cæcum (Tumour) has been closed by a purse-string suture and an over-lying serous suture (cf. 46). The efferent portion (ligatured at the clamp-groove in order to prevent the escape of fæces during the Operation) is now reopened by a transverse incision.

The open loop of the Small Intestine is next placed at right angles to the Colon at the point selected for the Anastomosis (Transverse Colon in the Plate), and the Mesentery fixed to the Mesocolon by a few sutures. The Small Intestine is now fixed, on either side of the Mesentery, to the Colon in such a way that half of the circumference of the Small Intestine is stitched to the Colon by Serous Sutures—1st posterior row—(Button-hole or Continuous Sutures may be used). This Continuous Serous Suture may be left in order that it may be continued later as an Anterior Serous Suture (cf. 45), so that the Ileum may be attached to the Transverse Colon in the way described. Great care must be taken so as not to cut across the Ileum too near the Cæcum. The 2nd posterior row of Sutures is passed through all three layers (Mucous, Muscular and Serous of the Colon, Serous, Muscular and Mucous of the Ileum) of the Intestine either as Button-hole or as Continuous Sutures after the Colon has been opened 1/5 inch above the first row of Sutures corresponding with the opening in the Small Intestine. The 1st Anterior Row may be continued from the 2nd Posterior Row by the same thread if the continuous Suture is employed, great care having been exercised in connection with the corners (cf. 45).

It is advisable to employ a Sero-Muscular Suture inasmuch as the better invagination of the mucous surface is hereby ensured.

Lastly, a 2nd Anterior row is passed by means of the continuation of the 1st Posterior Row of Serous Sutures.

In Lateral Implantation, as in all other forms of Entero-Anastomosis, it is important to appose broad serous surfaces.

A Lateral Anastomosis of Ileum and Colon could have replaced Lateral Im-

plantation in this instance. For Bilateral Anastomosis the colon is clamped distal to the Tumour, then ligatured and sutured in layers like the Small Intestine.

Both ends can only be closed if it is possible at a later period (Secondary Operation) to remove the occluded portion or if an external fistula is present. In other cases only the proximal end is sealed, while the distal end is sewn to the Abdominal Wall (cf. Colostomy). Through this opening the diseased gut may be irrigated.

Circular Entero-Anastomosis is condemned on the ground of insecurity when connecting two portions of the Small Intestine, an impossibility when uniting the Small and Large Intestines. *Murphy's* Button is not recommended in the Colon where the hardened Fæces may cause obstruction.

When Small Circumscribed Tumours occur at the Hepatic and Splenic Flexures, resection is often possible, *i.e.,* after excision of the Tumour, both ends of the Colon are closed and Lateral Anastomosis performed. The Abdomen is then closed in the usual way.

Plates LI. and LII.

Operations on the Rectum

Plate LI. and LII.

Operations on the Rectum

INSTRUMENTS.

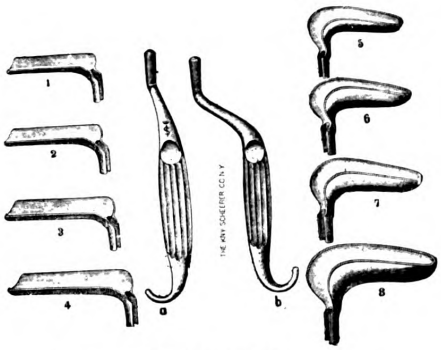

Bozeman's Set of Vaginal Specula.

Ricord's Rectal Speculum.

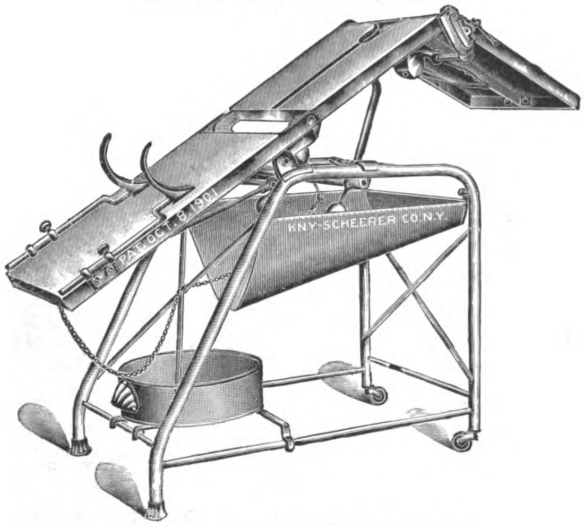

Cornell Operating Table, Showing Trendelenburg Position.

Pleniazeck's Tracheal Speculum for Children.

Conical Rectal Bougie.

Langenbeck's Haemorrhoidal Clamp.

Sims' Rectal Speculum.

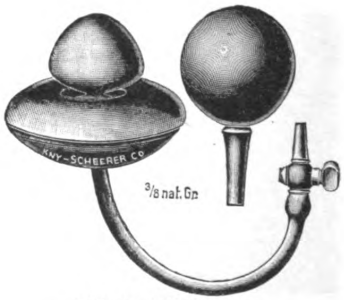

Pad for Artificial Anus.

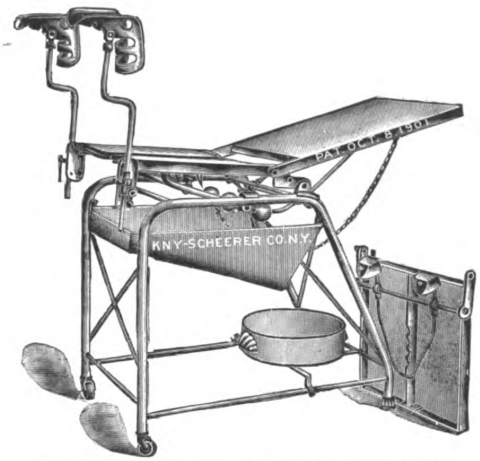

Cornell Operating Tables with Bierhof's Knee Crutches.

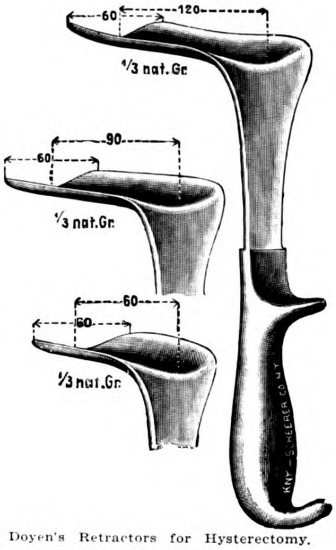

Doyen's Retractors for Hysterectomy.



Cylindrical Rectal Bougie.

Kelly's Proctoscopic Tube.

Haemorrhoidal Plug.

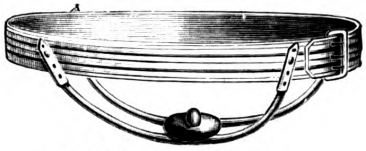

Supporter for Artificial Anus.

Sims' Vaginal Speculum.



Weiss' Rectal Speculum.

Bodenhamer's Rectal Speculum.

Operations on the Rectum.

Imperforate Anus in the New-born demands immediate operation. The operation differs with the variety of occlusion; if there is no external evidence of an Anus, the Perinæum is incised along the middle raphe and the Rectum is reached by blunt dissection. When this has been accomplished the gut is opened and the edges of the mucous membrane stitched to the skin. In some cases removal of the Coccyx may be necessary. A Catheter should be passed into the Bladder, inasmuch as it serves to be a useful guide and a signal against danger to the Urogenital Organs.

If, even after passing into *Douglas'* Pouch, the Rectum cannot be drawn downwards sufficiently, a Left Inguinal Colostomy should be performed.

In adults the following affections demand consideration: Foreign Bodies (Pieces of glass, *Murphy's* Button, etc.). Never try to crush a foreign body in the Rectum, but remove it entire by *Klysma,* by the Finger, by forceps, or with a scoop. An anæsthetic should be administered as it becomes necessary when a further operation is needed, *e.g.* Posterior Division of the Sphincter; Exposure of the Rectum by an incision carried backwards in the middle line as far as the Coccyx, or it may be required further, *i.e.,* Paracoccygeal or even Parasacral.

Fissure in Ano will only heal when division of the External Sphincter is performed.

Fistulæ, if External or Complete, should be thoroughly explored as far as the Rectum; starting at the Rectum all the soft parts down to the introduced director should be divided by a cautery. The External and Internal Sphincters are in this way divided. Internal Fistulæ can generally be extirpated by a long para-anal incision.

Hæmorrhoids are seized by forceps along an axis radial to the Anus. The mass is then completely cauterised (without any previous cutting) so as to produce complete thrombosis and ensure against Secondary Hæmorrhage; or the Hæmorrhoid may be excised and the mucous membrane sewn up by fine resistent-catgut.

Paraproctitic and Periproctitic (Ischio-Rectal and Peri-Rectal) abscesses should be opened by long incisions parallel with the middle-line.

Strictures may be treated by dilatation with suitable bougies; but in bad cases, resection of the affected portion must be considered. Prolapse of the Rectum which is of frequent occurrence in children almost always returns spontaneously and few cases remain uncured by Rest and Aperients. However, if the Prolapse be extensive and defy simple methods of treatment, then Excision, Cauterisation or Resection *Mikulicz*) may be needed. *König's* operation of Rectopexy is recommended: in this operation the Rectum is exposed by an incision extending from the Anus to the Coccyx and fixed by sutures to the Coccyx.

Polypi can usually be twisted or excised through a Speculum; the wound in the latter case is sewn up.

Extensive Polyposis may even require a Right Inguinal Colostomy especially when the Colon is implicated.

In Tumours (Carcinoma and Sarcoma), Obstinate Tuberculosis, Gonorrhœal or Syphilitic Lesions, Excision or Resection of the Rectum requires the surgeon's careful consideration.

Tumours of the Pelvic portion of the Colon can be readily felt when the abdominal walls are relaxed.

In all cases of suspected rectal disease, a careful digital examination (the finger being protected by a rubber finger-stall) should be made when an anæsthetic should be administered, if necessary, to allow of a satisfactory diagnosis being made.

Rectoscopy, for which *Simon's* or *Sims'* Speculum, or *Kelly's* Protoscope (fitted with a *Kasper's* lamp and constructed on the same principle of the Oesophagoscope), is, therefore, only necessary in a few cases.

If such is possible the External and Internal Sphincters should be preserved.

For all Tumours which are 1.1/2 inches above the Anus Resection of the Rectum is therefore performed. (Cf. Plate.)

Resection of the Rectum, after Schlange.

STAGE I.

Preparations: The patient should be gently purged for 8 days. *Schlange* recommends a Left Inguinal Colostomy 8 days prior to the operation.

Anæsthesia: Lumbar Anæsthesia is certainly preferable, because it practically obviates operation-shock: otherwise Chloroform and Ether: *Roth-Dräger's* apparatus.

Indications—Tumours—vide supra.

Contra-indications: 1. Immobility of the Tumour.
2. Implication of Neighbouring Organs.
3. Metastatic Growths.

Position: Pelvis raised on a *Trendelenburg* Table. The Anus, Coccyx and Sacrum must be freely accessible; this is attained by lowering the upper half of the back and flexing the legs upon the Abdomen. A Catheter is passed into the Bladder.

The Osteoplastic Resection of the Rectum is commenced with *Schlange's* incision.

At the level of the 3rd or 4th Posterior Sacral Foramina a transverse incision is carried down to the bone across its entire width. From either extremity of this transverse incision a longitudinal incision is carried towards the Tuberosity of the Ischium, ending opposite the middle of the Anus (cf. Fig. 4). These lateral incisions are towards their lower ends only carried through skin and superficial fascia, but in their upper portions they extend through the Gluteus Maximus Muscle and Ischio-Rectal Fat.

In all cases we strongly recommend a transverse division of the Sacrum because this appears to be the only way whereby the operation can be thorough and all diseased tissue removed. The Gluteus Maximus Muscle and the Sacro-Sciatic Ligaments are, therefore, divided close to the Sacrum.

By means of the finger or an elevator the Præsacral connective tissue is pushed forwards and a wire saw passed. The Sacrum is now sawn through at a level corresponding to the level of the growth; if the tumour is high up the saw-line is between the 3rd and 4th Sacral Foramina; if lower down, then between the 4th and 5th Foramina. No great injury results from this division because the Dural Sac terminates opposite the 2nd Sacral Segment, and the small nerves divided are of minor importance. Moreover, by this open method, Hæmorrhage from the Middle and Lateral Sacral Arteries is easily checked.

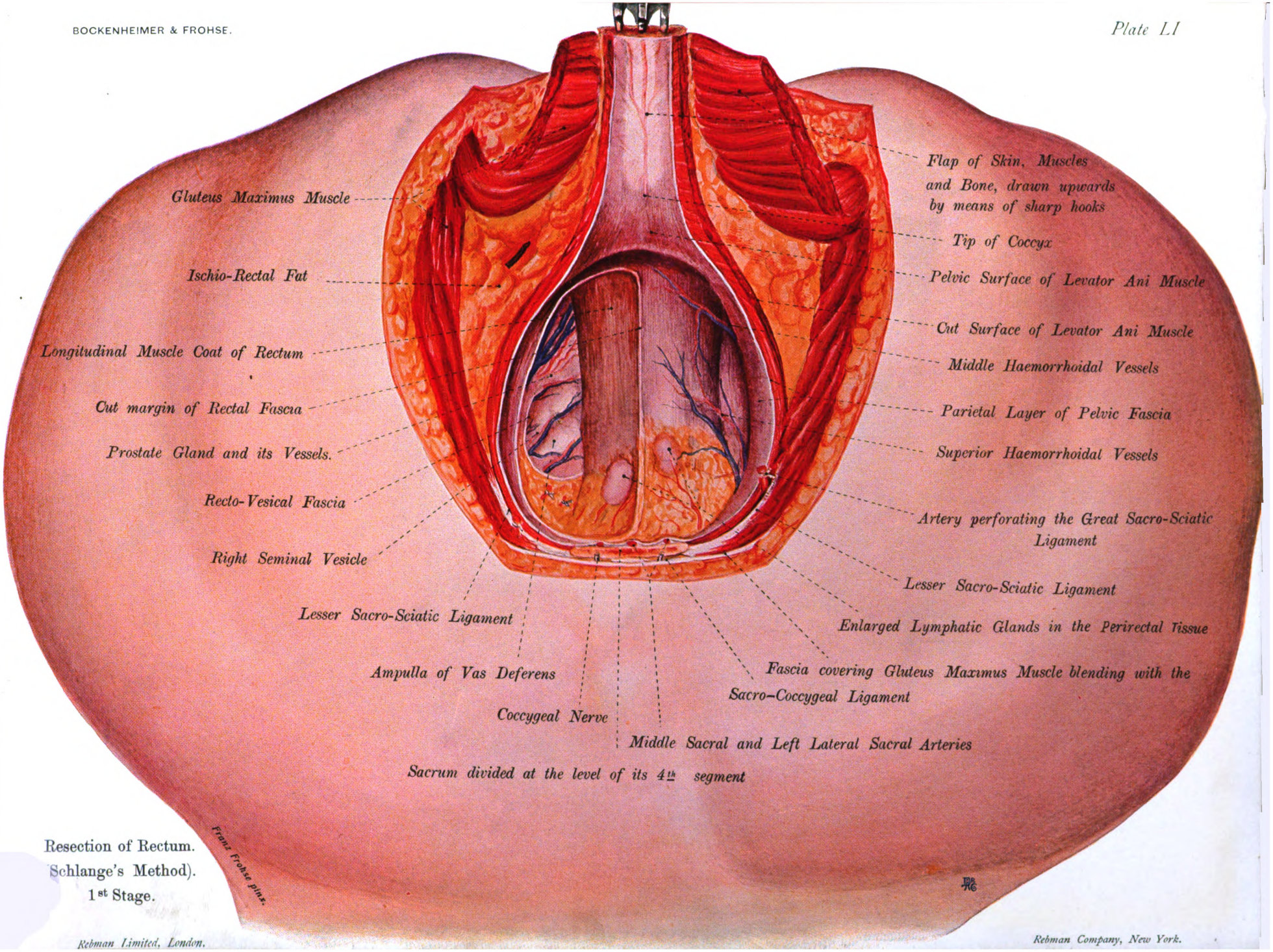

Resection of Rectum.
Schlange's Method).
1st Stage.

Rebman Limited, London.

Rebman Company, New York.

The central stump of the Sacrum is now protected by a gauze pad and the peripheral portion of the Sacrum is freed from the retro-rectal connective tissue by the blunt method.

The large flap, composed of Skin, Muscle and Bone, is turned towards the Perinæum (cf. Plate). On both sides the Levator Ani Muscle and the Anal Fascia covering it are divided before the Intrapelvic stage can be entered upon.

This method affords an excellent exposure of the field of operation.

In extensive injuries to the Rectum (impaling accidents) *Schlange's* incision should be adopted. After divisionof the Rectal Fascia the Posterior and Lateral Walls of the Rectum are readily exposed; the digital separation of the Anterior aspect of the Rectum from the Prostate is much assisted by the guidance of the Catheter; nevertheless, injury to the Urinary Tract is possible; the Rectum may be torn at the site of the tumour during this manipulation. In the event of such an occurrence sutures are necessary.

STAGE 2.

As soon as the finger can be passed between the Rectum and the Urinary Apparatus two rubber tubes are placed around the Rectum as far away from the Sphincter as possible. The gut is divided between these tubes. The peripheral portion is now attached to the flap and can be drawn with it towards the Perinæum. The Central End, including the Tumour, needs further separation anteriorly: when this step has been accomplished, the ligatured central end is drawn out of the wound towards the Sacrum. By this method the Bulbo-Cavernosus Muscle covering the Urethral Bulb, the Membranous Urethra and the Prostatic Portion can be exposed (cf. 34). An experienced surgeon (for the purpose of maintaining asepsis) may defer this division of the Rectum below the tumour.

In every case we advise free separation of the Rectum as far as the Peritoneal Reflection. Whereas this can be easily done laterally and posteriorly, considerable care is exercised anteriorly; nevertheless, this procedure is facilitated by pushing the posterior wall of the Bladder above the Prostate forwards and away from the Rectum, so that the peritoneum reflected from the bladder on to the Rectum is freed from the latter (Pouch of *Douglas*). The operator hereby exposes and enlarges the peripheral area of the Posterior Trigone of the Bladder (bounded laterally by

the Vasa Deferentia and their Ampullæ, which are in close contact with the Seminal Vesicles (*Waldeyer's* Inter-Ampullary Trigone).

After stripping the Peritoneum off the Rectum a far better idea of the extent of the growth is conceivable; if not too large, removal may be possible without opening into the Peritoneal Cavity.

The portion of the Rectum extending as far as the 3rd Sacral Segment (*Waldeyer's* Pelvic Portion of the Rectum) is dealt with as follows: Two rubber tubes are passed round the Rectum at a distance of one inch or more above the Tumour; the Gut is divided between these two constricting bands, for preference by means of *Paquelin's* cautery, and the Peripheral and Central Ends are united in the manner to be described later.

When the tumour extends upwards as far as the line of Peritoneal Reflection, the Abdominal Cavity must be opened in order that the Pelvic-Colon (*Waldeyer*) can be reached. The Superior Hæmorrhoidal Artery—a large vessel running along the posterior aspect of the Rectum and which is palpable when the Meso-Rectum

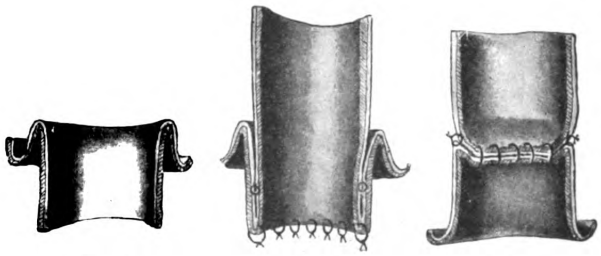

Fig. 1. Fig. 2. Fig. 3.

is long, demands attention. At first the Peritoneum at the lowest point of the Recto-Vesical Pouch is opened: with striking ease the Rectum can now be drawn down. Under all circumstances the Central portion of the Rectum must be freed far enough to allow, after removal of the tumour, of union between the Central and the Peripheral portions without any undue tension.

Any affected glands in the Meso-Rectum may be removed, but this procedure is so liable to impair the circulation and incur gangrene of the Rectum that it is far better to divide the Rectum transversely above the affected glands.

Before cutting off the bowel above the Tumour and suturing the two ends together, the central portion is drawn downwards and if the peritoneal cavity has been opened its cut edges are sutured,—either by a transverse union of the

peritoneum covering the posterior wall of the Bladder with the peritoneum covering the Anterior Wall of the Rectum or a circular peritoneal approximation (around the Rectum).

Circular sutures, in 2 layers, applied to the wound cavity is not a safe procedure, because the Pelvic portion of the Rectum has no Serous Layer.

Hochenegg's Invagination-Method is preferable when the gut is freely movable.

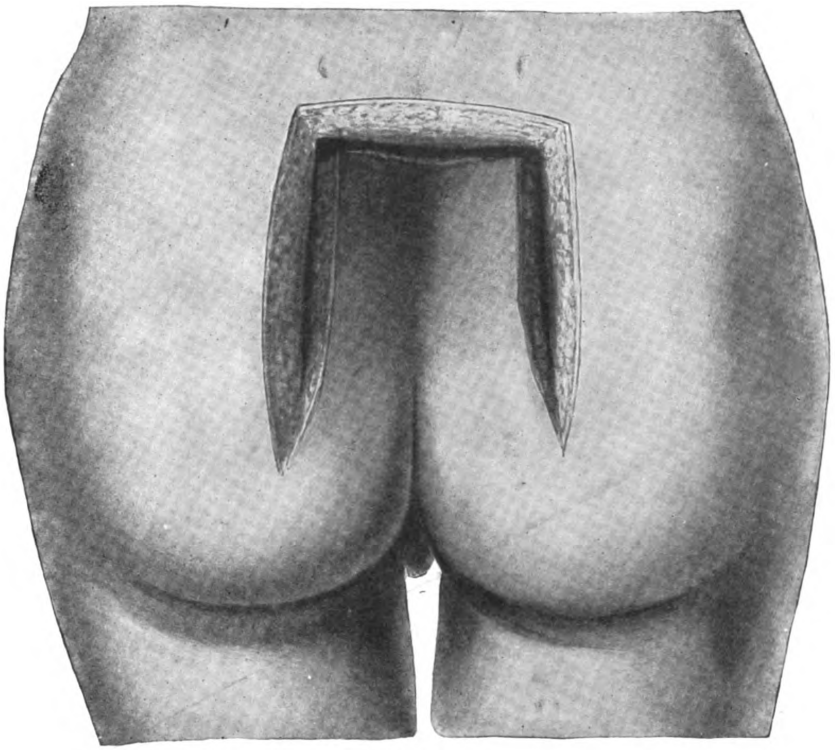

Fig. 4.

As shewn in Figs. 1, 2, 3 the peripheral portion is evaginated through the Anus (Fig. 1).

The Central portion is next telescoped through this evaginated peripheral portion. Both portions are now sewn together by 2 layers of sutures (Fig. 2). The Rectum is subsequently put back (Fig. 3). By another method, *Hochenegg* removes the Sphincter portion and after freshening the Anal margin fixes the central

portion (which he has telescoped through the Sphincter portion deprived of its mucous membrane) to the margin.

In many cases the sutures give way at the first act of defecation when a fistula is formed usually on the posterior aspect. The earlier such a Fistula occurs, the greater is the danger of infection of the wound from the fæces.

In order to protect the suture and afford better nutrition to the movable central portion of the Rectum, the bone may be removed from the flap (*i.e.,* Coccyx and a portion of the Sacrum) and the bleeding soft parts may be returned into and retained in position by a suitable dressing (*Bier.* Fig. 4). All cases treated in this way recovered without a Fistula. *Bier* advises fine lateral drains because free packing interferes with the drainage of the Rectum. We recommend fine lateral drains, the flap being temporarily kept in position by suitable dressings (Cf. Fig. 4) while a second operation effects a more complete return to its natural position.

In those cases in which the Tumour is low down near the Anus (Epithelioma) amputation of the Rectum is indicated, but when, as is often the case, Inguinal Glands are involved, a special operation is needful.

The incision should be circumferential to the Anus and close to its orifice, in performing the amputation, being extended from the Anus to the Left side of the Sacrum as far as the Sacro-Iliac Articulation (*Rehn-Rydygier*): the patient lies with the legs well fixed upon the abdomen.

For temporary division of the Sacrum it is not necessary to make a transverse skin-incision, as this may be left intact while the bone is divided subcutaneously with a chisel (*Lexer*), after cutting through the Gluteus Maximus and the Sacro-Sciatic Ligaments on the side of the incision.

By drawing aside (use a sharp hook) the divided Sacrum and Coccyx enough room is obtained for further manipulations.

After ligaturing all bleeding vessels the lateral and posterior surfaces of the Rectum are exposed. Here again some difficulty is experienced in separating the Anterior Wall of the Rectum, so that it is advisable to draw the Anal portion upwards and backwards during separation of the anterior surface from the Urogenital Tract. When the tumour is extensive the peritoneum may be opened; it is subsequently sewn up and lateral drainingе instituted.

After sufficient separation has been obtained the muscular coat of the bowel is attached to the soft parts at the upper angle of the wound (*i.e.,* Parasacral on the Left Side) by means of a circular suture. The tumour is now removed. When a suitable degree of compression is exercised upon the movable portion of the Sacrum a certain extent of Sphincteric action is derived therefrom.

The mucous membrane may be primarily or at a later date sewn to the skin. A drainage is inserted into the lower part of the wound.

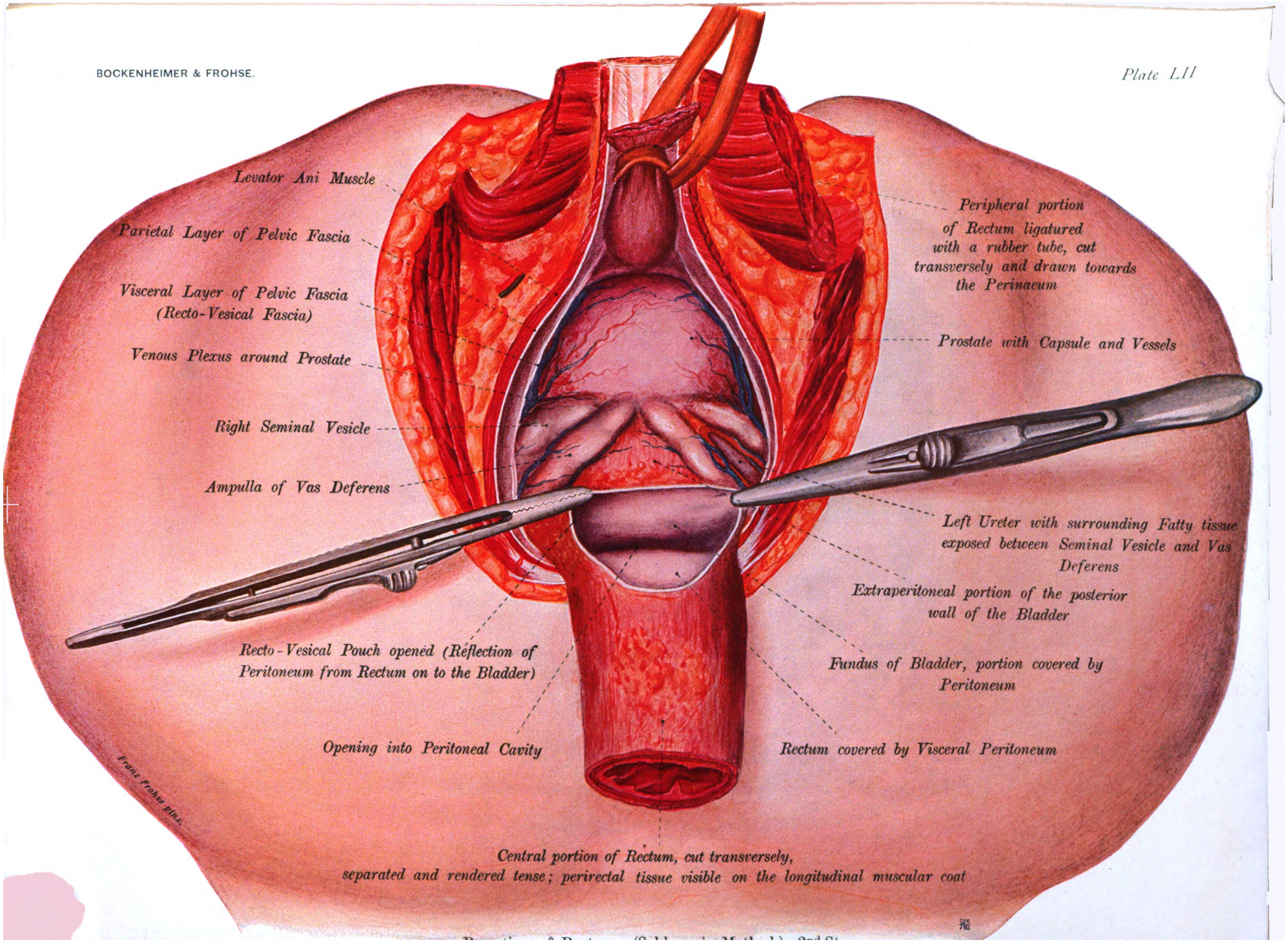
Levator Ani Muscle
Parietal Layer of Pelvic Fascia
Visceral Layer of Pelvic Fascia (Recto-Vesical Fascia)
Venous Plexus around Prostate
Right Seminal Vesicle
Ampulla of Vas Deferens
Peripheral portion of Rectum ligatured with a rubber tube, cut transversely and drawn towards the Perinaeum
Prostate with Capsule and Vessels
Left Ureter with surrounding Fatty tissue exposed between Seminal Vesicle and Vas Deferens
Extraperitoneal portion of the posterior wall of the Bladder
Fundus of Bladder, portion covered by Peritoneum
Rectum covered by Visceral Peritoneum
Recto-Vesical Pouch opened (Reflection of Peritoneum from Rectum on to the Bladder)
Opening into Peritoneal Cavity
Central portion of Rectum, cut transversely, separated and rendered tense; perirectal tissue visible on the longitudinal muscular coat
Franz Frohse pinx.

Neither *Gersuny's* method of bending the Rectum at an angle of 180° before suturing to the Skin, nor the *Witzel-Rydygier* method of drawing the bowel through an incision made in the Gluteus MaximusMuscle have given good results. To guard against Incontinence of Fæces the patient should wear an adapted truss.

In the Female *Rehn's* Method of Excision by the Vaginal Route may be employed successfully. After incision of the Posterior Vaginal Wall two lateral incisions are made extending from the median raphe of the Perinæum to the Tuberosity of the Ischia; through these incisions the tumour is freed and removed.

In the Female also we prefer *Schlange's* operation. When the seat of the tumour is the Pelvic Colon or Sigmoid Flexure, if many glands have become affected, and if there is any doubt as to the success of the operation (suitability of the tumour to operation), a preliminary Laparotomy is undertaken (*Czerny, Quenu, Rotter*). With the Pelvis raised, after setting the tumour free, *Douglas'* pouch is opened and the operation completed from below by one of the methods described.

Indeed, Laparotomy may become necessary when, though the operation was commenced from the inferior route, satisfactory progress is prevented by adhesions and numerous glands.

The After-Treatment is most important.

Collapse, which is not of uncommon occurrence, may be treated by Saline Infusions, Injections of Camphor, etc., etc. The patient should be kept lying on his side and for the first few days dressed frequently. If Delirium sets in, Saline Infusions should be resorted to while the local Iodoform packings are removed and dressings moistened with Aluminium Subacetate, Peroxide of Hydrogen or Boracic Acid are substituted. When Hyperpyrexia is present the wound must be kept freely open.

As a rule, Amputation gives no cause for anxiety; however, recovery after Resection may be complicated with many occurrences. Fistula of the Posterior Wall of the Rectum is of frequent occurrence. If dressings are firmly applied, or a cautery employed these Fistulæ may heal up spontaneously.

A Fistula in the Anterior Wall is more difficult to treat with success.

It is advisable to keep the peripheral part of the gut well open by means of Rectal Bougies.

When Gangrene follows Resection of the Rectum, a Para-Sacral Anus is made (by suturing the central portion to the Skin), and the Anal portion is removed.

If all goes well, the patient may get up after 8 days, a factor in the aid of natural defæcation. The bowels must be kept open from the 8th to 10th day onwards. Sitz-Baths afford one of the most excellent means for After-Treatment.

Plate LIII.

Operations Upon the Billiary Passages and the Liver

1. Cholecystostomy

Plate LIII.

Operations Upon the Billiary Passages and the Liver

INSTRUMENTS.



Hepatic Drainage Tube.

Lüer-W. Körte's Lithotomy Scoop.

v. Bergmann's Lithotomy Scoop.

Mayo's Gall Stone Scoop.

Operations upon the Biliary Passages and the Liver.

The most common indication for operations on the Bile-passages are Gall-Stones; these are most frequently found in the Gall-Bladder where they are usually formed. Gall-Stones are the cause of trouble: firstly, during their passage through the Bile-Ducts towards the Intensine; secondly, when the walls of the Bile-passages become inflamed and thickened.

For example, obstruction may produce a Hydrops (Mucocele) of the Gall-Bladder, or when infection occurs, an Empyæma of this Viscus. When Acute Cholecystitis is present the Gall-Bladder becomes palpable, like a definite tumour; the more severe the inflammation the more extensive the surrounding adhesions. Shrivelling of the Gall-Bladder with the formation of Fibrous tissue may also result. Jaundice does not necessarily accompany disease or displacement of the Cystic Duct.

In acute cases, with severe symptoms, immediate operation should be practised. In mild cases, the attack should be allowed to subside; the "cold operation" is also to be recommended, inasmuch as it guarantees rapid cure and safeguards against future disasters.

Several operations need consideration: The preparations are as for Laparotomy (No. 17); any particular details may be read up in special books upon the subject, such as *Kehr's* "Technik der Gallensteinoperation."

1. Cholecystostomy.

This is the formation of a Gall-Bladder Fistula.

Anæsthetic: Chloroform, Ether, *Roth-Dräger's* Apparatus. Harvey Hilliard's Apparatus for Ethyl Chloride and Chloroform.

Position: The Hepatic region is rendered prominent by a cushion placed under the back.

Incision: The incision, commenced at the costal margin, is carried through the middle of the Rectus Abdominis Muscle to the level of the Umbilicus. The nearer the incision is made to the middle line the less is the danger of injury to the Motor Nerves which supply the Rectus Muscle. The Superior Epigastric Artery (a branch of the Internal Mammary) is divided in all cases. The best incision is *Kehr's* undulating incision, which begins at the Xiphoid process and follows the mid-

dle line as far as a point midway between the Xiphoid Process and the Umbilicus. From this point the incision is carried obliquely downwards and outwards through the Rectus Muscle as far as the outer third of its width: from this point again the incision is carried longitudinally in the muscle substance, if necessary, to below the Umbilicus.

All vessels are carefully secured before opening the Fascia Transversalis and Peritoneum.

Upon opening the Abdominal Cavity the Omentum is generally seen to have formed adhesions with the Gall-Bladder; these require separation. An assistant keeps the Omentum and any protruding Intestines downwards and inwards by means of a towel. By this retraction, the Pylorus is seen near the middle line with the Colon external. The Liver is drawn upwards so that the Hepato-duodenal Fold becomes visible. This fold is generally altered, shewing either abundant adhesions or is very much broadened (stretching from side to side, cf. Plate).

The position of the Gall-Bladder is generally ascertained by the usual bile-stained colour of its surroundngs and in cases of inflammation by adhesions and bands which connect it with neighbouring parts. Touch and Sight should aid the operator.

The Fundus of the Gall-Bladder is punctured and the contents aspirated. After proceeding to open the Viscus, the surrounding area is covered with gauze pads and towels: the Gall-Bladder is incised to the extent of 1 1-2 inches, and the secured edges are held apart by traction-sutures, whereby the assistant endeavours to draw the Gall-Bladder outside the Peritoneum: this procedure can only be possible when the Viscus is enlarged (cf. Plate 54).

The contents are wiped away and the stones are removed with Forceps or Scoops. After the removal of all Calculi from the Gall-Bladder the Cystic Duct is carefully examined. In separation of the Duct the Hepato-duodenal Fold is invariably torn. Any stone in the Duct should be pressed into the Gall-Bladder whence it may be removed. If this manipulation is not successful, the Duct must be incised over the Calculus, and, when possible, this should be carried out at a point suitable for the formation of adhesions to the Liver. After removal of the Calculi the wound in the Duct is sutured with very fine silk sutures, which are passed through the muscle coats only. A drainage is always necessary.

The wound of the Gall-Bladder is stitched circumferentially to Peritoneum and Fascia Transversalis by sutures which pass only through serous and muscular coats (not including the mucous coat).

A drainage-tube is placed in the Gall-Bladder and the surrounding field packed.

When the Gall-Bladder is small or contracted it is advisable to make a Fis-

tula at the Parietal Peritoneum when *Kehr's* Tube-method should be adopted. A drainage-tube is hermetically secured in the Gall-Bladder and conducted to the surface with its track carefully packed. Even when success attends the suture of a contracted Gall-Bladder to the Fascia Transversalis and Peritoneum there is great danger of the Cystic Duct becoming bent so as to predispose to a Gall-Bladder Fistula.

The drainage-tube from the Gall-Bladder is led into a vessel of water.

All sutures should be left in rather a long time in order to ensure safety prior to their removal. Sutures may, when left in the Gall-Bladder, become encrusted.

Kehr's procedure may be adopted. Before tying the sutures connecting the Gall-Bladder Wall with the Peritoneum a wire is inserted so that the knots may be made over the wire. By this means in the removal of sutures the wire only need be pulled upon while the sutures are cut beneath it.

The Abdominal wound may now be closed, preferably by deep sutures which are passed through all layers (cf. 47) except where the gauze-drain and drainage-tube emerge.

Cholecystostomy is a reliable and easy operation. The Fistula allows Calculi which may have remained inside to pass away and the infected secretions to be drained off.

Primary closure of the incised Gall-Bladder is often dangerous. (Ideal Cholecystotomy of *Bernays.*)

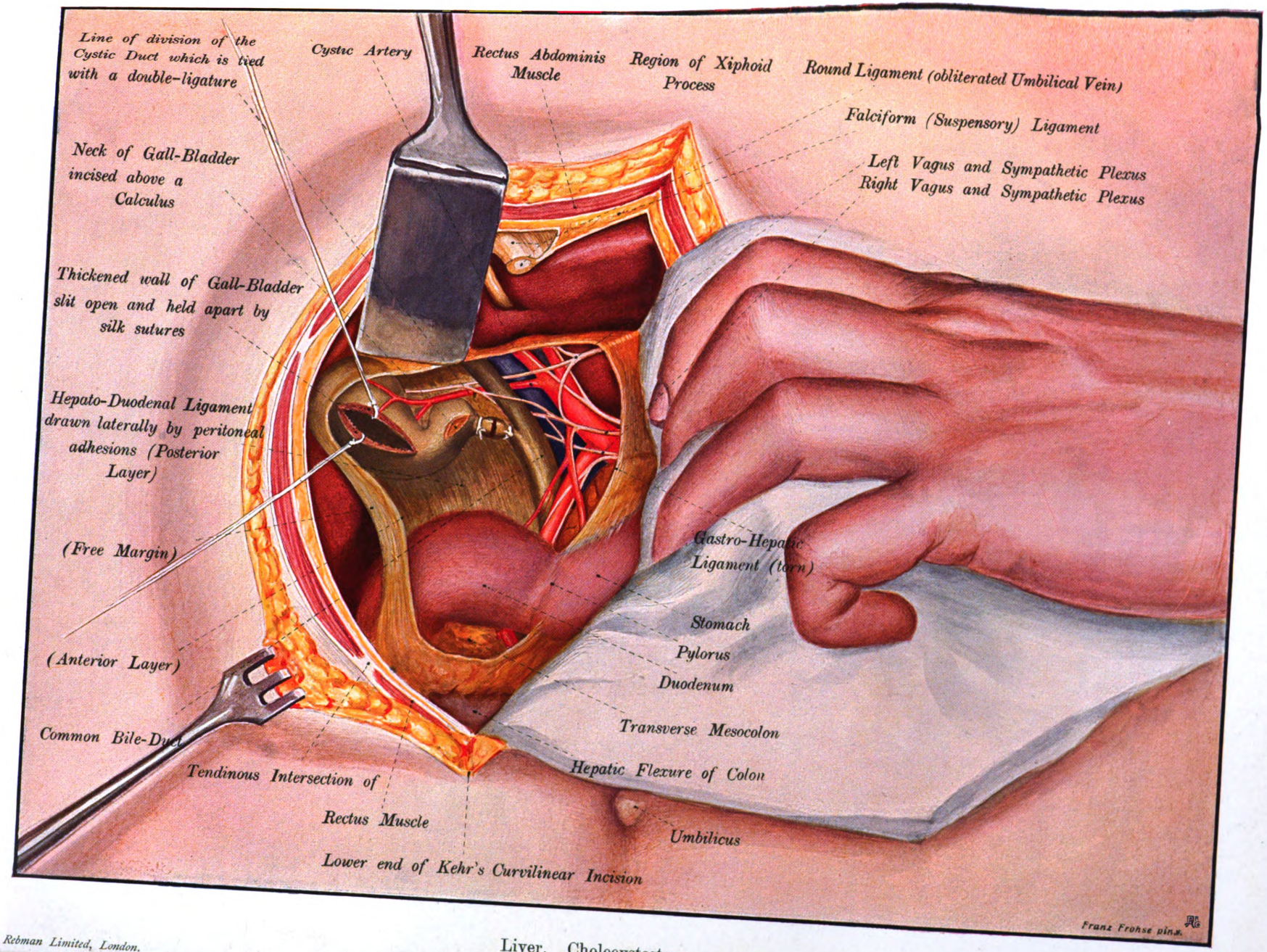

Rebman Limited, London.

Liver. Cholecystostomy.

Plate LIV.

2 Cholecystectomy

2. Cholecystectomy.

We have already recommended the formation of a Fistula when the Gall-Bladder is shrivelled up. Beside *Kehr's* Tube-method Cholecystectomy demands a consideration in these cases. There are very many cases in which the replacement of Cholecystostomy by Cholecystectomy is favoured.

Preparations: Position, Anæsthesia, etc. (Cf. Plate 53.)

Indications: In addition to those given in the previous section we would mention Ulcerative Changes in the Wall of the Gall-Bladder, Obliteration of the Cystic Duct, Tumours.

Contra-Indications: A much dilated or friable Cystic Duct upon which a ligature would not be safe. Under this condition Cholecystostomy should be performed.

Incision: *Kehr's* Undulating Incision.

When the preliminary steps have been carried out as in the preceding section (Plate 53), when the anterior layer of the Hepato-duodenal Fold and the numerous erous adhesions have been severed, an attempt is made to expose the Gall-Bladder and Cystic Duct. The Free Abdominal Cavity is packed off with gauze. The Gall-Bladder is separated from the Liver partly by cutting and partly by blunt dissection. Bleeding from the Hepatic bed of the Gall-Bladder is stopped by Iodoform Tampons, Cautery or Ligature.

The Gall-Bladder must be freed as far as the Cystic Duct so as to form a distinct pedicle.

The Duct, when separated, is secured with a *Doyen's* Clamp, doubly ligatured and divided between the ligatures by the Cautery. The central end is once more cauterised. The Cystic Artery should have been previously ligatured in two places.

A drain should always be placed on the stump of the Cystic Duct. The remaining portion of the Abdominal wound is sewn up.

When Calculi are suspected to be situated in the Hepatic or Common Bile Duct and for all Chronic cases with recurrent attacks, *Kehr* recommends Cholecystectomy (with ligature of the duct at the neck of the Gall-Bladder) combined with the opening up of the Duct upon a director. The director is introduced into the central end of the duct the anterior wall of which is opened as far as the exposed Common Bile Duct. (In the Plate the central end has been ligatured.)

The Common Bile-Duct and the Hepatic Duct, after isolation, should also be slit open if necessary. (Cholecystectomy with drainage of Hepatic Duct continued in the next plate.)

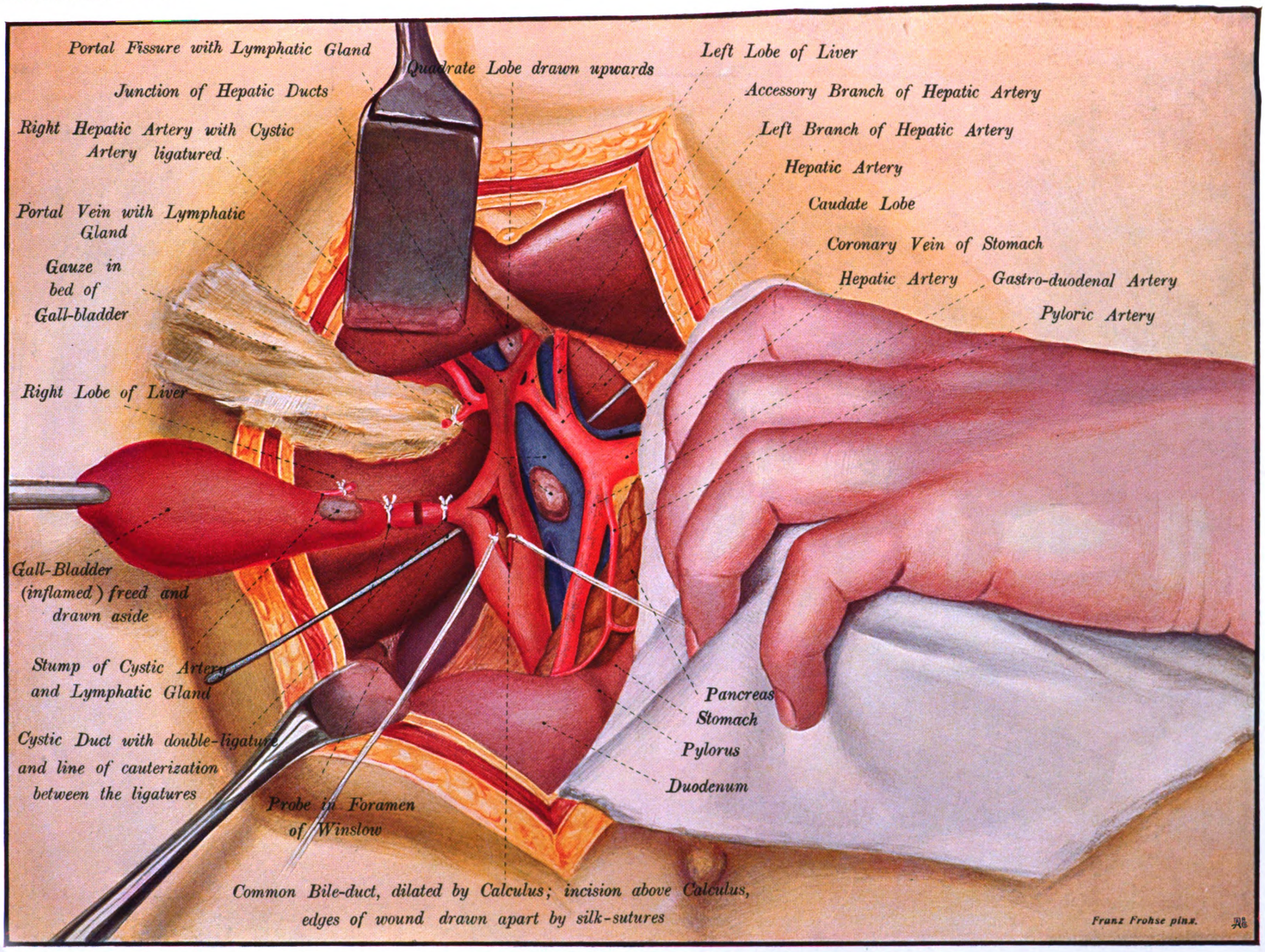

Cholecystectomy.

Rebman Limited, London.

Rebman Company, New York.

Plate LV.

3. Cholecystectomy and Choledochotomy Drainage of Hepatic Duct

3. Cholecystectomy and Choledochotomy. Drainage of Hepatic Duct.

Through the opening in the Common Bile Duct, a drainage tube, with a lateral opening near its extremity, is introduced into the Hepatic Duct and fixed by Sutures which are passed through the wall of the Common Bile Duct. (Drainage of Hepatic Duct.) Except at the point of entrance of this tube the incisions in the 3 Ducts (Cystic, Hepatic and Common Bile Duct) are sewn up with silk sutures, which should not pass through the Mucous Coat. These sutures are left long. Free drainage (cf. Choledochotomy) is always necessary.

When the Gall-Bladder and Cystic Duct are free from stones, but when the Calculi are present in the Hepatic or Common Bile Duct (marked Jaundice) incision of the Common Bile Duct with drainage of the Hepatic Duct is sufficient. It is often a difficult task to find the duct under these circumstances, because it may be enveloped by much fibrous tissue or displaced by bands.

Careful Hæmostasis is imperative to avoid a fatal issue as Icteric patients are of a hæmorrhagic diathesis. When the Gall-Bladder and Cystic Duct are diseased Choledochotomy should be followed by Cholecystectomy. Only when Cholecystectomy is impossible (vide supra) is Cholecystostomy permissible. Cholecystectomy or Cholecystostomy are performed in the usual manner before opening into the Common Bile Duct.

In order to find the Common Bile Duct the index finger of the left hand is placed into the Foramen of *Winslow,* the anterior layer of the Hepatoduodenal Fold having previously been split during the operation of Cholecystectomy. Lying in front of the finger are the Bile-Duct to the Right, and the vessels to the Left. If dilated and filled with Calculi the Common Bile Duct is readily found.

When the Abdominal Cavity has been protected by packing, the Common Bile Duct is incised above the Duodenum (cf. Figure).

The incision is held open by traction-sutures; the secretions are carefully wiped away and any stones removed. It is an important precaution to Catheterise the Hepatic Duct towards the Liver and the Common Bile Duct downwards into the Duodeum. Any Calculi in this upper or lower portion of the Ducts are manipulated towards the incision and removed.

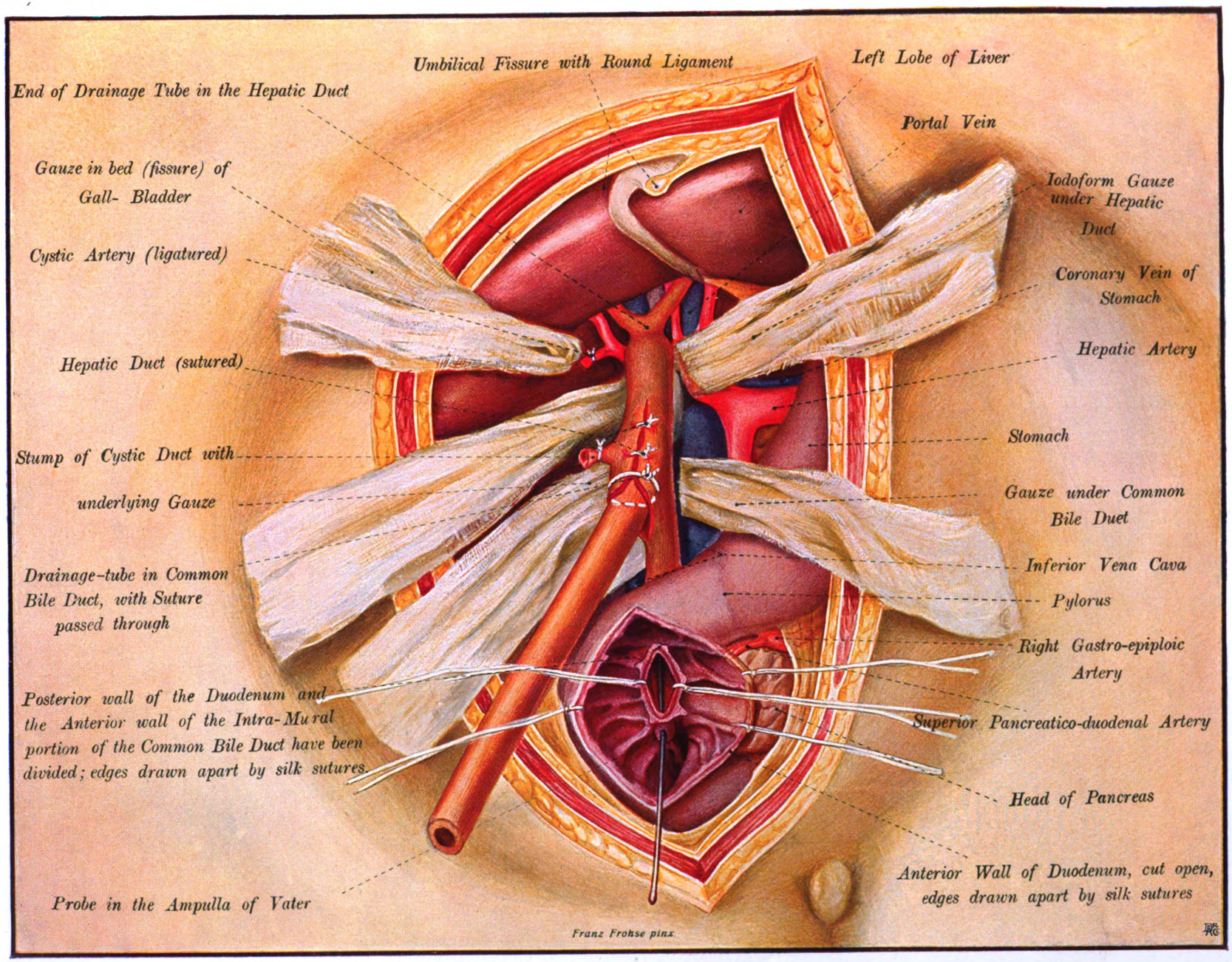

Cholecystectomy and Choledochotomy Drainage of Hepatic Duct.

Rebman Limited, London.

Rebman Company, New York.

The Common Bile Duct should never be completely sewn up, but a drainage should be passed through the incision in the direction of the Liver and sewn in position.

Careful packing around the tube, over the stump of the Cystic Duct, over the Hepatic Duct in the Foramen of *Winslow* and in the Hepatic Groove for the Gall-Bladder is most necessary. The Abdominal Walls are united in the usual way.

If a Gall-stone has become firmly impacted in the Duodenal Portion of the Common Bile Duct, or if adhesions render it impossible for the operator to find the Common Bile Duct, one of the Transduodenal Methods should be employed (*Kocher* and others).

The Anterior Wall of the Duodenum is opened by a Longitudinal or Transverse incision. The Ampulla of *Vater* is found and endeavours are made to remove the Calculi through this orifice. If these attempts prove futile access is had to the Calculus by an incision through the posterior duodenal wall and the anterior wall of the Intramural portion of the Common Bile Duct. If the Ampulla cannot be recognised, a direct incision may be made over the Calculus as it lies within the Duct which is now held in the hand.

In both cases the edges of the opening into the Common Bile Duct are stitched to the posterior wall of the Duodenum as a Fistula.

The Anterior Duodenal Wall is closed in layers. In some cases, particularly when malignant growths are present (*e.g.* Tumours of the Head of the Pancreas), even the Transduodenal Methods may not be practicable.

In order, therefore, to allow for the passage of the accumulated bile an anastomosis is made between the Small Intestine and the Gall-Bladder; in this case, however, there is a risk of retrograde infection spreading from the gut to the Biliary Channels. This operation of Cholecystenterostomy may be accomplished as Cholecyst-duodenostomy or Cholecyst-jejunostomy: the more correct but perhaps the most difficult procedure is the former.

The technique of the operation is much the same as for Gastro-enterostomy. The contents of the Gall-Bladder are aspirated previous to a seromuscular suture between the Gut and Gall-Bladder, both viscera are incised (incision about 4/5 inch long) and united by first a Posterior Seromuscular then an Anterior Sero-muscular suture. The anterior wall of the anastomosis is further strengthened by a seroserous (*Lembert*) suture. The mucous membrane is not included in the sutures. The Abdomen is closed in the usual manner.

The advantages of the operation are:

The possibility of primary closure of the Abdominal Wall without any risk of Gall-Bladder or Bile-Duct fistulæ.

The patient does not lose bile.

The after-treatment is very difficult (cf. *Kehr's* Technique der Gallenstein operationen).

These operations are often followed by severe shock. The Sterilised Gauze-tampons are removed after an interval of 3 to 4 weeks, by traction on the sutures which were purposely left long, under Peroxide of Hydrogen irrigation.

Any remaining Calculi are removed by daily irrigation of the Fistula. If a permanent fistula remains the clinician becomes suspicious of continued inflammation or unremoved calculi.

Bending of the Duct is another cause of the persistence of a Fistula—this may be the consequence of faulty technique.

According to the conditions which persist, the Fistula is closed or a Secondary Laparotomy performed. In cases of a lip-fistula, *i.e.,* with the edges everted, cauterisation on a tampon soaked in Aluminium Subacetate may be tried.

If Consecutive Peritonitis occurs the Abdominal wound must be freely opened and when necessary incisions should be made (in the loin and inguinal region on both sides as well as in the middle line) for drainage and irrigation with normal Saline solution.

We mention that Gall-stones may produce an Ileus (Volvulus or Twisting).

In this instance the prominent symptoms would be those of Volvulus and the usual median Laparatomy should be performed. The Intestine may be incised longitudinally over the Calculus and the incision-wound sewn up in a transverse line.

Diseases of the Liver.

Immediate Laparotomy is usually called for when the Liver is injured (Bullet wounds, Rupture of Liver after a run-over accident). Hæmorrhage may be arrested by packing, by intrahepatic ligature with *Kusnezoff* and *Peusky's* Blunt Needles (cf. *Anschütz,* Über die Resection der Leber, *v. Volkmann,* Sammlung klinischer Voträge No. 556-57), by Cauterisation (at a red heat slowly applied), or by Steam (*Snegireff*).

Kocher recommends the application of large pressure-forceps which are retained for two days. Recently attempts have been made to remove diseased portions of Liver-substance (Carcinoma, Sarcoma, Gumma). For Hydatid Cysts of the Liver it is desirable to perform the operation in two stages.

The first stage consists in fixing the diseased portion to the Parietal Peritoneum. A few days later the Cysts are opened.

For Abscess, incision of the Liver is necessary. If the Abscess is situated in the lower part of the Viscus or in the Left Lobe access is obtained by a Laparotomy. (Cf. 33.)

For Hepatoptosis the Liver is stitched to the Costal Arch or to the Anterior Wall. This has met with success in the hands of *Depage* (*Hepatopexy*). In all cases, operations upon the Liver are among the most dangerous, firstly, because it is very difficult, oftentimes impossible, to procure Hæmostasis; secondly, owing to the Extensive degree of postoperative shock.

Plate LVI.

Extirpation of the Thyreoid Gland

Plate LVI.

Extirpation of the Thyreoid Gland

INSTRUMENTS

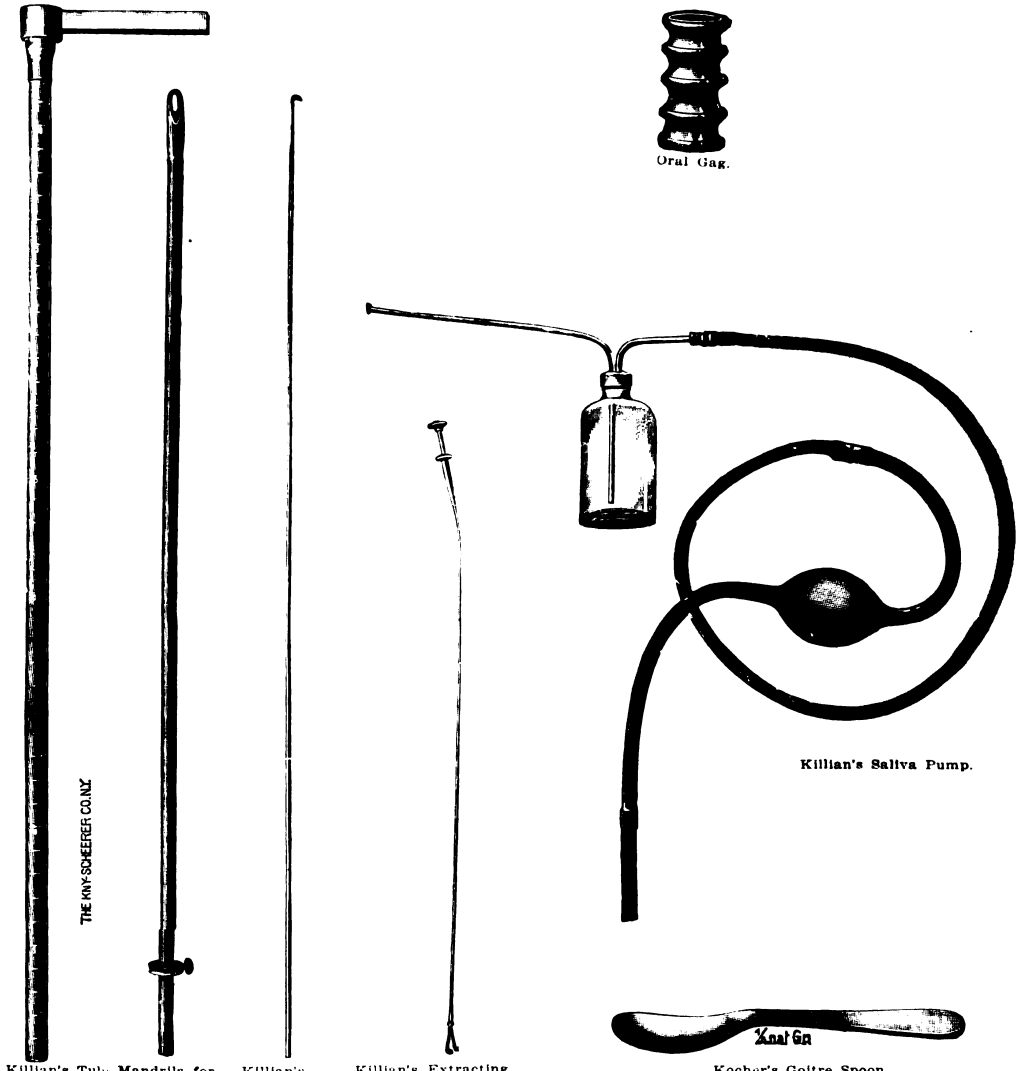

Oral Gag.

Killian's Saliva Pump.

Kocher's Goitre Spoon.

Killian's Tube for Bronchoscopy, Two Sizes.

Mandrils for Bronchoscopic Tube.

Killian's Extracting Hook.

Killian's Extracting Forceps.

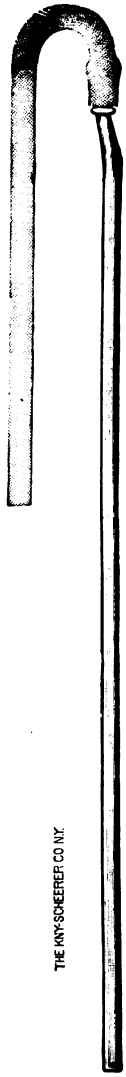

Extra Tube for Killian's Saliva Pump.



Laryngeal Forceps.



Apparatus for Peroral Intubation.

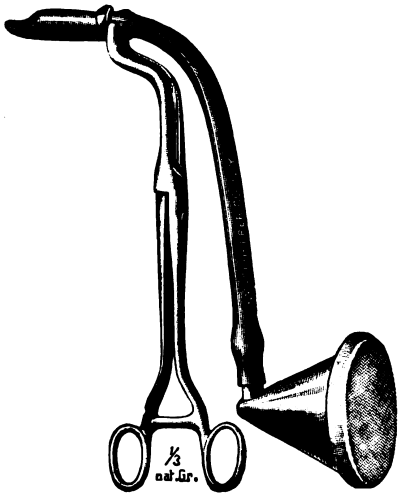

Doyen's Intubation Canula with Chloroform Apparatus and Introducing Forceps.

Killian's Cocaine Spray.



Killian's Intra-Laryngeal Tubular Spatula.

Killian's Curette Forceps.

Killian's Chloroform Attachment for Bronchoscopic Tubes.

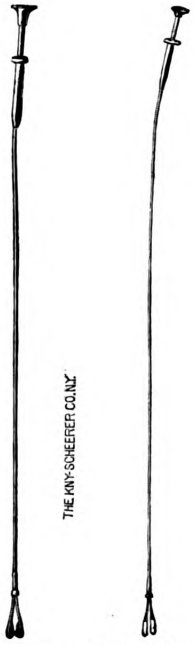

Killian's Compression Forceps. Killian's Forceps for Obtaining Specimens.

Fraenkel's Laryngeal Forceps.

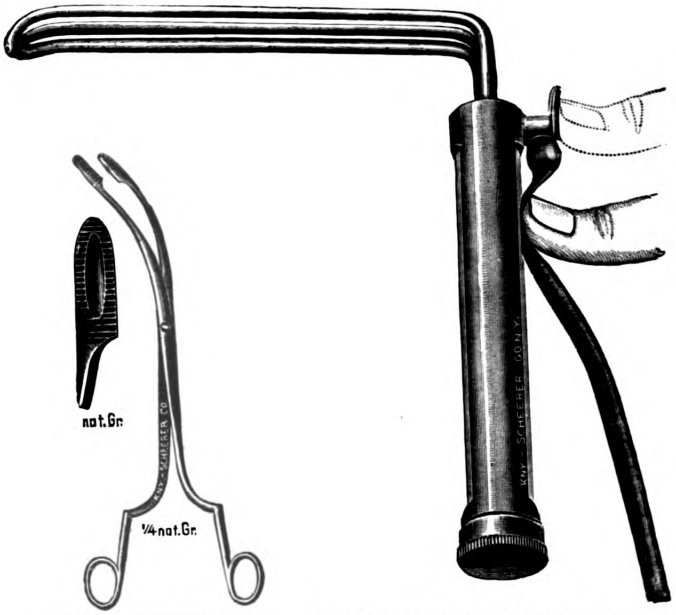

Killian's Cocaine Spray with Tongue Depressor and Uvula Retractor.

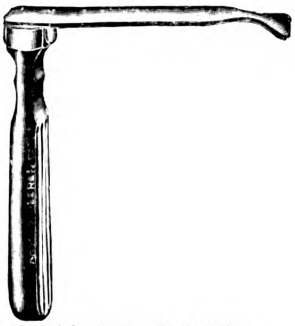

Kirstein's Autoscopic Spatula.

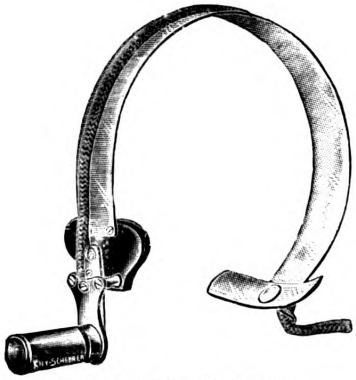

Kirstein's Electric Head Lamp.

Laryngeal Electric Illuminator.

Kocher's Bronchocele Sound.



Killian's Handle for Bronchoscopic Tube.

Extirpation of the Thyreoid Gland.

STAGE I.

A Goitre requires removal by surgical measures when it gives rise to serious trouble (Dyspnœa). The operation may, in most cases, be spoken of as free from danger. Accordingly, treatment of a Goitre by drugs (Iodine, Arsenic) or by injections (*Lugol's* Solution) is only justifiable in special cases.

The operation becomes urgent when the Goitre produces Dyspnœa, extends downwards (retrosternal) or when the two symptoms of *Graves'* Disease (Exophthalmos and Tachycardia) are present; inflammation or Tumours call for Surgical treatment.

Apart from simple incision which is indicated in suppuration, softening due to hæmorrhage or tumours undergoing degeneration which, in many cases, can be scraped out, the following operations have to be considered: Partial Extirpation and Enucleation. Before proceeding with the operation it should be determined by means of the X-Rays (*v. Bruns,* Blauel, Congress of Surgery, 1905), whether the Trachea is pushed aside or compressed so that the operator may be able to remove only that portion of the gland which presses on the Trachea. We rather hesitate in employing Bronchoscopy, which is described in detail in the 2nd Stage, because the instrument is very likely to produce Asphyxia.

General Anæsthesia, Chloroform—Oxygen Apparatus. For patients liable to Asphyxia (*e.g.* in cases of Bilateral Paralysis of the Recurrent Laryngeal Nerve) no Anæsthetic or *Schleich's* Infiltration Anæsthesia should be employed if possible.

Tracheotomy is to be avoided whenever possible in order to avert infection of the wound (Cellulitis, Mediastinitis) or of the Lung (Aspiration Pneumonia).

Total removal of the Gland is only justifiable in Malignant Tumours on account of the serious consequences (Tetany, Cachexia Strumipriva, Idiocy, Myxœdema, etc.).

Protection against such evil consequences should be made by grafting fresh Thyreoid Tissue (from a calf) into the Abdominal Walls and by feeding with Thyreoid preparations. In cases of Malignant Disease the operation is attended with such serious risks and recurrence is so frequent that medicinal treatment (Arsenic) or X-rays are preferable. The most frequent procedure is Unilateral or Partial Extirpation (cf. Plate), which may be complete if the other side is healthy.

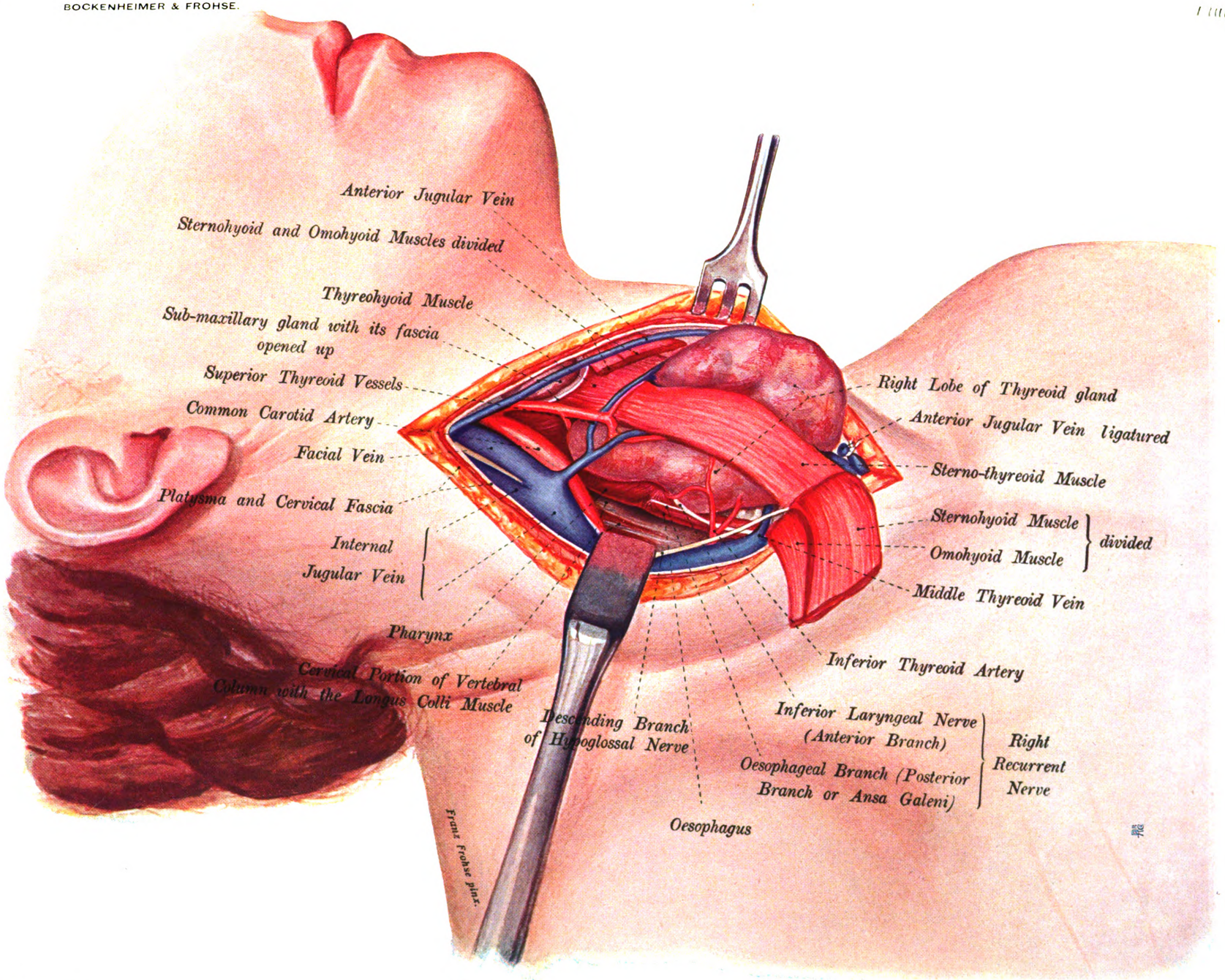

Excision of Thyreoid Gland. — 1st Stage.

Rehman Limited London

course behind the large vessels and Vagus nerve, becoming visible when traction outwards is exerted upon the Carotid Artery at the level of the Carotid Tubercle.

This vessel should be ligatured as far away as possible from the Thyreoid Gland in order to avoid the Recurrent Laryngeal Nerve and to obviate the necessity of multiple ligatures.

If the Recurrent Laryngeal nerve does not come into view during these manipulations, it is advisable to leave a portion of the Posterior Wall of the capsule of the enlarged lobe.

At the Inferior Pole of the Lateral Lobe, the operator may encounter a large artery—Thyreoidea Ima—this vessel and the accompanying veins will require double ligatures.

Small portions of the diseased gland lying in the Supra-Sternal Notch are easily removed, but large nodules situated behind the Sternum are separated by the finger or *Kocher's* Scoop.

Apparently alarming Venous Hæmorrhage may result from this manœuvre, a tampon will temporarily stop the bleeding until the Veins can be ligatured. It is necessary to remember that the Large Innominate Vein lies behind the Manubrium Sterni.

The Goitre is next freed from the Trachea by blunt dissection in order to avoid Necrosis; to prevent injury or impairment of nutrition to the Trachea it is often necessary to leave a thin layer of the gland.

After separation of the Lateral Lobe the Isthmus is ligatured (double-ligature) and divided with a Cautery. Large Veins are always present over the Isthmus.

(Operations continued in Plate 57.)

Isolated, well-encapsuled tumours of the Thyreoid Gland may be dealt with by Enucleation. In this operation the gland is incised as far as the tumour, all hæmorrhage is controlled, and the nodule enucleated by means of blunt instruments. When Hæmostasis is complete the incised glandular tissue may be sewn up. The advantage gained by this operation is practically nothing; because, though the Recurrent Laryngeal Nerve is usually safe, the Hæmorrhage will result and frequently demand the ligaturing of the Superior and Inferior Thyreoid Arteries or removal of the Lateral Lobe.

Accordingly, many surgeons regard Unilateral Extirpation as the normal procedure, reserving the operation of enucleation for Cysts.

When the whole gland is diffusely affected, *e.g.* Colloid Degeneration, partial resection may be resorted to.

Either wedge-shaped incisions may be made into the gland or the capsule may be incised, and the diseased portion removed piecemeal,—only the upper or

lower poles being left, in accordance with the seat of the disease. By this method the Goitre is much diminished in size: the remaining portions are sutured together.

Hæmorrhage, which is frequently very severe, may be avoided by using the Cautery instead of the knife, or using *Doyen's* Compression Clamp before ligature.

Considerable caution should be exercised not to remove too much of the Glandular tissue. If surgical measures are resorted to for *Graves'* (*Basedow's*) disease, the procedure to follow is ligature of the Superior and Inferior Thyreoid Arteries on both sides at the seat of election. (Incisions parallel to the Inner border of the Sterno-Mastoid Muscle. *Vide supra.*)

Removal of the Superior Cervical Sympathetic Ganglion has been carried out for this affection.

Plate LVII.

Extirpation of the Thyreoid Gland

Extirpation of the Thyreoid Gland.

STAGE 2.

When Unilateral Extirpation of a Goitre has been practised marked Asphyxia may occur, due to collapse of the Trachea, as the result of marked lateral compression. Under these circumstances the Trachea must be kept patent by means of hooks or traction-sutures. It is sometimes necessary to stitch the Trachea to the neighbouring muscles but rarely need Tracheotomy be resorted to. After the removal of a diseased lobe, the operator should carefully investigate the presence of Accessory Thyreoids or Nodules in the Supra-Sternal Notch which might exert undue compression on the Trachea.

Plate 57 shews the condition of the parts after removal of the Goitre (diseased lobe), and explains the care necessary in the operation in order to avoid injury to the Recurrent Laryngeal Nerve or to the Large Vessels.

Injury to the Veins, particularly to the Internal Jugular Vein, may produce death from air-embolism. Should injury to the Vein be suspected, the operator must immediately push a tampon into the lowest angle of the wound, *i.e.,* as near the heart as possible. When air enters the vein a peculiar hissing sound is heard. Air-embolism may be followed by immediate death.

Punctures of Vessel-walls may be dealt with by ligatures, small incisions by lateral sutures with very fine silk, or preferably by a double ligature. In case of injury to the Common Carotid Artery, arterial suture is advisable because ligature of the Vessel may be followed by Cerebral softening.

The best method of sewing up blood-vessels which is applicable to all injured Arteries is the method devised by *Payer* (Verhandlugen der Deutschen Gesellschaft fur Chirurgie, 1899, Arch. f. klinische Chirurgie, Bd. 72), who uses a prosthesis of Magnesium or that invented by *Hopfner* (*Arch. f. klinische Chirurgie,* Bd. 70). (Cf. Fig. 1-3.)

The technique is shewn in the accompanying figures:

Fig. 1. The Hæmostatic Forceps is applied to the Vessel. The Prosthetic apparatus is drawn over the end of the vessel and held in position by means of the Prosthesis-forceps. The end of the divided vessel is turned back by means of traction sutures.

Fig. 2. The Prosthesis is fixed to the Central End of the Vessel by ligature, it is then approximated by the aid of the Prosthesis-forceps to the distal end of the

vessel, which is held open by 3 Traction Sutures, while the Prosthesis is pushed into the distal portion. (The curve of the Hæmostatic Forceps when applied to either end must be directed with its convexity upwards.)

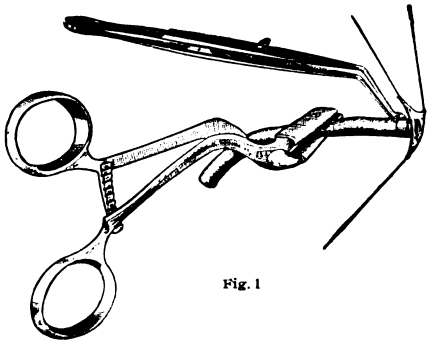

Fig. 1

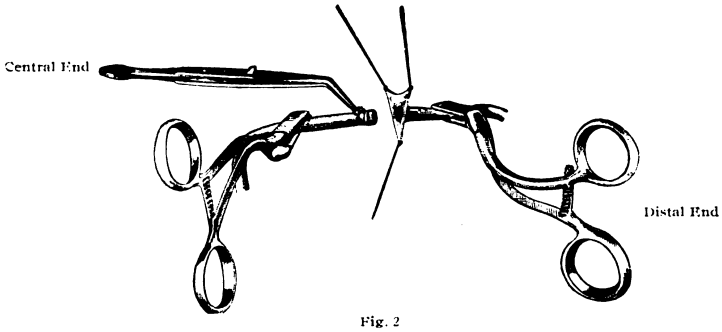

Fig. 2

Fig. 3

Fig. 3. Illustrates the suture completed.

Injury to Vessels is most likely to occur in operations for Malignant Disease of the Thyreoid. The Vagus is also liable to be injured. When this unfortunate result occurs or when the Recurrent Laryngeal Nerve is divided Aspiration Pneumonia may be set up in the Lung of the corresponding side and death result.

This plate also gives the regional anatomy to be considered in cases of removal of Tuberculous Cervical Glands and of Malignant Tumours, such as: Sarcomata originating in the (Carotid) Vascular Sheath or Carcinoma commencing in the Epithelium of Branchial Recesses or in already-existing Branchial Cysts.

In these operations injury to the Vagus is of frequent occurrence.

In every case Hæmostasis must be complete in order to prevent subsequent bleeding. The divided muscles may be sewn together by catgut sutures.

Drainage of the wound-cavity should always be resorted to and the gauze-drain employed left in situ for 5 to 8 days.

The wound is sewn up with the exception of the inferior angle.

The desire to avoid stitch-holes, provided the tension is not too great, may be accomplished by *Michel's* method (metal hooks and clamp). (Cf. No. 46.)

After the extensive removal of the Thyreoid Gland and in those cases in which the Trachea has been subjected to lateral compression a card-board splint is applied so as to keep the Head and Neck in a fixed position.

By this means Reactionary Hæmorrhage is obviated and bending of the Trachea in retraction of the Head (Goitre-Death) is prevented.

After a period of 8 days the gauze drain may be removed if everything goes well. A bandage is lightly applied.

In very many cases of Goitre affecting both lobes of the Thyreoid Gland, Unilateral removal is sufficient as the remaining lobe frequently shrinks spontaneously. Recurrence on the side of the operation occurs, but, as a rule, such does not give rise to enough trouble to justify a second operation.

Autoscopy. Laryngo-Tracheo-Bronchoscopy.

Autoscopy was introduced by *Kirstein* in 1894. This clinical method is based upon the possibility, by means of a specially adapted Spatula, of pressing the back of the tongue forcibly forwards and downwards, so that the Larynx and Trachea form practically one straight tube with the floor of the Buccal Cavity. When insufficient information is obtained by the Laryngoscope this method is employed. It is, however, somewhat painful, and not suited to every patient. *Von Schrötter* and *Pieniaceck* after a Preliminary Tracheotomy introduced suitable tubes for the inspection of the Lower Air-passages.

Killian, acting upon this idea, tried a new method based upon the principles of Oesophagoscopy.

This observer introduces suitable tubes through the mouth and by this route inspects the Larynx, the Trachea and the Bronchi directly.

This method is almost suited to universal application, without the production of pain, under the following conditions:

The patient should be fasting; all articles around the neck should be removed, any false teeth or dental plates should be taken out. If the patient is unable to open his mouth widely a few teeth may be removed from the upper jaw.

One of the points of greatest importance in this procedure—as in Oesophago-

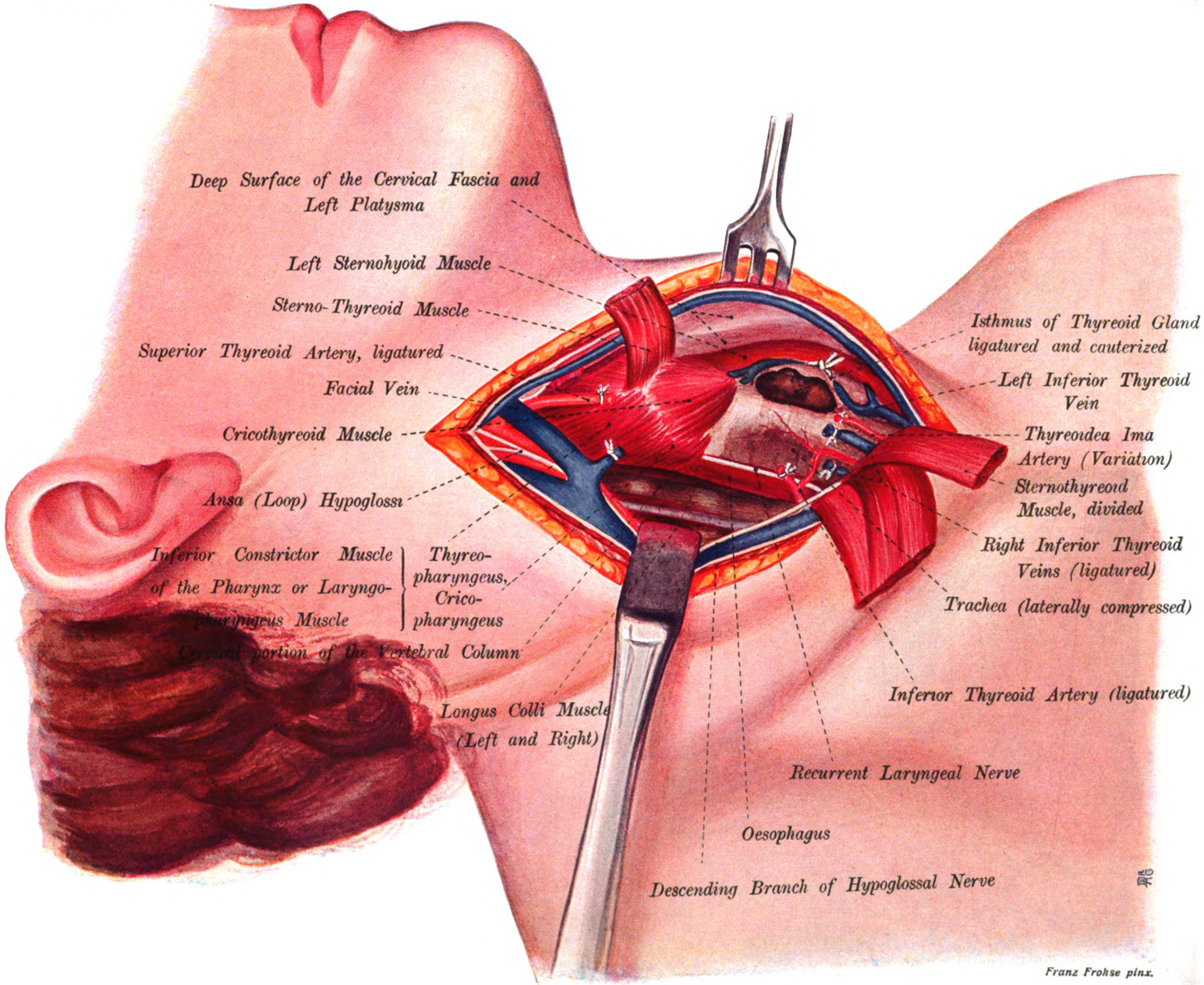

Rebman Limited, London.

Excision of Thyreoid Gland. — 2nd Stage.

scopy—is the local anæsthetisation of the back of the Tongue, the Soft Palate, the Epiglottis, the Glottis and Infra-Glottidean Space by means of a 20 per cent to 25 per cent aqueous (or even better alcoholic) solution of Cocaine, to which may be added, if desired, 1 or 2 drops of Adrenalin. The spray is directed on these parts by the aid of a Spatula or Laryngoscope. If the patient is much excited, a hypodermic injection of Morphia may be given about an hour prior to the cocaine-spray.

For children a general Anæsthetic is recommended. The Tubes are warmed, lubricated with oil and introduced into the patient's mouth while in the sitting position. The Index finger of the Left Hand may be used as a guide for the introduction of the tube. With the Head well retracted, the patient should take a deep breath, coincident with the passage of the tube between the Vocal Cords.

It now becomes necessary to anæsthetise the Trachea as far as its bifurcation; through the tube a swab of cotton-wool soaked in a 10 per cent solution of Cocaine (20 per cent in catarrhal conditions) may be applied. The tube can then be introduced further.

For illuminating purposes *Kirstein's* Head-Lamp is the best; but for purposes of demonstration *Casper's* Electroscope should be employed. For Laryngo-Tracheoscopy the tube-spatula is usually sufficient. In fact, it is always advisable to primarily make use of the tube-spatula; and subsequently to pass the tube for examination of the lower end of the Trachea or Bronchi.

This method is designed for diagnostic and therapeutic purposes, including surgical manipulations such as removal of foreign bodies.

It is contra-indicated in cases of Aortic Aneurysm, marked deformity of the Trachea and Goitre producing respiratory difficulty.

The introduction of this method has rendered High Tracheotomy unnecessary in many cases. For the removal of foreign bodies, those inexperienced in this new method should employ Tracheotomy. If the foreign body has only recently entered the air-passage, and if it does not become swollen by imbibition (*e.g.* beans) simple incision of the Trachea frequently brings the body into the wound whence it can be extracted with ease. Practitioners who are not familiar with Bronchoscopy do better by introducing the tube through the opening of a High Tracheotomy.

Tracheotomy is always indicated if it is necessary to remove a foreign body which might lacerate the Larynx or become impacted lower down (Inferior Direct Bronchoscopy).

For Superior Direct Bronchoscopy in which the tubes are introduced by the mouth, *i.e.,* without Tracheotomy, deep general Anæsthesia is usual; in children it is always employed so as to avoid any reflex coughing.

The patient's head is directed backwards. When the Fauces and Larynx have

been well Anæsthetised with cocaine the tube-spatula is introduced. The Trachea is now anæsthetised and the Bronchoscopic tube introduced through the tube-spatula.

The tube is directed towards the side of the Bronchus which is about to be inspected, by this guide the Bronchus is anæsthetised with a solution of Cocaine conveyed on a pledget of wool fixed in a holder. The Tube can now be introduced further. Mucous is removed by aspiration (cf. Oesophagoscopy. Plate 58).

The technique of this method can only be learnt by repeated practice on the Cadaver.

If a main Bronchus is almost completely occluded by a foreign body, the tube introduced should have an opening corresponding to the main Bronchus on the unaffected side, so as to avoid Asphyxia.

Bronchoscopy is of service as a diagnostic and Therapeutic measure, the evacuation of Pulmonary Abscesses, Inflammation, etc. Its most frequent employment is in the removal of foreign bodies, for which purpose the instruments, forceps, etc., described, are required (cf. Instruments).

In certain cases the foreign bodies cannot be extracted through the tube, they are accordingly suitably pressed against the tube and removed by withdrawing the tube.

If removal is impossible, the position of the foreign body is carefully ascertained prior to the operation of Pneumonotomy.

A Skiagram is taken while a bougie is passed through the tube as far as the foreign body. The Lung is cut through, on to the bougie, by means of the Cautery.

Whenever there occurs any suspicion of an inhaled foreign body, Branchoscopy should be immediately employed; the earlier this is done the easier is the procedure, inasmuch as the air-passages have not already undergone any alteration.

After an examination the tubes are removed as soon as possible, so that the accumulated mucus may be evacuated. Subsequent pain can be treated with Morphia, Cold pack, inhalations of Steam. (Cf. *v. Eicken,* Arch. f. Larynx, Bd. 14, and *Killian,* Chir. Kongress, 1905.)

Plate LVIII.

Oesophagotomy

LVIII.

Oesophagotomy

INSTRUMENTS



Renner's Instruments for Dilating the Oesophagus.

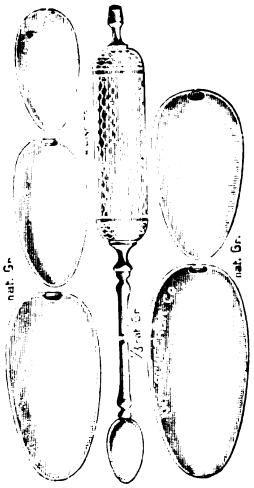

Collins' Oesophageal Dilator.



Collins' Laryngeal Forceps.

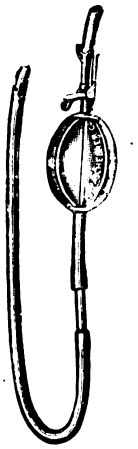

Boas' Stomach Tube.

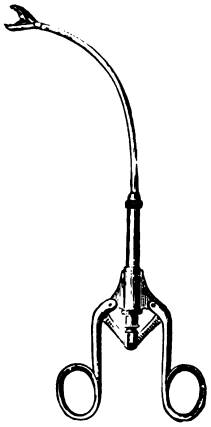

Movig's Laryngeal Forceps.

Glueckmann's Seizing Forceps.

Glueckmann's Tampon Carrier.

Glueckmann's Probe.

Kasper's Electroscope.

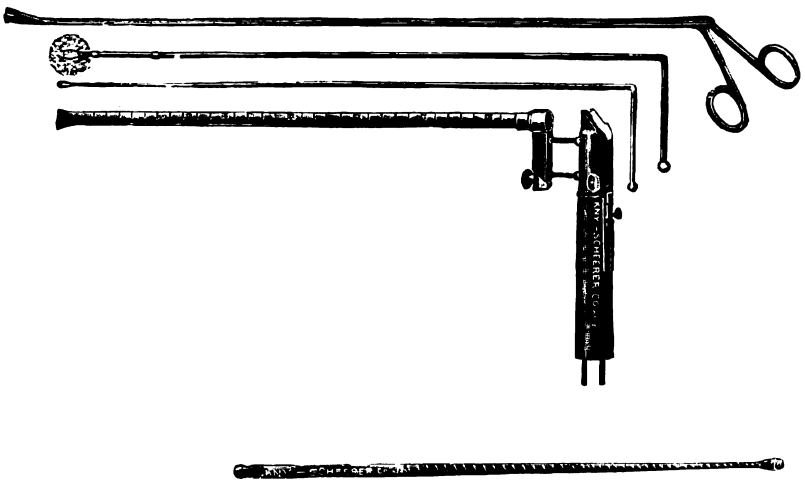

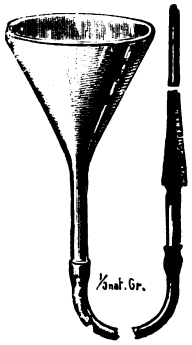

Kussmaul's Stomach Tube.

Rosenheim's Oesophageal Bougie.

Tiemann's Spiral Laryngeal Forceps.

Collins' Foreign Body Extractor.

Probang.

Probang.

Hinged Bucket for Carrying Coins.

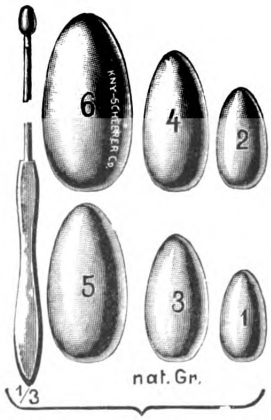

Trousseau's Oesophageal Dilator.



Ferguson's Bristle Probang.

Ewald's Stomach Tube.

Körte's Oesophageal Bougies.

Oesophagotomy.

Prior to a description of External Oesophagotomy it is necessary to consider certain other means which may possibly render a more serious operation unnecessary.

Surgical measures are generally required for the following conditions:

1. Injury from without.
2. Injury from within. (Foreign Bodies, Caustics, Burns.)
3. Tumours.

Injuries from without may call for Tracheotomy if respiratory difficulty arises.

Wounds of the Oesophagus are best treated by immediate tampons followed by Secondary Suture. The treatment of foreign bodies in the Oesophagus varies according to circumstances. There is but one fixed rule: "remove as early as possible."

When the foreign body has not passed further than the Pharynx or the upper part of the Oesophagus it can, oftentimes, be removed with the finger. Foreign bodies situated at a somewhat lower level can, at times, be removed with suitable forceps, with the coin-catcher, etc. When the objects are discernible with the X-Rays, any attempt at their removal should be carried out under the control of the X-Rays.

By external manipulations attempts have been made to alter the shape of pieces of meat and subsequently push them onwards into the Stomach.

The safest method, at the present day, of removing foreign bodies is with the aid of Oesophagoscopy, which was first introduced in 1868 by *Kussmaul.* Since this date the method has been so developed by *Mikulicz, Hacker, Rosenheim, Kirstein, Killian, v. Eicken,* and others, that it has now become most reliable.

Oesophagoscopy should always be preceded by the passage of bougies after any dental-plates or false-teeth have been removed. The tubes employed are rigid and thickwalled, varying in length and calibre, but dilated at the end. During their introduction an English Bougie, somewhat longer than the tube, is employed as a Stylet. With the aid of a Laryngoscope and a special forceps (cf. Instruments) the Soft Palate, Larynx and commencement of the Oesophagus have been cocainised (20 per cent to 52 per cent aqueous or, better, alcoholic solution).

In children a general Anæsthetic should also be administered. The patient should be fasting.

The Tubes, lubricated with Glycerine, should be introduced when the patient is in the sitting-posture, but if the examination is prolonged the patient is better in the recumbent position with the head retracted.

Kasper's Electroscope or *Kirstein's* Head-Lamp can be employed to illuminate the tube.

Killian's Aspirator is a most useful apparatus for the very rapid removal from the Oesophagus through a thin tube, of any fluid. Particles of food can be removed by means of a sponge on a holder (cf. Instruments). By the above method foreign bodies in the Oesophagus can be localised and extracted with suitable forceps or hooks. Dental Plates may be broken up into small fragments by means of a Cautery and removed piece-meal (*Killian*).

Oesophagoscopy is of service as a diagnostic and therapeutic measure, Scars due to Corrosives, Dilatation of Strictures, etc.

In doubtful cases of Carcinoma the diagnosis has been confirmed by inspection, followed, when desirable, by an exploratory excision (a small portion of the Tumour removed for Microscopic examination). Upon removal of the tube the patient's head is forthwith bent forward to allow of the escape of saliva. Pain arising in the course of Oesophagoscopy soon disappears after sucking pieces of ice or the application of a wet pack.

Oesophagoscopy is contra-indicated in Acute Inflammatory Diseases of the Respiratory Passages and Aortic Aneurysm.

Whenever the foreign body is large or has sharp edges extraction is difficult, by means of the Oesophagoscope, in addition to the danger of the injury which may result to the Oesophagus.

Under these conditions an External operation should be performed. Whenever bodies have remained in the Oesophagus for a considerable time or have set up an inflammatory condition, these must always be removed by an External Oesophagotomy.

As a general rule strictures resulting from Caustics or Hot Substances should be dealt with by gradual dilatation, by means of suitable bougies (Olivary-pointed Bougies, Drainage Tubes, etc).

Caustics and Electrolysis have also been tried in dilatation of these stenoses.

Internal Oesophagotomy, *i.e.,* the incision of a stricture from within, has been abandoned.

When dilatation fails External Oesophagotomy, *i.e.,* division of the Stricture from without, is performed. Incision above and below the Stricture with subsequent dilatation may be undertaken. If other methods fail in the case of foreign bodies or strictures at the lower end of the Oesophagus, Gastrostomy will demand

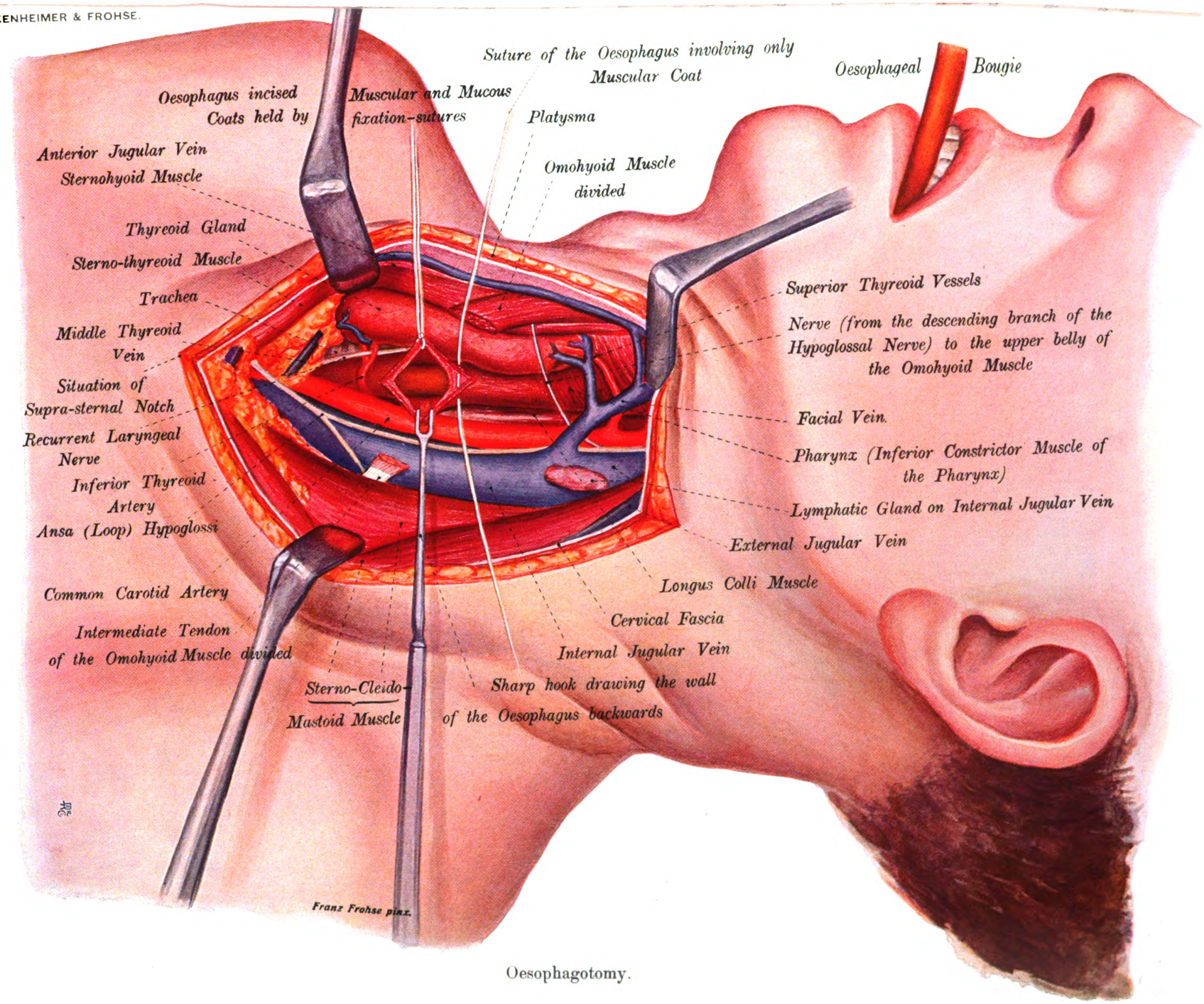

Oesophagotomy.

consideration. After Gastrostomy has been performed and the wound has healed an attempt is made to extract the foreign body through the fistula or to dilate the stricture from below (retrograde dilatation).

Von Hacker's method of passing tubes may be employed.

Dorsal Oesophagotomy has been practised when the above methods have not resulted in the successful removal of a foreign body; however, this operation is to be regarded as "a last resource."

In the case of Oesophageal Tumours only two operations need be considered. (a) External Oesophagotomy when the opening is made below the tumour and (b) Gastrostomy when the tumour is situated very low down.

Resection of the Cervical Portion of the Oesophagus has met with success, the lower end of the Oesophagus being subsequently drawn into the wound; if the portion resected is small, the two ends can be united; otherwise the missing portion of the Oesophageal wall has to be substituted by invaginated skin flaps.

Resection of the lower end of the Oesophagus as practised by *von Mikulicz* and *Sauerbruch* in the Pneumatic chamber is hardly applicable to man. Apart from the difficulty of the operation, owing to adhesions of the tumour to the Vagus, Vessels., etc., and the difficulty of securing the sutures, the tumour is generally not amenable to operation by the time diagnosis is certain.

External Oesophagotomy

Anæsthesia: Chloroform, Ether, *Roth-Drager's* Apparatus. Harvey-Hilliard's Ethyl Chloride and Chloroform method.

Position: Neck pushed forwards by a cylindrical cushion, Head raised and slightly inclined towards the right. An Oesophageal Bougie is introduced.

Indications: *Vide supra.*

As the Oesophagus lies to the left and posterior to the Trachea, it is sought for on the left.

Incision: The incision is in the same line as for ligature of the Common Carotid Artery, but is longer, *i.e.,* it extends from the level of the Hyoid Bone downwards to the Suprasternal Notch along the inner border of the Sterno-Cleido-Mastoid Muscle.

After division of the Skin and Platysma the inner border of the Sterno-Mastoid Muscle is freed, by an incision through its fascial covering, and drawn outwards. The Vascular (Carotid) Sheath can now be recognised by the Descendens Hypoglossi which runs along its anterior aspect. Upon opening this sheath the large Internal Jugular Vein is exposed and drawn aside, if possible, without ligature of the Common Facial Vein, in order to expose the Common Carotid Artery.

As much as possible of the Common Cartoid Artery from its bifurcation to the lower angle of the skin incision is freed and drawn outwards. At the upper angle of the wound the Superior Thyreoid Artery is ligatured as it runs forwards along the inner side and in front of the Common Carotid Artery.

The Omohyoid Muscle, which runs across the field of operation, is divided transversely.

If the Sternohyoid Muscle be drawn inwards and the Thyreoid Gland held forwards and inwards, the Oesophagus is brought into view. If now the Prevertebral Layer of the Cervical Fascia is divided the Oesophagus becomes quite distinct, as it is situated somewhat behind and a little to the left of the Trachea, a little below the level of the Cricoid Cartilage. The pale-red colour and the longitudinal striation (muscle fibres) are its characteristic features. If any difficulty should arise in finding the Oesophagus, the operator must search between the Trachea and Spinal Column. Long incisions and a free exposure of the Oesophagus are advisable; for this purpose we also ligature the Inferior Thyreoid Artery at the lower angle of the wound, carefully avoiding the Recurrent Laryngeal Nerve which crosses the Artery to lie on its inner side.

At the lower angle of the wound the Trachea completely covers the Oesophagus, which can only be seen when the Trachea is lifted forwards.

The previous introduction of a bougie renders it much easier to see and to feel the Oesophagus. A very important point to observe is the drawing outwards of the Large Vessels and the drawing inwards of the Laryngeal Structures. A mistake which the operator is liable to make is to proceed at too great a distance from the middle line, so that he comes down upon the Longus Colli Muscle as it covers the anterior aspect of the Cervical Vertebræ.

The Oesophagus is opened on its postero-lateral aspect by a small slit, which can be subsequently enlarged when the Recurrent Laryngeal Nerve has been drawn well downwards and inwards. The figure exhibits our method of keeping open the wound in the Oesophagus by means of an anterior traction-suture and a posterior traction-hook.

Foreign bodies, in the majority of cases, can thus be easily removed. After this has been accomplished, the Oesophagus may be sewn up with silk sutures, which are passed through the muscle coats, but not through the mucous membrane. The superficial soft parts are only stitched together at the upper and lower angles of the incision, a drainage being placed in the remainder of the wound.

In other instances, the mucous membrane of the Oesophagus is stitched to the skin so as to form a Fistula—a gauze being placed circumferentially—(Oesophagostomy).

Diverticula may be removed at their Oesophageal orifice, the Oesophageal wound being primarily sutured.

Despite sutures, fluid exudes from the Oesophagus into the wound, rendering frequent renewal of the dressing necessary (every 3 hours).

In order to avoid injury to the sutures the patient may be fed through a thin, soft, Oesophageal tube, or may be allowed to take food at once.

Cellulitis of the Neck is by no means an exceptional complication, and if this be not treated immediately by keeping the wound widely open, Consecutive Anterior or Posterior Mediastinitis may result; accordingly, free drainage becomes indispensable.

Elevation of the lower end of the bed assists in the flow of pus towards the head.

To obtain a sufficient exposure of the Oesophagus in children and in patients with short necks, it is necessary to divide the Sterno-Mastoid Muscle in its lower third.

It is very important that the Oesophagus be found quickly in order to diminish the risk of infection from excessive injury to the neighbouring tissues.

Plate LIX.

Excision of the Breast according to von Bergmann

Plate LIX.

Excision of the Breast according to von Bergmann

Removal of the Breast and Cleaning away of the Axillary Lymphatic Glands.

General Anæsthesia: Chloroform: Ether: *Roth-Dräger's* Apparatus. Harvey-Hilliard's Ethyl Chloroform and Chloroform apparatus.

Position: The Shoulder-region is raised by a cushion. The arm is abducted to a right-angle with the Thorax.

Indications: Tumours (Carcinoma, Sarcoma, Tuberculosis).

On the right side the operation is begun by an incision, similar to the one employed in ligature of the Axillary Artery. For this purpose the Axilla, which is bounded in front by the Pectoralis Major Muscle, behind by the Latissimus Dorsi Muscle, is divided into an anterior, a middle and a posterior third. The incision is commenced at the junction of the Anterior and Middle thirds, not too far from the Thorax.

The Breast is drawn to the left and upwards, while the incision is carried around the outer and lower margins to a point just short of the Xiphoid Process. The incision is made direct, through the Skin and Subcutaneous Tissue, on to the Pectoral Fascia. At this stage only the large vessels are secured, any bleeding from small vessels is checked by compression. The Breast is, as far as possible, returned to its normal position, while a second incision joining the former is swept around the upper and inner margins of the gland. Owing to retraction of the Skin, our figure does not depict the second incision as commencing in the Axilla at the position of the blunt-hook.

In this way there is presented a straight incision in the Axilla (as in ligature of the Axillary Artery) extending to an oval incision which encircles the breast. The short axis of this oval incision depends upon the extent of the disease. In connection with this incision also only the larger vessels are clamped.

In making these incisions the cutting edge of the knife should be directed obliquely, outwards and downwards for the lower incision and inwards for the upper incision. In this way any subcutaneous breast-tissue and fat will be removed with the chief mass.

On the left side, the outer incision is commenced near the Xiphoid Process

and carried around the lower and outer parts of the breast to terminate as the incision for ligaturing the Axillary Artery.

After the oval incision encircling the breast, separation of the entire Breast and Pectoral Fascia, which nearly always shews evidence of Carcinomatous infiltration, is commenced; in fact, it is better to remove at the same sweep the superficial part of the Pectoralis Major Muscle. Along the lower incision the Pectoralis Major, Pectoralis Minor, Latissimus Dorsi and Serratus Magnus Muscles are exposed. After removal of the fat, the Teres Major and Subcapularis Muscles also come into view. This gives considerable advantage to the further proceedings.

The Breast, thus freed, is allowed to hang downwards. By this means the Axillary fat and Lymphatic Glands are rendered more accessible to the operator.

Considerable care should be exercised in the removal of the various irregular prolongations of the breast and not only of the bulk of the organ.

A large portion (Axillary Process) of Mammary Tissue extends over the free-Axillary border of the Pectoralis Major Muscle.

Upwards towards the Clavicle a second prolongation (Clavicular Process) may have to be dealt with, even extending upwards over the second rib. A third, lower and outer, prolongation has to be considered in its extension as far as the 7th rib (the point of meeting of the Serratus Magnus and External Oblique Muscles).

In every case the Regional Glands, *i.e.,* the Axillary Glands, are sought for, even when they are not palpable; to ensure the removal of these glands a dissection comparable to an anatomical exposition is necessary. (Cf. Plate.) The Axillary Vein should be found. There may be two large veins. Diseased glands are usually found below the Vein; these glands are best removed by the finger covered with gauze. Several small tributaries of the Axillary Vein are ligatured. Whenever possible the large Subscapular Vein should be left intact. The Lymphatic Glands embedded in the Axillary Fat are removed with it. There is no need to preserve the Intercosto-humeral Nerve, which is a purely sensory nerve. But all the nerves which run in a longitudinal direction, *e.g.* the Long Thoracic Nerve of *Bell* and the Subscapular Nerves, should be preserved in order to avoid paralysis of the muscles supplied by them (Serratus Magnus, Subscapularis, Teres Major and Latissimus Dorsi). The nerves above the Axillary Vein (the Brachial Plexus) are in no way interfered with if there are no diseased glands around them.

Besides those Axillary Glands which are usually visible and palpable, attention must be directed to the Infra-Clavicular Glands. If these are affected it is advisable to remove the whole Clavicular Portion of the Pectoralis Major and to cut off the Pectoralis Minor near the Coracoid Process or to remove it in its entirety, even if only to ensure no injury to the vein.

The Subclavian vein should not be interfered with, because unpleasant sequelæ may result from its ligature. In some cases, however, the vein is completely surrounded by diseased glands and may be torn during their removal. If this results, lateral ligature or suture is attempted and, if impossible, the vein is ligatured.

Whenever the Supraclavicular Glands are involved the success of the operation is doubtful, so that we refuse to operate under these conditions. In many of these cases, a chain of diseased glands can be felt extending upwards along the large vessels and downwards to the Apex of the Pleura. In order to remove these, an incision in the Supraclavicular region would be necessary. For removal of these glands division of the Clavicle has been recommended, whereby more room is obtained and injury is avoided to the Thoracic Duct (Left Side) to the Lymphatic Duct (Right Side), or to the Pleura (both sides). The Thoracic Duct is frequently injured during this operation; Suture is unnecessary as packing with gauze impregnated with Subacetate of Aluminium invariably ensures its closure.

The large vessels, previously clamped, are now ligatured, *e.g.* Long Thoracle, Subscapular and some perforating arteries. Any other vessels are now secured so that the wound is made quite dry, as the greater the Hæmostasis the more certain is Primary union.

The skin is undermined and the wound-edges are approximated by long, wide and strong silk sutures. In only a few instances can complete sewing up be accomplished. A drainage-tube extending from the Axillary Vein to the middle of the incision is a safeguard. When the wound-cavity is very capacious, a counter-incision becomes necessary along the outer border of the Scapula, where the fibres of the Latissimus Dorsi may need separation.

Nextly, finer and smaller sutures are interpolated in order to ensure better approximation of the edges of the wound after the removal of any protruding adipose tissue.

In some cases the edges cannot be approximated opposite the middle of the wound. After the interval of a week, Skin-Grafting (*Thiersch's* method) will prove a remedy.

The dressing should be firmly applied in order to prevent any otherwise inevitable accumulation of blood between the Skin and underlying Muscles.

The whole arm from the tip of the fingers to the Thorax is firmly bandaged and kept fixed to the Thorax for a week.

If everything is satisfactory, the large sutures and drainage-tube may be removed in about a week after the operation.

The arm is then placed in a sling and on the average the patient leaves Hospital on the 12th day.

Permanent cure, *i.e.*, absence of recurrence 3 years after the operation has been obtained in 29.79 per cent in *von Bergmann's* Clinique. (*Guleke's* Statistics.)

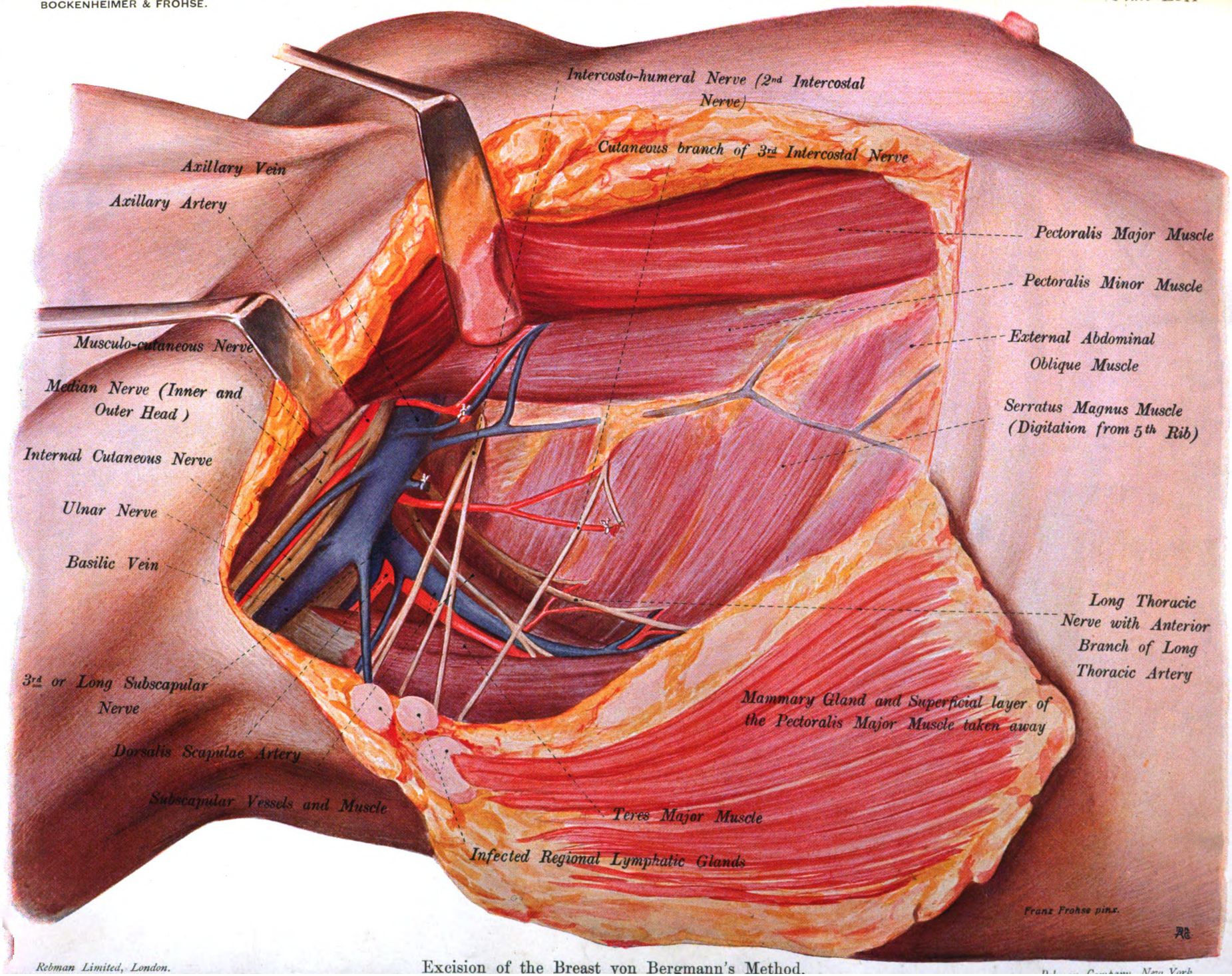

Rebman Limited, London.

Excision of the Breast von Bergmann's Method.

Rebman Company, New York.

Plate LX.

Operations on the Trigeminal Nerve—Fifth Cranial Nerve—(with the Collaboration of Professor Lexer)

Plate LX.

Operations on the Trigeminal Nerve

INSTRUMENTS

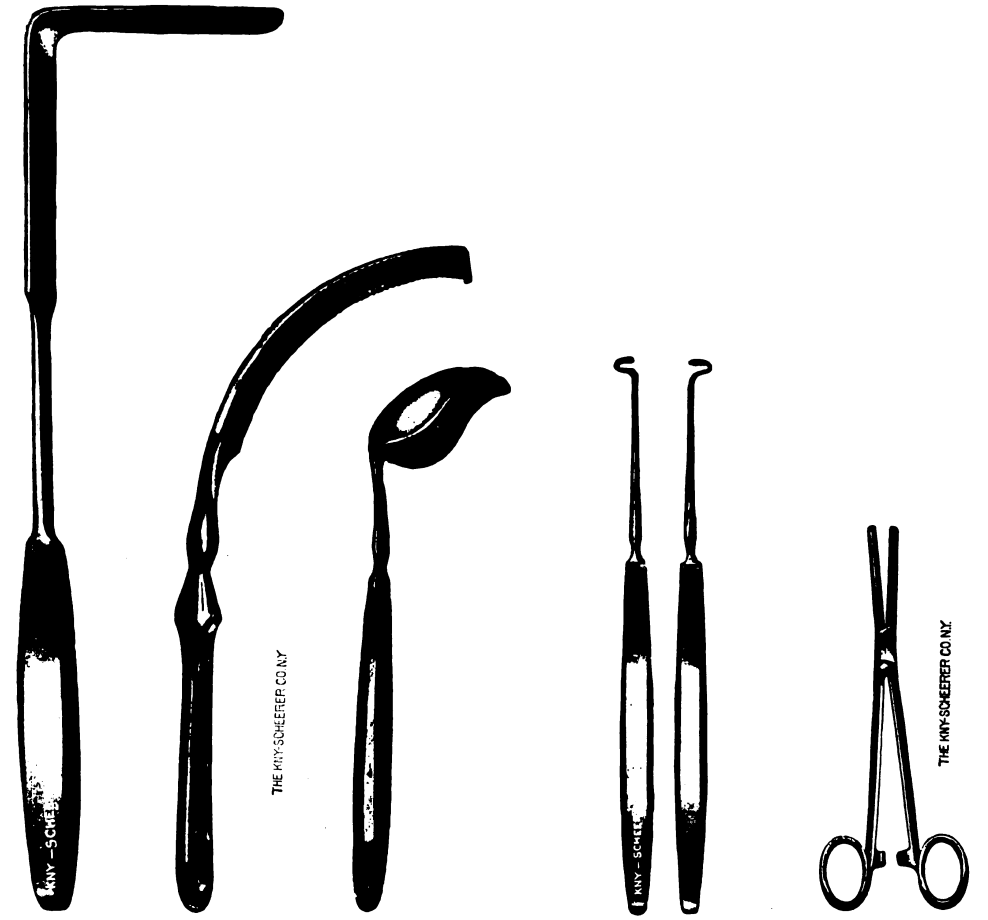

Lexer's Retractor. Lexer's Cranial Spatula Wagner's Eye Retractors. Aneurism Needles. Thiersch's. Nerve Extracting Forceps.

Operations on the Trigeminal Nerve

These operations are necessary in cases of severe Neuralgia when the treatment of Local Causes (Cicatrices, Inflammation, Foreign Bodies, Tumours) or General Causes (Malaria, Diabetes) has failed. Success is, however, only possible in the absence of Central disease (Hysteria, Basal-Tumours, Aneurism of the Internal Carotid, Sclerosis).

These operations deal with diseases of the branches of the 3 divisions of the 5th Nerve, with the 3 divisions themselves or even with the Gasserian Ganglion. Complete bilateral disease of the 5th Nerve contra-indicates operation owing to the functional disturbances which would be produced; furthermore, in such cases a central lesion is frequently present.

The operations which may be performed are: Neurotomy (*Schlichting*, 1748), Neurectomy (*Abernethy*, 1793), Extraction of the Nerve (*Thiersch*, 1889), Removal of the Gasserian Ganglion (*Hartley* and *F. Krause*, 1892).

Simple division of the Nerve was abandoned and resection adopted so as to avoid recurrence which might be brought about by reunion of the divided ends. As resection of a stretched nerve proved an inefficient guarantee against recurrence, *Thiersch* introduced torsion of the exposed nerves—Neurexairesis. The main nerve distributed to the affected area is exposed to a small extent as near as possible to the Ganglion; the distal end is seized in a forceps, which is slowly twisted so as to tear all the peripheral connections, while the nerve is rolled up on the forceps. Specimens varying from 4 to 8 inches in length, with the minute terminal filaments, are easily obtained if sufficient patience is exercised.

The operations are classified into 3 groups.

1. Operations on the Terminal Ramifications.
2. Operations near the Base of the Skull.
3. Operations on the Gasserian Ganglion.

As to 1. The following "Terminal or Peripheral Operations are of practical importance: a. Torsion or Resection of the Ophthalmic or 1st division. A small curved incision is made along the upper margin of the orbit, directly over the Supra-Orbital Notch, through Skin and Muscles, down to the periosteum. Care is taken not to injure the nerve twigs. The Supra-Orbital Nerve now comes into view with the Supra-Trochlear Nerve on its mesial aspect. These branches are seized and twisted or the main trunk may be traced backwards into the orbit (*Krause's* Method) where the main division may be seized before the Supra-Trochlear nerve is given off.

If a foramen replace the Supra-Orbital Notch, the osseous bridge should be broken. (Owing to their Anatomical position the Lacrymal and Nasal Nerves defy operation.)

b. Torsion of the Infra-Orbital Nerve.

An incision is made from the lower border of the Orbit, at the junction of the inner and middle thirds, obliquely downwards and outwards parallel with the branches of the Facial vessels (*Kocher*) or a longitudinal incision at the level of the Infra-Orbital Foramen may be made.

While the Inferior Palpebral and External Nasal Nerves are preserved the Infra-Orbital Nerve is exposed by division of the periosteum directly over it and the origin of the Levator Labii Superioris (Quadrate) Muscle.

After separating the Infra-Orbital Artery from the Nerve, the latter is seized and twisted. In order to secure the Anterior and Middle Dental Nerves at the same time *Krause* recommends a small incision at the margin of the orbit, elevation of the Periosteum from the floor of the orbit and removal of a small wedge of bone above the Foramen, so that the thin floor of the orbit, inasmuch as it roofs in the Supra-Orbital Nerve, may be cut away with forceps. The accompanying artery may be separated and the nerve, when lifted out of the groove, seized as far back as possible. Even the Posterior Superior Dental Nerves may be in this way reached.

c. Torsion of the Lingual Nerve is carried out from within the Buccal Cavity. The tongue is drawn towards the unaffected side. The mucous membrane of the floor of the mouth, opposite the last molar tooth, at its point of reflection on to the tongue, is divided from before backwards. The nerve is thus exposed.

d. Torsion of the Inferior Dental Nerve.

Carefully preserving from injury the branches of the Facial Nerve, an incision curving round the angle of the Jaw is carried down to the bone. The posterior portion of the Masseter is freed from the bone; the periosteum on the outer aspect of the lower half of the ascending ramus of the jaw is separated.

After *Linhart's* Method an elongated window or a corresponding furrow (cf. Fig. 1) is chiselled out of the bone. In this way the main trunk is exposed in its canal before its dental branches have been given off. With a little care it is possible

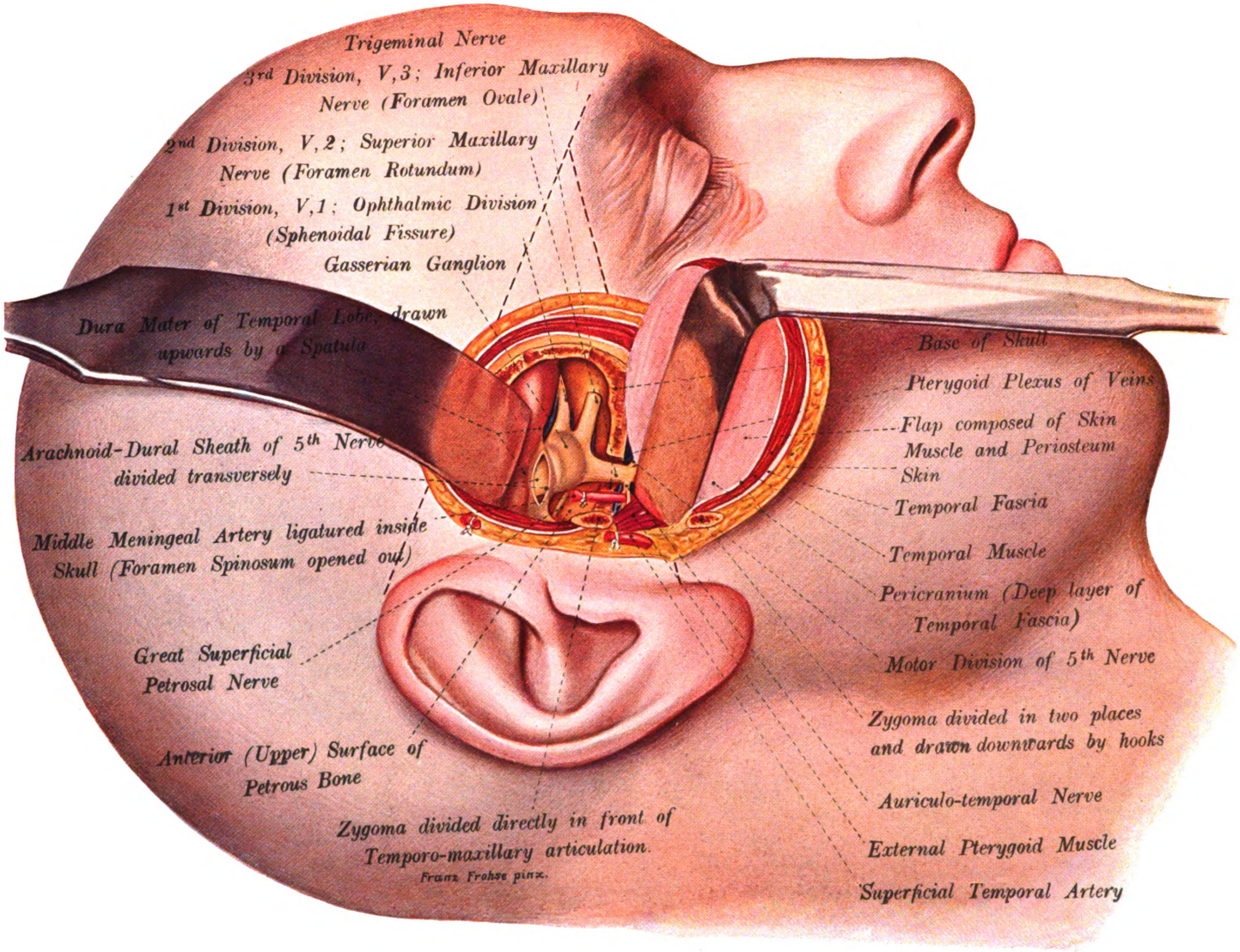

Operations on the 5th Nerve.
Removal of Gasserian Ganglion (Lexer's Method).

to push the nerve out of its canal and secure it in the Nerve-forceps without damage to the Inferior Dental Artery.

On the inner surface of the Jaw, the same nerve is found (*Sonnenberg*) through the same incision before it enters the Inferior Dental Foramen near the Spine of Spix or the Lingula. Owing to the depth of the wound it is safer to feel for the Spine and to draw the Nerve out directly above before it is seized with the forceps guided by the finger (Fig. 2).

The Long Buccal Nerve and the Auriculo-Temporal Nerve are not reached by this route.

2. Operations near the Base of the skull are carried out in order to deal with the second or third division or both near their foramina of exit.

These operations are indicated either when the peripheral procedures have been followed by recurrence or when inaccessible branches (*e.g.* Palatine Nerves, Auriculo-temporal nerve, etc.) are diseased.

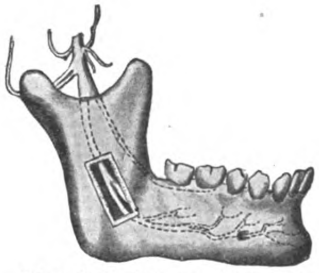

Fig. 1.—Right half of Lower Jaw outerside with Velpeau-Linhart's window.

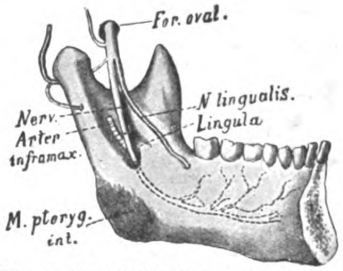

Fig. 2.—Left half of Lower Jaw, inner side.

The greater number of these operations are based upon *Krönlein's* Method (1884): the simplest modification is *Lexer's* operation (1905), which deals with either or both divisions.

A horizontal incision is made through the skin and temporal fascia along the upper border of the Zygoma, extending from the Zygomatic angle to a point in front of the superficial temporal artery (Fig. 3). By drawing downwards the posterior angle of the wound a *Gigli's* saw may be passed around the root of the Zygoma by means of *Deschamp's* Needle. The bone is sawn through close to the articular tubercle, and the zygomatic process of the Malar bone is divided obliquely downwards and forwards (cf. Fig. 3). After exposure of the Temporal Muscle its posterior portion is separated from the bone and drawn well forwards (after partial division if necessary). The Infra-Temporal Crest now becomes accessible; at this line the periosteum is divided; a hook 4/5 inch broad is placed into the gap and employed to separate the Periosteum and External Pterygoid Muscle from the bone

The soft structures are now drawn downwards so that the Infra-temporal Fossa with the Foramen Ovale and the emerging 3rd division becomes exposed (cf. Fig. 4). By means of a hook the nerve is secured. With comparative ease all injury to the Middle Meningeal Artery is avoided as it lies deep to the articular surface of the lower jaw.

By proceeding forwards at the base of the skull the Pterygoid Fossa is reached, here the 2nd division has been drawn into the wound by a retraction-suture (cf. Fig. 4). It is advisable to employ the electric forehead-lamp.

After torsion of the nerve the Zygoma is replaced: careful suturing of the soft parts will retain it in position.

3. Removal of the Gasserian Ganglion is necessary when persistent and severe Neuralgia occurs, after operative methods have been resorted to in all 3 divisions.

Hartley and *Krause's* operation, which consists in making a large temporal flap and lifting up the Brain in order to reach the Gasserian Ganglion, has been modified by many surgeons, by *Lexer* (1898), because of the danger to which the brain is exposed when lifted up.

Waldeyer states that his procedure is the most correct, inasmuch as the danger of injury to the brain through the spatula is diminished owing to the very small trephine opening.

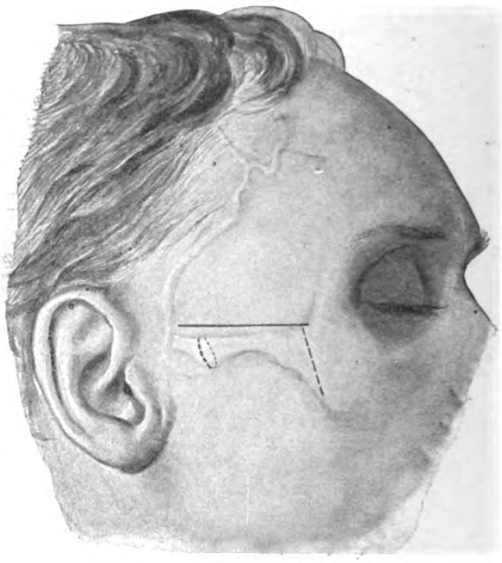

Fig. 3.

The incision begins at a point one finger's breadth in front of the ear on a line connecting the point of attachment of the lobule of the ear with the upper margin of the orbit; the other extremity of this curved incision ends at the upper zygomatic angle on the same line.

In this manner nearly all branches from the Facial Nerve to the Upper Eyelid are avoided (cf. Fig. 5).

In the Plate the incision has been carried a little beyond this line.

A line drawn from the upper border of the Pinna to the Supraorbital margin should be tangential to the curve of the incision.

The Temporal Artery is now ligatured, and the incision carried down to the bone. (For operations upon the scalp it is advisable to ligature the Temporal Artery in order to lessen Hæmorrhage.)

The Zygoma is divided in two places: directly in front of its tubercle by means of a wire saw and subcutaneously at its junction with the Malar Bone by means of a chisel, which is directed forwards and downwards.

The Flap composed of Skin, Muscle and Pericranium is separated from the Bone as far as the Infra-Temporal Crest; here again the Periosteum and External Pterygoid Muscle are separated as far as it is necessary to expose the Infra-Temporal Fossa. The Flap is drawn downwards and slightly forwards by means of a large hook. Hæmorrhage from the PterygoidPlexus is stopped by the introduction of a tampon.

The skull is now opened, directly above the Crest, by means of a chisel. The opening is, at first, made very small; piece-meal the exposed bone is cut away. The small size of the opening renders it unnecessary to preserve the bone in the flap.

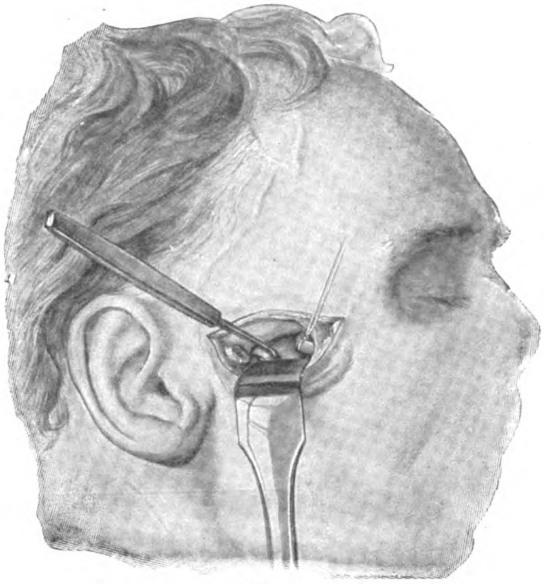

Fig. 4.

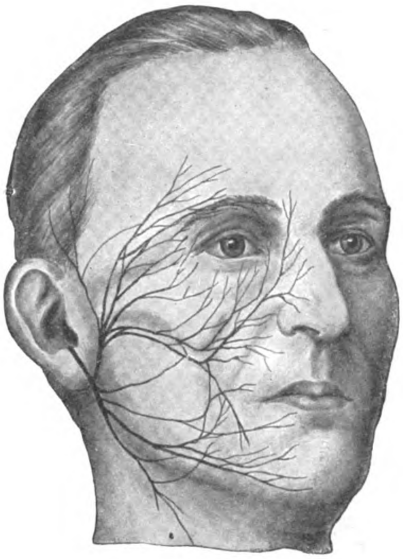

Fig. 5.

By digital manipulation, to which the Middle Meningeal Artery serves as a guide, the Dura Mater is separated as far as the Foramen Spinosum. In this way the Base of the Skull within the area of the Infra-Temporal Fossa is exposed on both its outer and inner surfaces. The bone is removed as far as the Foramen Spinosum. (In the figure the margin of the Foramen Spinosum has been broken in order to shew more distinctly the Middle Meningeal Artery; this is not necessarily done in the operation.) The Artery can now be doubly-ligatured within the Skull. Bone is removed as far as the Foramen Ovale. (This method may be employed for Ligature of the Middle Meningeal Artery.)

The 3rd division serves as a guide to the Ganglion. Hæmorrhage from the

neighbouring vein may be very severe. By raising the Head this Hæmorrhage is considerably diminished; at the same time the Cerebro-Spinal Fluid runs into the Cord as Gravity brings the Brain back to its normal position (*v. Bergmann*).

The Dura Mater on the outer aspect of the Ganglion is freed by blunt dissection until the 2nd division is brought into view. This is completely exposed with ease. To avoid bleeding from the Cavernous Sinus and to avoid injury to the Oculo-Motor Nerve, the lower border only of the 1st Division is exposed.

The inner surface of the Ganglion is now freed from the bone so that by traction upon the 3rd Division the Ganglion can be drawn downwards while the Spatula keeps the Dura Mater upwards. The Brain cannot be injured in these proceedings because the Spatula is pressed up against the upper border of the opening at the base of the skull.

Only the posterior portion of the Ganglion is freed so as to expose the upper part of the Ganglion. The upper border of the root of the 5th Nerve is seized with a blunt hook, and drawn downwards before division. (By this manipulation the nerve is partially or completely torn.) The Ganglion is next turned forwards and the three divisions are cut across or the 2nd and 3rd divisions having been cut the 1st is twisted with a *Thiersch's* forceps. If each division is cut, it is advisable to cut the 3rd division last.

A loose strand of Iodoform-gauze is placed in the Cave of *Meckel* and the wound nearly completely sewn up, a drainage tube is placed in the posterior part of the wound for a few days so as to prevent an accumulation of blood in the Infra-Temporal Fossa.

The eye is guarded by a watch-glass retained in position by adhesive plaster, so as to form a protection for the Cornea and Conjunctiva which have now been deprived of sensibility.

Index

The figures refer to plates.

A.

Abdominal Wall, suture of, 47.
Anus, Artificial, 41.
Appendicitis, 30—32.
Appendicectomy, 30—32.
Arteries, suture of, 57.
Autoscopy, 57.
Axilla, 59.

B.

Basedow, 56.
Bassini, 6—10.
Bladder, 38.
Bottini, 35.
Brain, operations on the, 5.
Breast, removal of, 59.
Bronchoscopy, 57.

C.

Cellulitis of Hand, 25.
Cellulitis of Neck, 37.
Cholecystectomy, 54.
Cholecystenterostomy, 55.
Cholecystostomy, 53, 54.
Cholecystotomy, 53.
Choledochoduodenostomy, 55.
Choledochotomy, 55.
Chylous Fistula, 59.
Colon, operations on, 41, 42, 50.
Colostomy, 41, 42.
Cystoscopy, 26.
Cystostomy, Suprapubic, 38.

E.

Empyæma, 24.
End-to-side Anastomosis, 50.
Enteroanastomosis, 47.
Enterorrhapy, 46—47.
Enterotomy, 46, 55.
External Urethrotomy, 34.

F.

Fæcal Fistula, 42.
Femoral Hernia, 28, 29.

G.

Gall-Bladder, operations on, 53—55.
Gasserian Ganglion, 60.
Gastroenterostomy, Anterior, 43, 46.
Gastroenterostomy, Posterior, 49.
Gastrostomy, 17, 18.
Gastrotomy, 17, 18.
Goitre, 56, 57.
Graves's Disease, 56.

H.

Hand, Cellulitis of, 25.
Heart, operations on, 48.
Hemicraniotomy, 4, 5.
Hernia, 6—10, 29.

I.

Implantation, lateral, 50.
Inguinal Hernia, 6—10.
Intestine, resection of, 46—47.

J.

Jejunostomy, 45.

K.

Kidneys, abscess of, 27.
Kidneys, decapsulation of, 27.
Kidneys, operations on, 26.
Kryoscopy, 26.

L.

Laminectomy, 39, 40.
Laparotomy, 17.
Laparotomy, Transthoracic, 33.
Laryngofissure, 20.
Laryngoplasty, 22.
Laryngoscopy, 57.
Larynx, extirpation of: total and partial, 19—23.
Ligature of Aorta, 26.
Ligature of Axillary Artery, 59.
Ligature of Carotid Arteries, 56, 57, 58.
Ligature of Facial Artery, 13.
Ligature of Common Iliac Artery, 26.
Ligature of External Iliac Artery, 26.
Ligature of Internal Iliac Artery, 26.
Ligature of Lingual Artery, 11, 13.
Ligature of Middle Meningeal Artery, 4, 60.
Ligature of Thyreoid Arteries, 56.
Liver, operations on, 53—55.
Lower Jaw, division of, 13, 14.
Lower Jaw, division of, 16.
Lower Jaw, chiselled open, 60.
Lumber Anæsthesia, 39.
Lungs, operations on the, 24, 33, 57.

M.

Murphy's Button, 46, 47.

N.

Neck, Cellulitis of, 37.
Nephrectomy, 27.
Nephropexy, 27.

Nephrotomy, 27.
Nerve, Vth Cranial, 60.
Neurectomy, 60.
Neurexairesis 60.
Neurotomy, 60.

O.

Oesphagoscopy, 58.
Oesphagostomy 58.
Oesphagotomy, 58.

P.

Pericardiotomy, 48.
Pleurotomy, 24.
Pneumopexy, 33.
Pneumotomy, 33, 57.
Prostatectomy, 34—36.
Pubis, division of, 38.
Pyloroplasty, 45.

R.

Radical Cure of Femoral Hernia, 29.
Radical Cure of Inguinal Hernia, 6—10, 28.
Rectopexy, 52.
Rectoscopy, 51.
Rectum, operations on the, 51, 52.
Rectum, excision of, 51, 52.
Ribs, resection of, 24.
Retropharyngeal tumour, 4.

S.

Seminal Vesicle, 52.
Spinal Cord, 39, 40.
Stomach, operations on, 17, 18, 43—45, 49.
Suprarenal Bodies, 27.

T.

Thyreoidectomy, 56, 57.
Tongue, excision of, 12, 16.
Tracheoscopy, 57.
Tracheotomy, High, 4—10.
Tracheotomy, Low, 19, 20, 37.
Transpleural Laparotomy, 33.
Trephining, 4, 5, 49.
Trigeminal Nerve, 60.

U.

Ureter, exposed in Pelvis from behind, 52.
Ureter exposed retroperitoneally, 27.
Urethrotomy, External, 34.

Z

Zygoma, division of, 60.

U.C. BERKELEY LIBRARIES
C039318529